

**DATE**

7/722

PRESENTING CLINICAL SIGNS

Came in for vaccine update for boarding; O had no concerns;
PE- Thin appearance (4/9); bladder large on palpation but otherwise P appeared WNL
Current Medications: None.

PATIENT

Gracey Bellinger

Lab Results: TP- 5.9 (6.3-8.8), Globulins 2.7 (3.0-5.9).
Date of Previous IntraPet Ultrasound: No previous.
Sedation: Not required to complete full diagnostic ultrasound.
Stat Report: Not requested.
Imaging Performed By: Stephanie Pearce RDCS, RVT.

SPECIES

Feline

ULTRASONOGRAPHIC EXAMINATION OF THE ABDOMEN**BREED**

Domestic Shorthair

Urinary System

Urinary bladder is adequately distended with anechoic contents. No masses, inflammatory changes, echogenic sediment or cystoliths are observed. The urinary bladder, trigone and visible pelvic urethra are normal in thickness with a smooth mucosal surface.

SEX

Spayed Female

Left kidney is normal is size (3.6 cm), shape and echogenicity. It has smooth peripheral margination. There is a normal 1:3 cortex to medulla ratio with appropriate corticomedullary distinction. There is no evidence of pyelectasia, mineral or infarcts observed.

AGE

5/30/11

Right kidney is normal is size (3.87 cm), shape and echogenicity. It has smooth peripheral margination. There is a normal 1:3 cortex to medulla ratio with appropriate corticomedullary distinction. There is no evidence of pyelectasia, mineral or infarcts observed.

WEIGHT

8.1 lbs

Adrenal Glands

Left adrenal gland is normal in size (0.28 cm), shape and overall architecture, echogenicity and echotexture. Visible surrounding vasculature appears normal.

INTERPRETED BYBeth Johnson, DVM
DACVIM

Right adrenal gland is normal in size (0.35), shape and overall architecture, echogenicity and echotexture. Visible surrounding vasculature appears normal.

HOSPITAL NAMEEssex Middle Riveer
VC**Spleen**

Spleen is subjectively normal in size with a normal smooth capsular contour. Parenchyma is appropriately finely textured and homogenous with normal echogenicity relative to surrounding tissue (hyperechoic to liver). No focal nodules or masses are observed. Splenic vasculature appears normal.

REFERRING VET

Dr. Hicks

Liver

Liver is subjectively normal in size with normal smooth curvilinear peripheral contour. Parenchyma is appropriately hypoechoic to the spleen in echogenicity and appropriately mildly coarse and homogenous in echotexture. No focal lesions are observed. Visible vasculature and biliary tree appear normal without distension or congestion.

INVOICE

31509

Gallbladder is non-distended in size. The wall is smooth without visible thickening. Luminal contents are primarily anechoic. There is no evidence of cystic or common bile duct dilation.

Gastrointestinal

The visible small intestine demonstrates areas of thick muscularis layer relative to mucosa (disruption of the normal 1:3 muscularis:mucosa ratio). Small intestinal submucosa is slightly irregular, thick and hyperechoic,

without evident loss of layering appreciated. The lumen of the small intestine is empty with no evidence of obstruction or foreign material.

The visible colon is normal in wall thickness (< 0.2 cm) and layering. Contents are consistent with normal formed feces and gas.

Pancreas

The observed pancreas appears appropriately isoechoic to surrounding omental fat. The capsule is mildly irregular in shape. Parenchyma is mildly heterogenous and coarse. There is no visible pancreatic duct dilation. There is no evidence of active peripancreatic inflammation.

Free Abdomen

Reactive mesentery lymph nodes are prominent in size with swollen capsular contour. Normal elongated shape (length to width ratio) is maintained. There is no loss of parenchymal detail. Enhanced, hyperechoic fat was noted around the mesenteric lymph nodes in the area of the ileocecolic junction were noted. There was no appreciable free fluid.

ULTRASONOGRAPHIC FINDINGS

PRIMARY FINDINGS:

- **Inflammatory bowel disease (IBD) pattern** – Thick muscularis has been reported with infiltrative bowel disease including both benign inflammatory disease as well as infiltrative neoplasia such as lymphoma. No aggressive lymphadenopathy, loss of layering, etc. is noted to make lymphoma more probable, but lymphoma cannot be definitively ruled out without tissue sampling.
- **Pancreatic age-related remodeling** – Mild irregularities are consistent with benign age-related change. Low-grade smoldering chronic pancreatitis cannot be ruled out and should be suspected in the face of appropriate clinical signs.
- **Reactive lymph nodes** – infiltrative neoplastic disease cannot be ruled out but is considered less likely

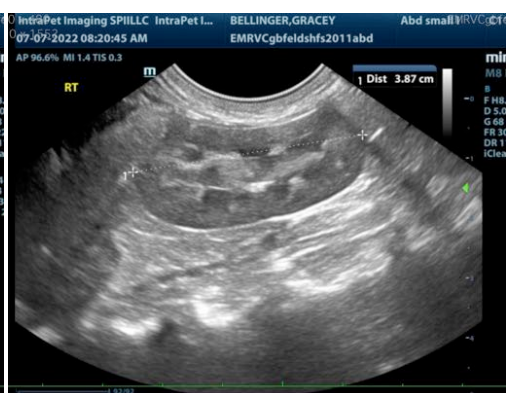
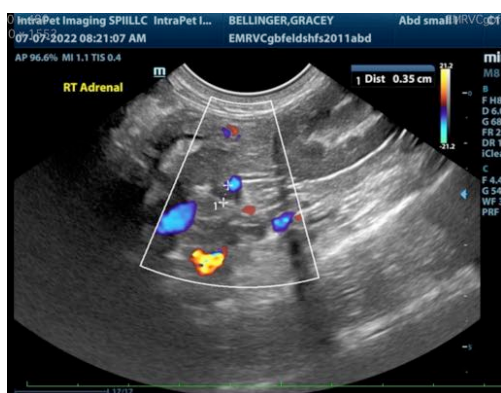
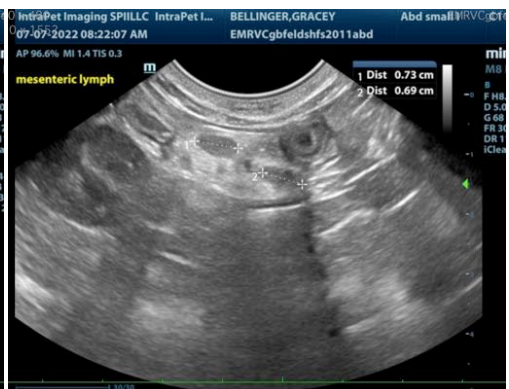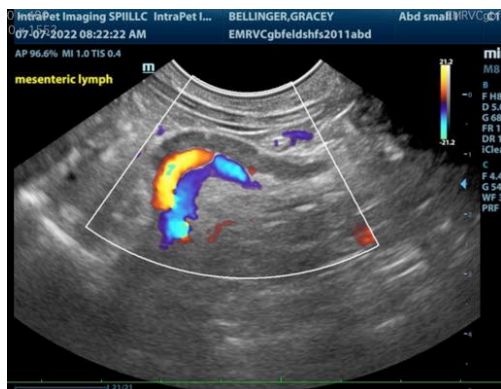
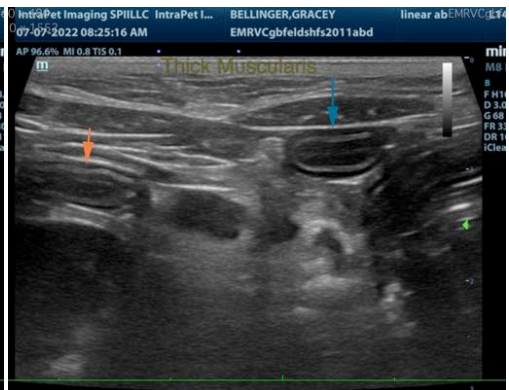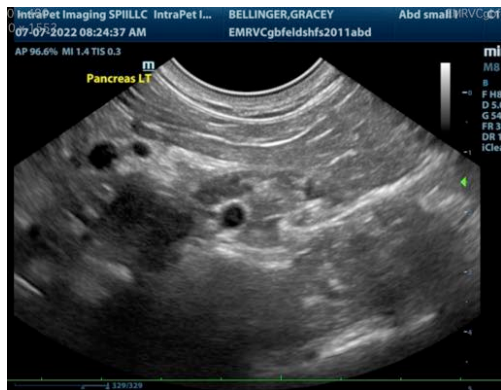INTERPRETATION OF THE FINDINGS & FURTHER RECOMMENDATIONS

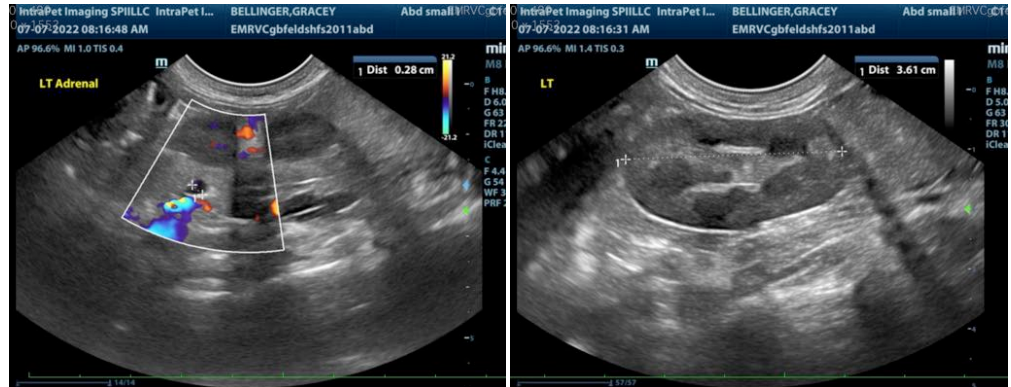
Recommendation for this patient includes:

A gastrointestinal malabsorption panel (including cobalamin, folate, TLI and PLI) to Texas A&M GI Laboratory is recommended for further evaluation of GI and pancreatic function.

Ideally, biopsies of the GI tract, being sure to include ileum if possible, are recommended to definitively diagnose and therefore manage the infiltrative bowel disease.

If biopsies cannot be obtained then empirical therapies could: include diet change, empirical deworming with a 5 day course of Panacur, cobalamin supplementation (unless cobalamin level is evaluated and supplementation is not warranted) and prednisolone (if not contraindicated based on patient contraindications, co-morbidities, etc.). Other supportive therapeutic considerations could include fiber supplementation, especially with large bowel diarrhea and/or a probiotic.





The information and recommendations provided are based on the images presented by the referring veterinarian. No evaluation can be communicated regarding pathology that was not visible in the image/video clips provided.

Thank you for this referral. If the clinical or image interpretation does not parallel your findings or if I can be of any further assistance please contact me.

Beth Johnson, DVM DACVIM

Beth.Johnson@SonoPath.com