



**PATIENT**

Camie Probst

**SPECIES**

Feline

**BREED**

DMH

**SEX**

Spayed Female

**AGE**

12 Years

**WEIGHT**

13 Pounds

**INTERPRETED BY**

Beth Johnson, DVM  
DACVIM

**IMAGING PERFORMED BY**

Dr. Jack Reese

**HOSPITAL NAME**

Willow Run VC

**REFERRING VET**

Dr. Jack Reese

**INVOICE**

39302

**DATE**

7/7/22

**PRESENTING CLINICAL SIGNS**

Several week history of decreased activity level, lethargy. Owner reports that Camie will lie on her side more frequently at home in strange places, which is a new behavior for her. Appetite has been good, known history of degenerative joint disease in hind end. Currently taking amlodipine for hypertension, currently being monitored by cardiologist for mild mitral regurgitation and left ventricular hypertrophy. Also taking gabapentin 50mg BID and Dasuquin Advanced at home.

Abnormal PE/Chem/CBC/UA Results: Mild hypokalemia 3.0 (3.5 - 5.8 mmol/L) - 2 measurements, 2 weeks apart Rest of blood values WNL Hypertension - on amlodipine Subclinical heart disease

**ULTRASONOGRAPHIC EXAMINATION OF THE ABDOMEN**

**Urinary System**

The urinary bladder is moderately distended with anechoic contents. No masses, inflammatory changes, echogenic sediment or cystoliths are observed. The urinary bladder, trigone and visible pelvic urethra are normal in thickness with a smooth mucosal surface.

The right kidney is normal in size (3.3 cm) and shape with smooth peripheral margination. A normal 1:3 cortex to medulla ratio is maintained. The medulla and cortices are uniform in texture with some mild increased echogenicity and mild loss of corticomedullary distinction. There is no evidence of pyelectasia, mineral or infarcts observed.

The left kidney is normal in size (3.3 cm) and shape with smooth peripheral margination. A normal 1:3 cortex to medulla ratio is maintained. The medulla and cortices are uniform in texture with some mild increased echogenicity and mild loss of corticomedullary distinction. There is no evidence of pyelectasia, mineral or infarcts observed.

**Adrenal Glands**

The structure believed to be the right adrenal gland is mildly plump, measuring 0.55 cm thick. However, an enlarged lymph node in the area of the right adrenal gland cannot be definitively ruled out.

The left adrenal gland is normal in size (0.46 cm thick), shape and contour. Corticomedullary structure is unremarkable. Visible surrounding vasculature appears normal.

**Spleen**

The spleen is subjectively normal in size with a normal smooth capsular contour. Parenchyma is appropriately finely textured and homogenous with normal echogenicity relative to surrounding tissue (hyperechoic to liver). No focal nodules or masses are observed. Splenic vasculature appears normal.

**Liver**

The liver is subjectively normal in size with normal smooth curvilinear peripheral contour. Parenchyma is appropriately hypoechoic to the spleen in echogenicity and appropriately mildly coarse and homogenous in echotexture. No focal lesions are observed. Visible vasculature and biliary tree appear normal without distension or congestion.

The gallbladder is non-distended in size. The wall is smooth without visible thickening. Luminal contents are primarily anechoic. There is no evidence of cystic or common bile duct dilation.

**Gastrointestinal**

The stomach wall is normal in thickness (canine < 0.5 cm and feline < 0.4 cm) and layering. The lumen of the stomach is mildly distended with echogenic non-shadowing luminal contents and gas consistent



**PATIENT**

Camie Probst

with normal ingesta. There is no evidence of obstruction, foreign material or infiltrative disease. Pyloric outflow tract appears patent.

**SPECIES**

Feline

The visible small intestines are normal in wall thickness and layering (canine duodenum < 0.5 cm and feline duodenum < 0.4 cm; other < 0.3 cm). Small intestinal motility appears adequate (1-3 contractions per min). The lumen of the small intestine is empty with no evidence of obstruction, foreign material or infiltrative disease.

**BREED**

DMH

The visible colon is normal in wall thickness (< 0.2 cm) and layering. Contents are consistent with normal formed feces and gas.

**SEX**

Spayed Female

**Pancreas**

The pancreatic parenchyma is appropriately isoechoic to surrounding tissue. Visible capsule is smooth and normal in contour. There is no visible pancreatic duct dilation. There is no evidence of active peripancreatic inflammation.

**AGE**

12 Years

**Free Abdomen**

There is no evidence of free peritoneal effusion noted in these images.

There is no apparent lymphadenopathy noted in these images.

**WEIGHT**

13 Pounds

**ULTRASONOGRAPHIC FINDINGS**

- Suspect mild right adrenomegaly – primary rule out includes an aldosterone producing tumor, given the patient’s reported hypokalemia and hypertension. However, normal variant or less an enlarged lymph node in the area of the right adrenal gland, cannot be ruled out.
- Age related kidney change – This finding is expected/consistent with age-related mild degenerative disease and should be interpreted clinically in combination with laboratory changes.

**INTERPRETED BY**

Beth Johnson, DVM  
DACVIM

**INTERPRETATION OF THE FINDINGS & FURTHER RECOMMENDATIONS**

- Recommendations include running an aldosterone level to try to rule in/out Conn’s syndrome contributing to this patient’s weakness, hypokalemia and hypertension, etc. In the meantime, potassium supplementation is recommended.
- Pending the results of the aldosterone level, Spironolactone may be considered moving forward.

**IMAGING PERFORMED BY**

Dr. Jack Reese

**HOSPITAL NAME**

Willow Run VC

**REFERRING VET**

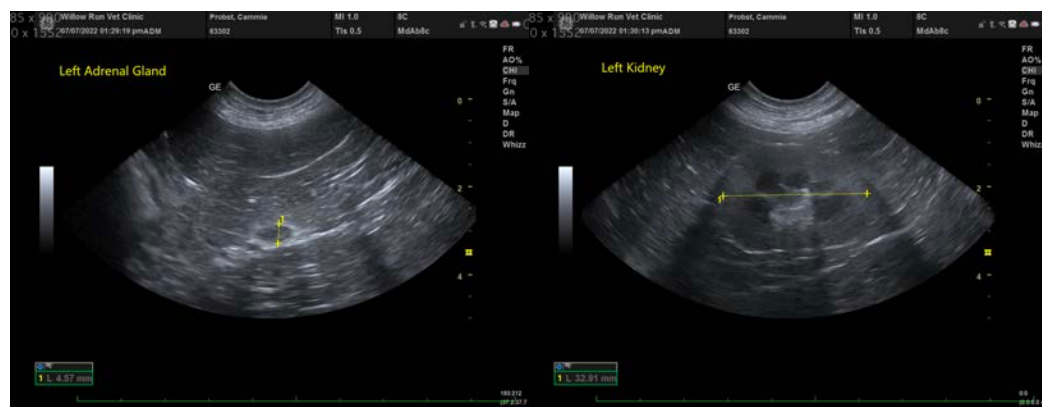
Dr. Jack Reese

**INVOICE**

39302

**DATE**

7/7/22





**PATIENT**

Camie Probst

**SPECIES**

Feline

**BREED**

DMH

**SEX**

Spayed Female

**AGE**

12 Years

**WEIGHT**

13 Pounds

**INTERPRETED BY**

Beth Johnson, DVM  
DACVIM

**IMAGING PERFORMED BY**

Dr. Jack Reese

**HOSPITAL NAME**

Willow Run VC

**REFERRING VET**

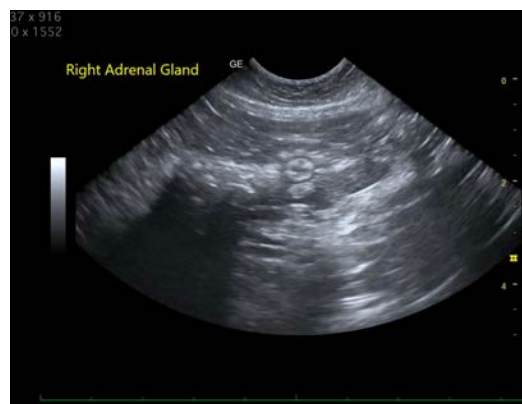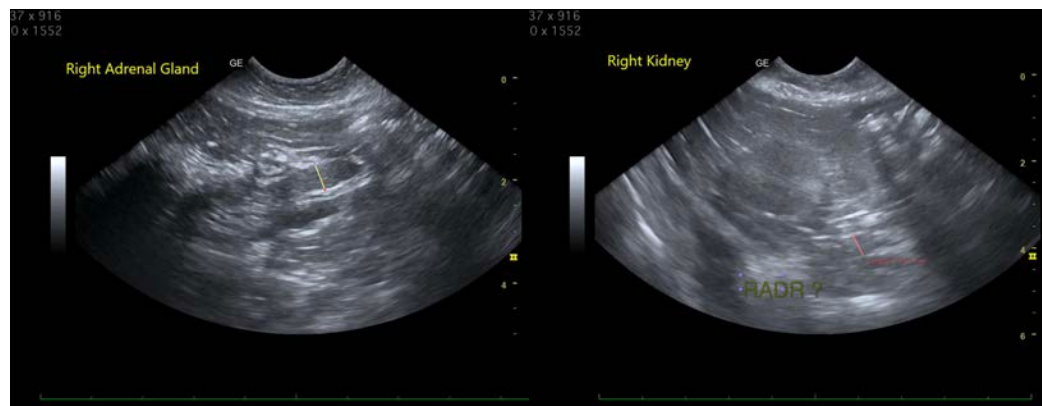
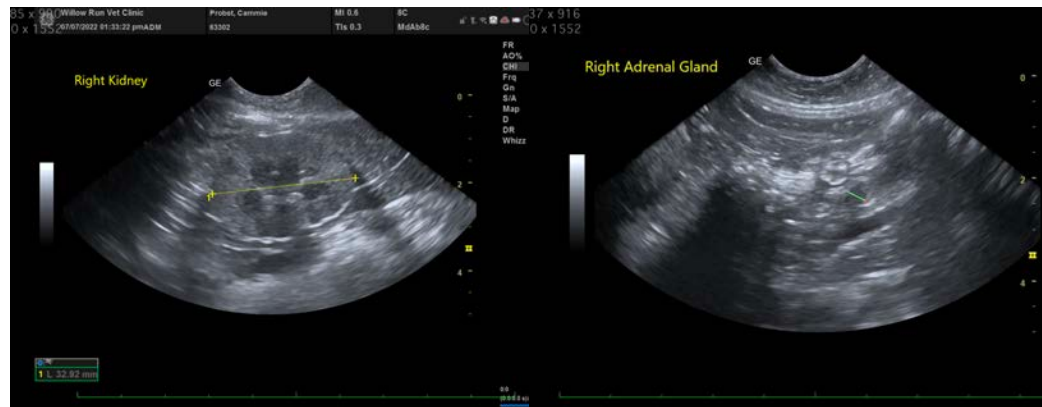Dr. Jack Reese

**INVOICE**

39302

**DATE**

7/7/22



The information and recommendations provided are based on the images presented by the referring veterinarian/sonographer. No evaluation can be communicated regarding pathology that was not visible in the image/video clips provided.

Thank you for this referral. If the clinical or image interpretation does not parallel your findings or if I can be of any further assistance please contact me.

**Beth Johnson, DVM, DACVIM**  
Beth.Johnson@sonopath.com