



**PATIENT**

Leo Brown

**SPECIES**

Feline

**BREED**

Abyssinian

**SEX**

Neutered Male

**AGE**

5 Years

**WEIGHT**

9.9 Pounds

**INTERPRETED BY**

Beth Johnson, DVM  
DACVIM

**IMAGING PERFORMED BY**

Amy Mayhew, LVT

**HOSPITAL NAME**

SVS Imaging MI

**REFERRING VET**

Kathryn Hicks

**INVOICE**

23178

**DATE**

7/6/23

**PRESENTING CLINICAL SIGNS**

History: Patient presents for ultrasound due to elevated ALT of unknown etiology. Patient presented as new patient to our clinic for wellness care 3/16/23. Patient was originally adopted (August 2021) when the family was living in Korea. He has an occasional cough that could be related to allergies/asthma, etc. It improved on Loratadine. Chest rads being obtained after AUS.

Abnormal PE/Chem/CBC/UA Results: Patient has grade 3 dental disease. Owners describe a cough at home, no abnormal lung sounds on PE. Patient had normal CBC/Chem/BNP levels and was FeLV/FIV/HW negative on 3/16/23. ALT at that time was 154 (upper normal was 158). UA on 3/25/23 showed SpG of 1.053 and mild proteinuria (plan to recheck UA with UPC in the future to monitor). Presented for dentistry on 5/1/23 and ALT was 195 (upper normal 130). Dentistry was postponed and patient was treated with a course of Amoxicillin and metronidazole. Recheck ALT on 5/17/23 was 162 (upper normal 130). Amoxicillin and Metronidazole courses were repeated and recheck ALT on 6/3/23 was 172 (upper normal 130). \*\*See attached in link.

**ULTRASONOGRAPHIC EXAMINATION OF THE ABDOMEN**

**Urinary System**

Urinary bladder is adequately distended with anechoic contents. No masses, inflammatory changes, echogenic sediment or cystoliths are observed. The urinary bladder, trigone and visible pelvic urethra are normal in thickness with a smooth mucosal surface.

Kidneys are normal in size (left kidney 3.73 cm, right kidney 3.8 cm) with increased cortical echogenicity. Normal smooth peripheral margination and shape are maintained. There is a normal 1:3 cortex to medulla ratio with appropriate corticomedullary distinction. There is no evidence of pyelectasia, mineral or infarcts observed. Infiltrative disease (infectious, neoplastic, etc.) or nephritis cannot be ruled out but is considered less likely.

**Adrenal Glands**

Left adrenal gland is normal in size (0.37 cm), shape and overall architecture, echogenicity and echotexture. Visible surrounding vasculature appears normal.

Right adrenal gland is normal in size (0.44 cm), shape and overall architecture, echogenicity and echotexture. Visible surrounding vasculature appears normal.

**Spleen**

Spleen is mildly enlarged (1.1 cm thick) in size with a mildly swollen but smooth capsule. Parenchyma is normal and homogenous in echogenicity and echotexture. No focal nodules or masses are observed. Splenic vasculature appears normal. A small chronic infarct is suspected, characterized by a subtle capsular indentation at a hyperechoic wedge-shaped density near the head of the spleen.

**Liver**

Liver is subjectively normal in size with normal smooth curvilinear peripheral contour. Parenchyma is appropriately hypoechoic to the spleen in echogenicity and appropriately mildly coarse and homogenous in echotexture. No focal lesions are observed. Visible vasculature and biliary tree appear normal without distension or congestion.

Gallbladder is non-distended in size. The wall is smooth without visible thickening. Luminal contents are primarily anechoic. There is no evidence of cystic or common bile duct dilation.



**PATIENT**

***Gastrointestinal***

Leo Brown

The visible stomach wall is normal in thickness and layering. The lumen of the stomach is empty with no evidence of obstruction, foreign material or infiltrative disease. Pyloric outflow tract appears patent.

**SPECIES**

Feline

The visible small intestine demonstrates areas of mildly thick muscularis layer relative to mucosa (disruption of the normal 1:3 muscularis:mucosa ratio). Small intestinal submucosa is slightly irregular, thick and hyperechoic, without evident loss of layering appreciated. The lumen of the small intestine is empty with no evidence of obstruction or foreign material.

**BREED**

Abyssinian

The visible colon is normal in wall thickness and layering. Contents are consistent with normal formed feces and gas.

**SEX**

***Pancreas***

Neutered Male

The observed pancreas appears appropriately isoechoic to surrounding omental fat. Visible capsule is smooth and normal in contour. Visible pancreatic parenchyma is homogenous and unremarkable. There is no visible pancreatic duct dilation. There is no evidence of active peripancreatic inflammation.

**AGE**

5 Years

***Free Abdomen***

There is no evidence of peritoneal effusion. The mesenteric lymph nodes are prominent in size with swollen capsular contour. Normal elongated shape (length to width ratio) is maintained. There is no loss of parenchymal detail.

**WEIGHT**

9.9 Pounds

**ULTRASONOGRAPHIC FINDINGS**

**INTERPRETED BY**

Beth Johnson, DVM  
DACVIM

- Mild inflammatory bowel disease (IBD) pattern – Thick muscularis has been reported with infiltrative bowel disease including both benign inflammatory disease as well as infiltrative neoplasia such as lymphoma. No aggressive lymphadenopathy, loss of layering, etc. is noted to make lymphoma more probable, but lymphoma cannot be definitively ruled out without tissue sampling.

**IMAGING PERFORMED BY**

Amy Mayhew, LVT

- Reactive mesenteric lymph nodes – infiltrative neoplastic disease cannot be ruled out but is considered less likely.

**HOSPITAL NAME**

SVS Imaging MI

- Mild hypersplenism with an incidental small chronic infarct suspected near the head of the spleen- can be associated with congestion caused by sedation (if sedated) but can also be associated with diffuse infiltrative disease. Both benign conditions such as extramedullary hematopoiesis, lymphoid hyperplasia, amyloidosis (leave amyloidosis out if canine) as well as infiltrative neoplastic diseases such as round cell neoplasia should be considered.

**REFERRING VET**

Kathryn Hicks

- Urinary bladder debris

**INTERPRETATION OF THE FINDINGS & FURTHER RECOMMENDATIONS**

**INVOICE**

23178

Further recommendations, given this patients reported ALT history, and young age, include bile acid testing, if not already evaluated. Followed, potentially, by liver sampling beginning with a fine needle aspirate, if patients coagulation status is appropriate. Additionally, comprehensive infectious disease testing could be considered, as well as, if not recently evaluated, urinalysis and, if indicated based on urinalysis results, urine culture is recommended. If protein is present in an otherwise quiet sediment, protein quantification with a urine protein to creatinine ration is recommended.

**DATE**

7/6/23



## PATIENT

Leo Brown

Pending results, some of the ALT elevation, could be secondary to chronic or intermittent ascending infections as a result of occult bowel disease. Given this patient's mild bowel changes, especially if there are any supporting gastrointestinal signs, a gastrointestinal malabsorption panel (including cobalamin, folate, TLI and PLI) to Texas A&M GI Laboratory is recommended for further evaluation of GI and pancreatic function.

## SPECIES

Feline

Ideally, biopsies of the GI tract, being sure to include ileum, if possible, are recommended to definitively diagnose and therefore manage the infiltrative bowel disease.

## BREED

Abyssinian

If biopsies cannot be obtained, empirical therapies could include a probiotic (if diarrhea is present, such as Visbiome or Provable), empirical deworming with a 5-day course of Panacur and, if tolerated, a transition in diet, based on trial-and-error response, beginning with a hydrolyzed protein diet. Some patients respond to one brand/version of a hydrolyzed protein diet better than another brand, so several trials may be required.

## SEX

Neutered Male

Additional considerations could include cobalamin supplementation (unless cobalamin level is evaluated and supplementation is not warranted) and prednisolone (if not contraindicated based on patient contraindications, co-morbidities, etc.).

## AGE

5 Years

## WEIGHT

9.9 Pounds

## INTERPRETED BY

Beth Johnson, DVM  
DACVIM

## IMAGING PERFORMED BY

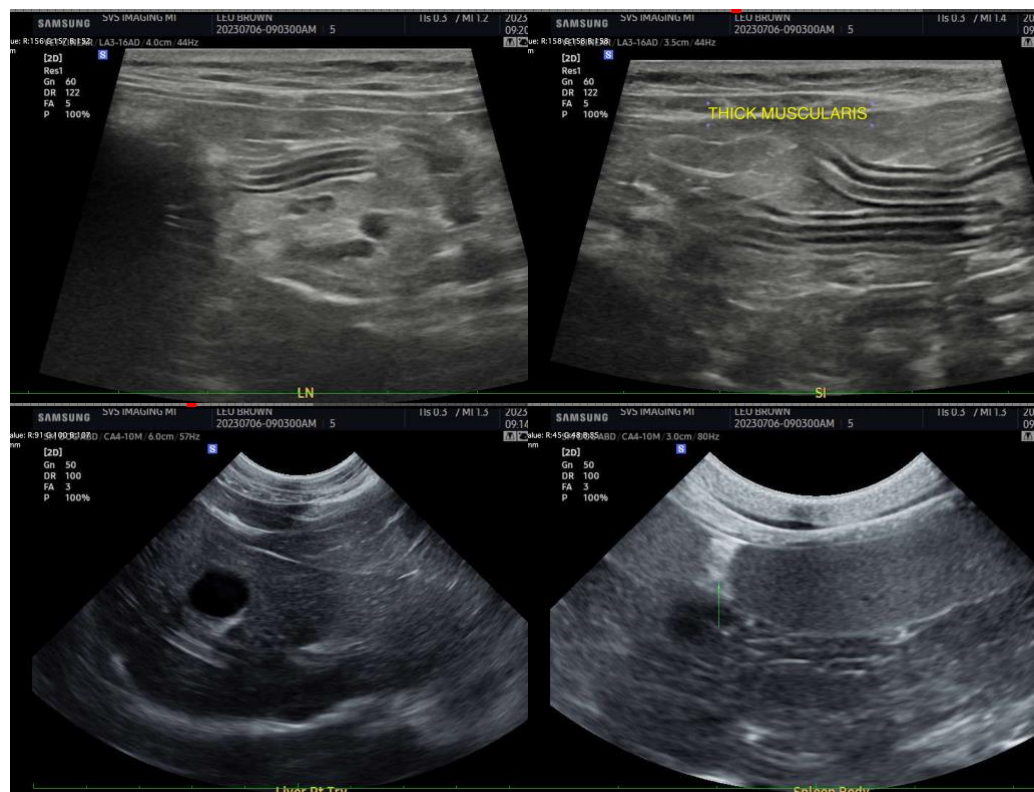
Amy Mayhew, LVT

## HOSPITAL NAME

SVS Imaging MI

## REFERRING VET

Kathryn Hicks

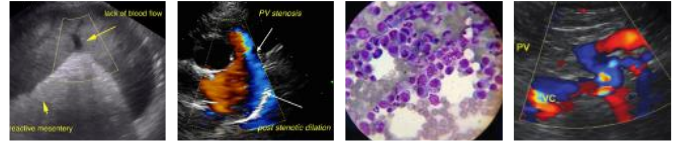


## INVOICE

23178

## DATE

7/6/23



**PATIENT**

Leo Brown

**SPECIES**

Feline

**BREED**

Abyssinian

**SEX**

Neutered Male

**AGE**

5 Years

**WEIGHT**

9.9 Pounds

**INTERPRETED BY**

Beth Johnson, DVM  
DACVIM

**IMAGING PERFORMED BY**

Amy Mayhew, LVT

**HOSPITAL NAME**

SVS Imaging MI

**REFERRING VET**

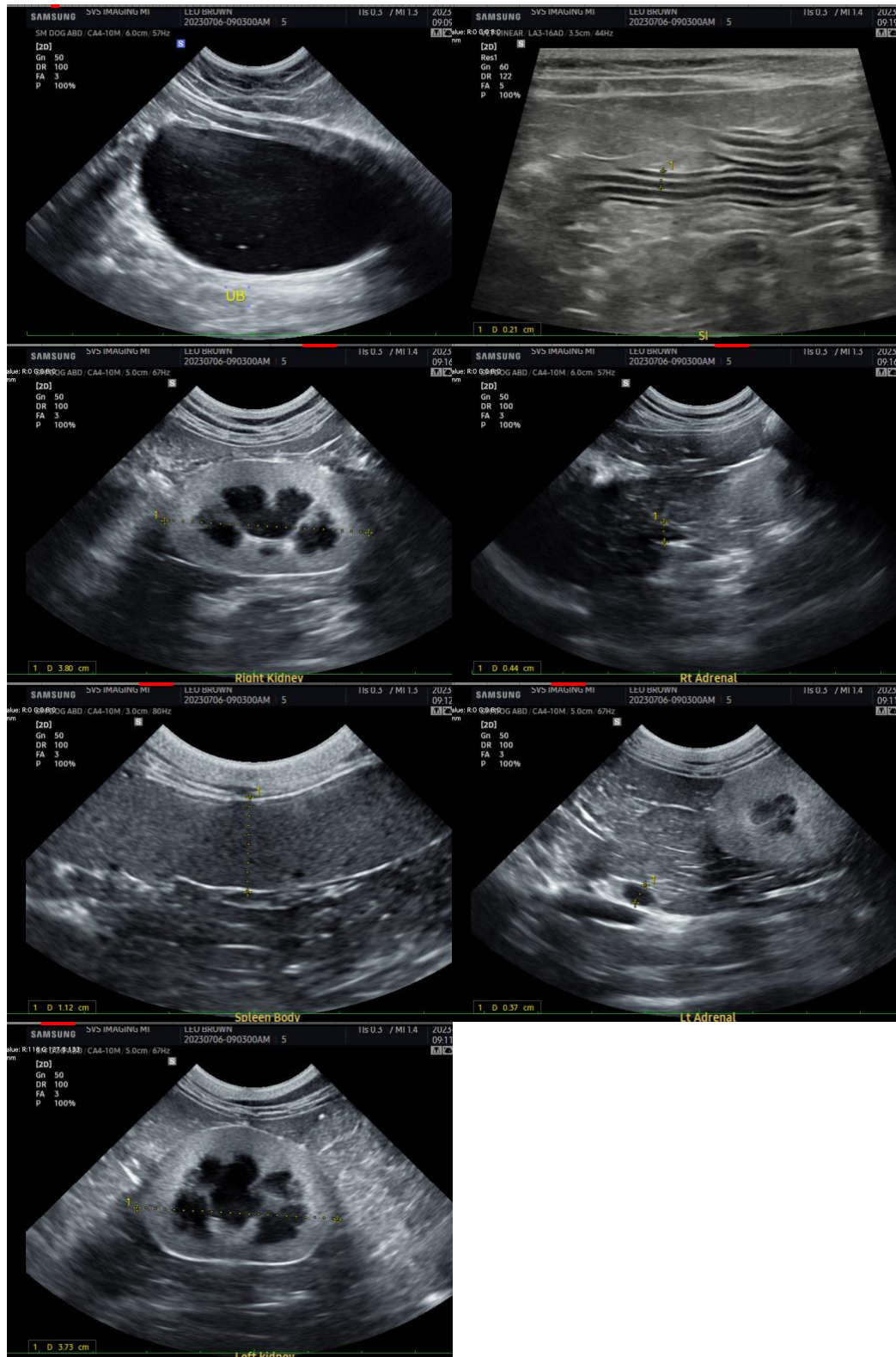
Kathryn Hicks

**INVOICE**

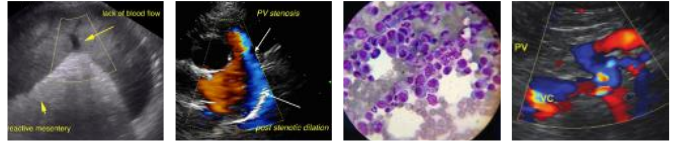
23178

**DATE**

7/6/23



The information and recommendations provided are based on the images presented by the referring veterinarian. No evaluation can be communicated regarding pathology that was not



**PATIENT**

**visible in the image/video clips provided.**

Leo Brown

Thank you for this referral. If the clinical or image interpretation does not parallel your findings or if I can be of any further assistance please contact me.

**SPECIES**

Feline

**Beth Johnson, DVM DACVIM**

info@sonopath.com

**BREED**

Abyssinian

**SEX**

Neutered Male

**AGE**

5 Years

**WEIGHT**

9.9 Pounds

**INTERPRETED BY**

Beth Johnson, DVM  
DACVIM

**IMAGING  
PERFORMED BY**

Amy Mayhew, LVT

**HOSPITAL NAME**

SVS Imaging MI

**REFERRING VET**

Kathryn Hicks

**INVOICE**

23178

**DATE**

7/6/23