**PATIENT PRESENTING CLINICAL SIGNS**

**Dinkum Beasley**  
**SPECIES** History: Hx elevated liver values that are not responding to Denamarin and ursodiol supplementation. Abnormal PE/Chem/CBC/UA Results: Bile acids & dex suppression test attached. Previous AUS done 3/23 indicated larger liver nodule as well as splenic nodules, would like to compare measurement/size to assess for progression.

Canine

**BREED ULTRASONOGRAPHIC EXAMINATION OF THE ABDOMEN**

Boxer Mix **Urinary System**

Urinary bladder is adequately distended with anechoic contents. No masses, inflammatory changes, echogenic sediment or cystoliths are observed. The urinary bladder, trigone and visible pelvic urethra are normal in thickness with a smooth mucosal surface.

**SEX**

Female Spayed

**AGE**

10.5 years

Left kidney is normal in size (5.98 cm), shape and echogenicity. It has smooth peripheral margination. There is a normal 1:3 cortex to medulla ratio with appropriate corticomedullary distinction. There is no evidence of pyelectasia, mineral or infarcts observed.

**WEIGHT**

46.60 lbs

Right kidney is normal in size (6.27 cm), shape and echogenicity. It has smooth peripheral margination. There is a normal 1:3 cortex to medulla ratio with appropriate corticomedullary distinction. There is no evidence of pyelectasia, mineral or infarcts observed.

**INTERPRETED BY****Adrenal Glands**

Beth Johnson, DVM  
DACVIM

Left adrenal gland is normal in size (0.61 cm at cranial pole / 0.62 cm at caudal pole), shape and overall architecture, echogenicity and echotexture. Visible surrounding vasculature appears normal.

Right adrenal gland is normal in size (0.80 cm at cranial pole / 0.70 cm at caudal pole), shape and overall architecture, echogenicity and echotexture. Visible surrounding vasculature appears normal.

**IMAGING PERFORMED BY**

Amy Mayhew LVT

**Spleen**

Spleen is subjectively normal in size with a normal smooth capsular contour. Parenchyma is appropriately finely textured and homogenous with normal echogenicity relative to surrounding tissue (hyperechoic to liver). Multifocal well-demarcated hyperechoic homogenous nodules are noted. Additionally, there are several (0.60 to 1.00 cm in diameter) hypo- to anechoic non-capsule-disrupting nodules throughout the parenchyma. Splenic vasculature appears normal.

**HOSPITAL NAME**

SVS Imaging Michigan

**Liver**

Liver is subjectively enlarged with mildly irregular margins. Parenchyma is heterogenous characterized by multiple poorly defined hypoechoic nodules within otherwise hyperechoic liver parenchyma. Visible vasculature and biliary tree appear normal without distension or congestion. In the deep left-liver, there is a slightly larger nodule (approximately 2.00 x 3.50 cm in size).

**REFERRING VET**

Dr. Marie Haddock

**INVOICE**

13590

Gallbladder is moderately distended with anechoic bile as well as suspended and gravity dependent echogenic debris. The wall is smooth without visible thickening. There is no evidence of cystic or CBD dilation. There is no evidence of effusion or inflammation.

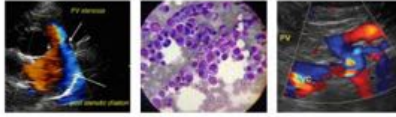
**DATE**

7.6.23

**Gastrointestinal**

The visible stomach wall is normal in thickness and layering. The lumen of the stomach is empty with no evidence of obstruction, foreign material or infiltrative disease. Pyloric outflow tract appears patent.

The visible small intestines are normal in wall thickness and layering. Small intestinal motility appears adequate (1-3 contractions per min). The lumen of the small intestine is empty with no evidence of obstruction, foreign material or infiltrative disease.



**PATIENT** The visible colon is normal in wall thickness and layering. Contents are consistent with normal formed feces and gas.

Dinkum Beasley

**SPECIES** *Pancreas*

The observed pancreas appears appropriately isoechoic to surrounding omental fat. Visible capsule is smooth and normal in contour. Visible pancreatic parenchyma is homogenous and unremarkable. There is no visible pancreatic duct dilation. There is no evidence of active peripancreatic inflammation.

Canine

**BREED** *Free Abdomen*

Boxer Mix There is no evidence of peritoneal effusion. There is no apparent lymphadenopathy.

**SEX** **ULTRASONOGRAPHIC FINDINGS**

Female Spayed

**Primary Findings**

**AGE**

10.5 years

**WEIGHT**

46.60 lbs

- Heterogenous Liver – These changes are most consistent with benign processes such as nodular hyperplasia, steroid (vacuolar) hepatopathy, extramedullary hematopoiesis or possibly chronic inflammatory disease and less commonly infiltrative round cell or metastatic neoplasia. The slightly larger nodule appears unchanged from the ultrasound report provided from the other clinic and also trends in appearance towards benign. Having said that, infiltrative neoplasia cannot be ruled out but is consider less likely.
- Hyperechoic splenic nodules with hypo- to anechoic splenic nodules – most consistent with benign myelolipomas. Other differentials such as fibrosis or calcification caused by old hematomas or infarcts, chronic inflammation, granulomatous disease or metastatic disease cannot be ruled out, but are considered less likely. The hypo- to anechoic splenic nodules likely represents a benign lesion such as a cyst, hematoma, nodular hyperplasia, extramedullary hematopoiesis, etc., however while considered less likely, infiltrative neoplasia can mimic benign lesions, and cannot be ruled out.

**INTERPRETED BY**

Beth Johnson, DVM  
DACVIM

**IMAGING PERFORMED BY**

Amy Mayhew LVT

**Secondary Findings**

- Mild gallbladder debris - Cholecystic debris is of unknown clinical significance. It can be seen with biliary stasis from fasting or illness. Cholecystic debris is not necessarily related to hepatobiliary disease. Echogenic bile is most commonly an incidental finding in dogs and should be interpreted in combination with clinical signs such as nausea, inappetence, cranial abdominal discomfort and/or laboratory changes such as increased ALP and/or increased Tbili.

**HOSPITAL NAME**

SVS Imaging Michigan

**REFERRING VET**

Dr. Marie Haddock

**INTERPRETATION OF THE FINDINGS & FURTHER RECOMMENDATIONS**

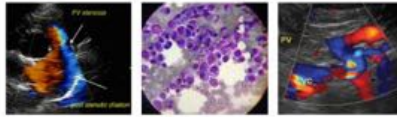
- Given this patient's normal or unremarkable work-up so far, combined with reported lack of improvement with hepatic nutraceuticals, etc., the next diagnostic recommendations to consider can include a fine-needle aspirate of the liver and/or spleen (if coagulation status of the patient is appropriate).

**INVOICE**

13590

**DATE**

7.6.23



**PATIENT**

Dinkum Beasley

**SPECIES**

Canine

**BREED**

Boxer Mix

**SEX**

Female Spayed

**AGE**

10.5 years

**WEIGHT**

46.60 lbs

**INTERPRETED BY**

Beth Johnson, DVM  
DACVIM

**IMAGING  
PERFORMED BY**

Amy Mayhew LVT

**HOSPITAL NAME**

SVS Imaging Michigan

**REFERRING VET**

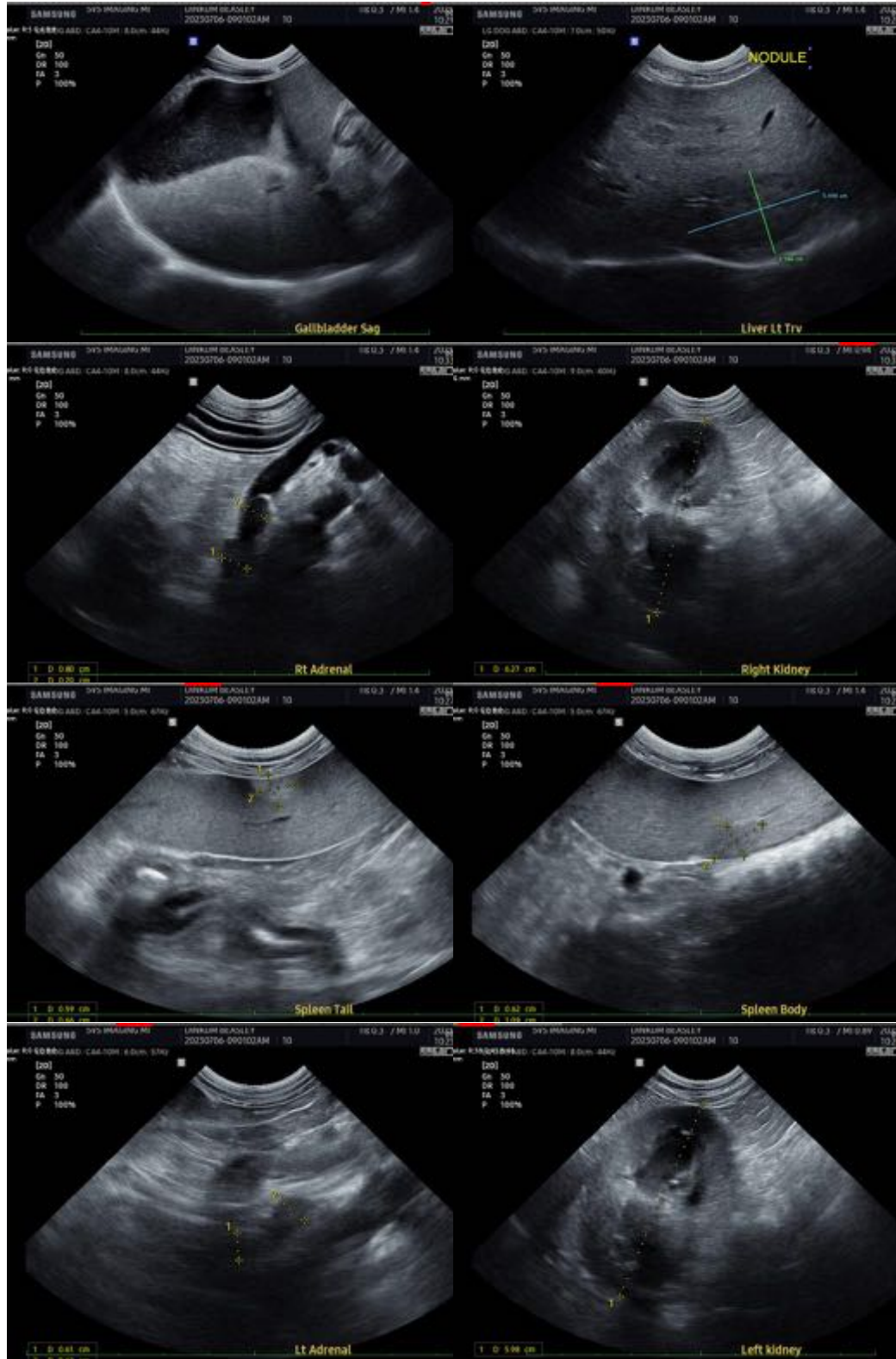
Dr. Marie Haddock

**INVOICE**

13590

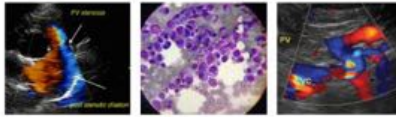
**DATE**

7.6.23



IMAGING PERFORMED BY

svsimagingqc.net 309-737-3070



Clinical Sonography & Telecytology

EDUCATIONAL TELECONSULTATION SERVICES™

1-800-838-4268 info@sonopath.com SonoPath.com

**PATIENT**

Dinkum Beasley

The information and recommendations provided are based on the images presented by the referring veterinarian. No evaluation can be communicated regarding pathology that was not visible in the image/video clips provided.

**SPECIES**

Canine

Thank you for this referral. If the clinical or image interpretation does not parallel your findings or if I can be of any further assistance, please contact me.

**BREED**

Boxer Mix

**Beth Johnson, DVM DACVIM**  
info@SonoPath.com

**SEX**

Female Spayed

**AGE**

10.5 years

**WEIGHT**

46.60 lbs

**INTERPRETED BY**

Beth Johnson, DVM  
DACVIM

**IMAGING  
PERFORMED BY**

Amy Mayhew LVT

**HOSPITAL NAME**

SVS Imaging Michigan

**REFERRING VET**

Dr. Marie Haddock

**INVOICE**

13590

**DATE**

7.6.23