

**DATE PRESENTING CLINICAL SIGNS**

7.6.2023 Decreased appetite, mild upper airway congestion, weight loss.

PATIENT

Abby Parrish

Current Medications: 7/5/23 started on 2.5mg Felimazole sid, Mirtazipine transdermal SID
 Lab Results: 7/3/23 alt 556, ast 180, alkphos 1,321, TBil 2.7, unconj. bili 1.5, conj. bili. 1.2; T4 5.0; UA -
 spgr. 1.017, + bilirubin
 Date of Previous IntraPet Ultrasound: No previous.
 Sedation: IM sedation given prior to arrival.
 Stat Report: Not requested.
 Imaging Performed By: Stephanie Warga RDCS, RVT.

SPECIES

Feline

ULTRASONOGRAPHIC EXAMINATION OF THE ABDOMEN**BREED**

DSH

SEX

Female Spayed

AGE

3/25/2007

WEIGHT

14.6 lbs

INTERPRETED BYBeth Johnson, DVM
DACVIM**HOSPITAL NAME**

Essex Middle River VC

REFERRING VET

Dr. Zulty

INVOICE

13595

Urinary System

Urinary bladder is adequately distended with anechoic contents. No masses, inflammatory changes, echogenic sediment or cystoliths are observed. The urinary bladder, trigone and visible pelvic urethra are normal in thickness with a smooth mucosal surface.

Left kidney is normal in size (4.24 cm), shape and echogenicity. It has smooth peripheral margination. There is a normal 1:3 cortex to medulla ratio with appropriate corticomedullary distinction. There is no evidence of pyelectasia, mineral or infarcts observed.

Right kidney is normal in size (3.92 cm), shape and echogenicity. It has smooth peripheral margination. There is a normal 1:3 cortex to medulla ratio with appropriate corticomedullary distinction. Pyelectasia is noted in the transverse view (0.24 cm). There is no evidence of mineral or infarcts observed.

Adrenal Glands

Left adrenal gland is normal in size (0.46 cm), shape and overall architecture, echogenicity and echotexture. Visible surrounding vasculature appears normal.

Right adrenal gland is normal in size (0.45 cm), shape and overall architecture, echogenicity and echotexture. Visible surrounding vasculature appears normal.

Spleen

Spleen is subjectively normal in size with a normal smooth capsular contour. Parenchyma is appropriately finely textured and homogenous with normal echogenicity relative to surrounding tissue (hyperechoic to liver). No focal nodules or masses are observed. Splenic vasculature appears normal.

Liver

Liver is subjectively enlarged (swollen contour). Mild parenchymal remodeling with diffusely mildly coarse architecture and increased portal markings is present. No focal nodules or masses are observed. Visible vasculature and biliary tree appear normal without distension or congestion.

Gallbladder is non-distended in size. The wall is smooth without visible thickening. Luminal contents are primarily anechoic. There is no evidence of cystic or common bile duct dilation.

Gastrointestinal

The visible stomach wall is normal in thickness and layering. The lumen of the stomach is empty with no evidence of obstruction, foreign material or infiltrative disease.

Diffusely, the visible small intestines are normal in wall thickness and layering. Small intestinal motility appears adequate (1-3 contractions per min). The lumen of the small intestine is empty with no evidence of

obstruction, foreign material or infiltrative disease. Focally, in the midabdomen, there is a bowel mass that appears to be jejunal (measuring 2.00 cm long), characterized by a concentric, heterogenous, primarily hypoechoic thick wall (measuring 0.47 cm thick) with complete loss of layering.

The visible colon is normal in wall thickness and layering. Contents are consistent with normal formed feces and gas.

Pancreas

The observed pancreas is prominent (enlarged) in size, hypoechoic to surrounding tissue and irregular in shape with a swollen undulating contour. Pancreatic duct dilation is noted. Enhanced hyperechoic ill-defined surrounding fat is noted.

Free Abdomen

There is a trace amount of anechoic free fluid adjacent to the bowel mass described above. . There is no apparent lymphadenopathy.

ULTRASONOGRAPHIC FINDINGS

Primary Findings

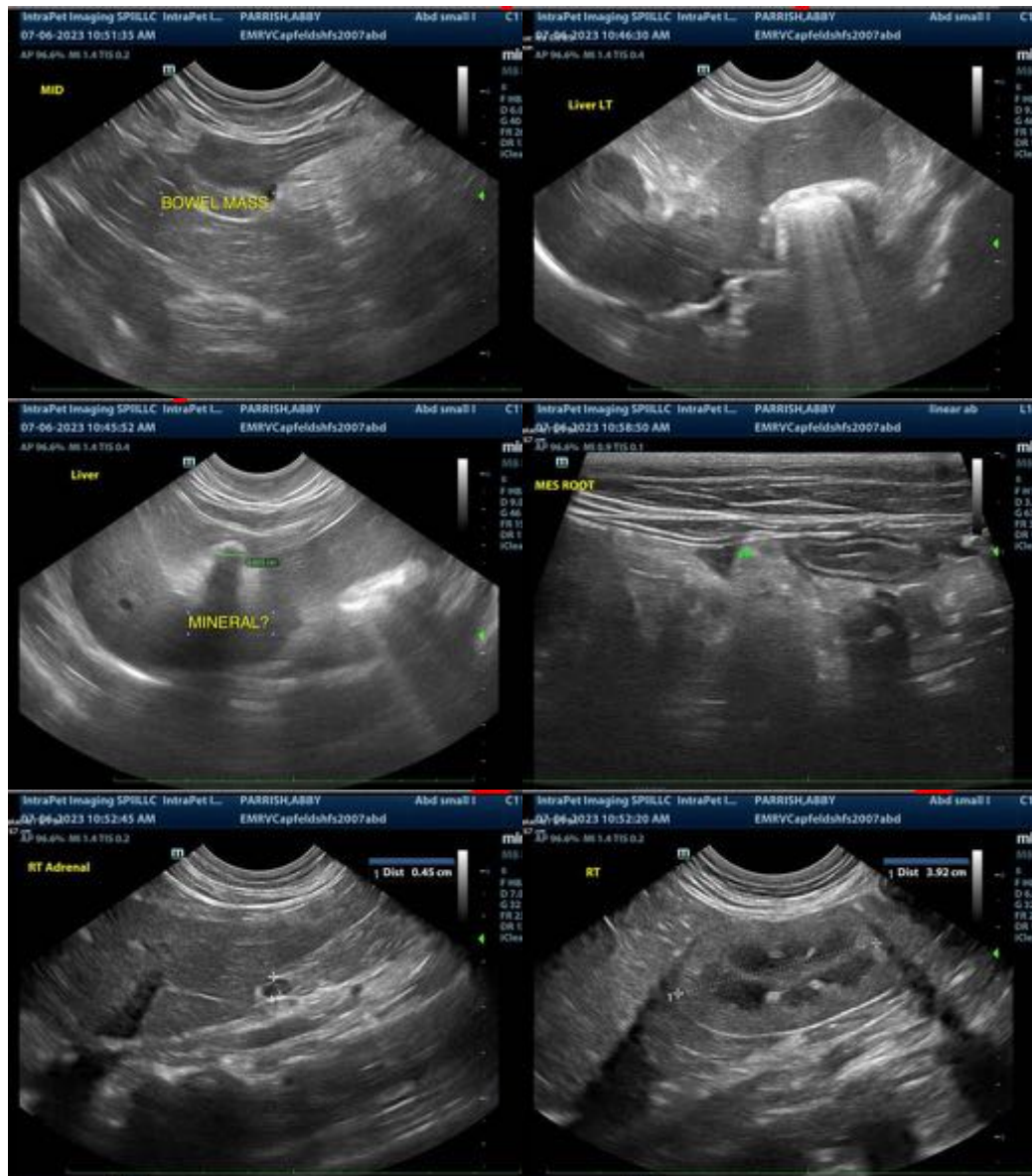- Aggressive mesenteric lymph nodes – most consistent with infiltrative round cell or metastatic neoplasia. A benign aggressive inflammatory response cannot be ruled out without tissue sampling +/- culture. Additionally, there is mild hypoechoic lymphadenopathy caudal to the stomach, adjacent to the pylorus and pancreas. Additionally, in the cranial abdomen, there is an approximately 0.80 cm curvilinear echogenic structure, with strong acoustic shadow, consistent with a mineral density that can't be definitively localized to GI tract, intrahepatic biliary system, versus potentially, a Bates body.
- A bowel mass that appears to be jejunum - Having said that, it is near the root of the mesentery, and adjacent to the ileocecolic junction, so involvement of the ileocecolic junction cannot be definitively ruled out. The appearance of the mass, given the loss of layering, is concerning for infiltrative neoplasia, such as round cell neoplasia (i.e., lymphoma) vs adenocarcinoma, vs other.
- Aggressive mesenteric lymph nodes – most consistent with infiltrative round cell or metastatic neoplasia. A benign aggressive inflammatory response cannot be ruled out without tissue sampling +/- culture.
- Hypoechoic hepatomegaly-This appearance is consistent with an acute hepatopathy or acute cholangiohepatitis. Infiltrative neoplasia (round cell neoplasia) should also be considered.
- Chronic smoldering pancreatitis is suspected.

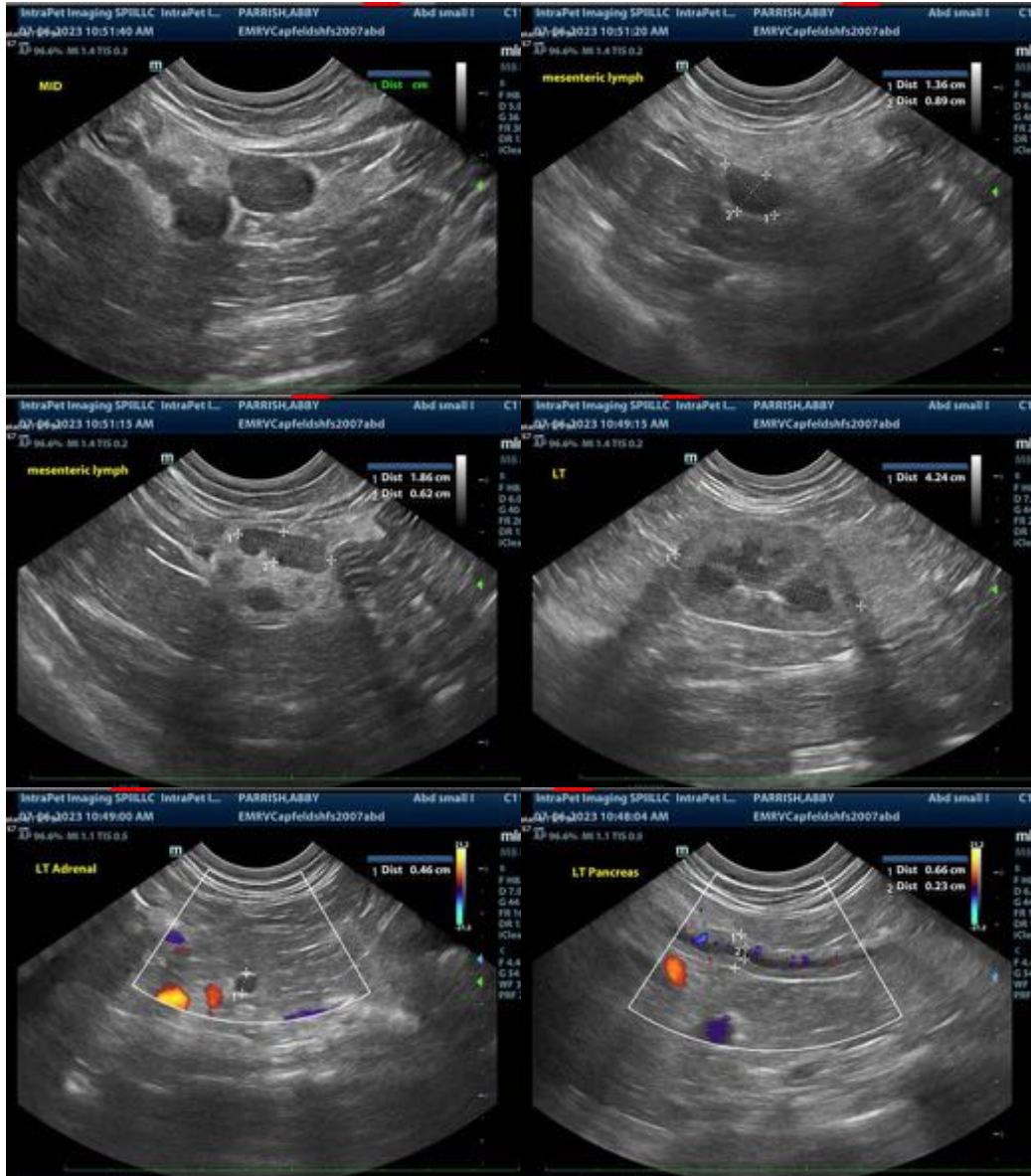
Secondary Findings

- Mild right kidney pyelectasia – Differentials for pyelectasia include pyelonephritis, diuresis, congenital malformation or ureteral or lower urinary tract obstruction.
- The mineral density in the cranial abdomen is likely intrahepatic biliary mineral, vs potentially, a Bates body. Either way, it appears nonobstructive and likely incidental. A trace amount of free fluid is noted adjacent to the bowel mass.

INTERPRETATION OF THE FINDINGS & FURTHER RECOMMENDATIONS

Given the pathology described above, infiltrative neoplasia (primarily round cell neoplasia such as lymphoma) is the top differential. Having said that, some contribution to the increased liver enzymes by the recently diagnosed hyperthyroidism, as well as potentially, some chronic inflammatory cholangiohepatitis, etc., cannot be definitively ruled out. Therefore, recommendations include fine-needle aspirates of the bowel mass, +/- mesenteric lymph node (if coagulation status of the patient is appropriate). In the meantime, medical management of hyperthyroidism is recommended, as is reportedly already in place. Additionally, treatment recommendations include fluid therapy, anti-emetics, gastroprotectants, hepatic nutraceuticals such as ursodiol and/or Denamarin, and broad-spectrum antibiotics. Nutritional support is critical to prevent/manage concurrent hepatic lipidosis, so appetite stimulants and/or, if indicated, feeding tube placement is also recommended.





The information and recommendations provided are based on the images presented by the referring veterinarian. No evaluation can be communicated regarding pathology that was not visible in the image/video clips provided.

Thank you for this referral. If the clinical or image interpretation does not parallel your findings or if I can be of any further assistance, please contact me.

Beth Johnson, DVM DACVIM
 info@SonoPath.com