



**PATIENT**

Piper Wong

**SPECIES**

Canine

**BREED**

Terrier X

**SEX**

Spayed Female

**AGE**

8.5 Years

**WEIGHT**

20 Pounds

**INTERPRETED BY**

Beth Johnson, DVM  
DACVIM

**IMAGING PERFORMED BY**

Dr. Christina Sitton

**HOSPITAL NAME**

Sherwood Family PC

**REFERRING VET**

Dr. Christina Sitton

**INVOICE**

39264

**DATE**

7/6/22

**PRESENTING CLINICAL SIGNS**

elevated liver values, progressing dermal mast cell removal in 1/2022  
Abnormal PE/Chem/CBC/UA Results: ALT 433 (18-121); was 136 ALP 1353 (5-160); was 1175, 792 otherwise chem11/CBC: wnl

**ULTRASONOGRAPHIC EXAMINATION OF THE ABDOMEN**

**Urinary System**

The urinary bladder is only mildly distended (empty). Visible contents are anechoic. Urinary bladder wall is unable to be fully assessed for pathology without further distension. No visible masses or cystoliths are observed. The trigone and visible pelvic urethra are normal thickness with a smooth mucosal surface. If there are urinary signs and/or concern for urinary bladder pathology, reassessment after complete filling is recommended.

The right kidney is normal in size (5.0 cm) and shape with smooth peripheral margination. A normal 1:3 cortex to medulla ratio is maintained. The medulla and cortices are uniform in texture with some mild increased echogenicity and mild loss of corticomedullary distinction. There is no evidence of pyelectasia, mineral or infarcts observed.

The left kidney is normal in size (4.2 cm) and shape with smooth peripheral margination. A normal 1:3 cortex to medulla ratio is maintained. The medulla and cortices are uniform in texture with some mild increased echogenicity and mild loss of corticomedullary distinction. There is no evidence of pyelectasia, mineral or infarcts observed.

**Adrenal Glands**

The right adrenal gland is normal in size (1.0 cm at the cranial pole and 0.47 cm at the caudal pole), shape and contour. Corticomedullary structure is unremarkable. Visible surrounding vasculature appears normal.

The left adrenal gland is normal in size (0.52 cm at the cranial pole and 0.63 cm at the caudal pole), shape and contour. Corticomedullary structure is unremarkable. Visible surrounding vasculature appears normal.

**Spleen**

The spleen is subjectively normal in size with a normal smooth capsular contour. Parenchyma is appropriately finely textured and homogenous with normal echogenicity relative to surrounding tissue (hyperechoic to liver). No focal nodules or masses are observed. Splenic vasculature appears normal.

**Liver**

Liver is subjectively enlarged. Margins are smooth but round. It has a normal homogenous echotexture. Parenchyma is diffusely hyperechoic characterized by less prominent than normal portal vein walls and increased echogenicity relative to the spleen. No focal lesions are observed. Visible vasculature and biliary tree appear normal without distension or congestion.

The gallbladder is non-distended in size. The wall is smooth without visible thickening. Luminal contents are primarily anechoic. There is no evidence of cystic or common bile duct dilation.

**Gastrointestinal**

The stomach wall is normal in thickness (canine < 0.5 cm and feline < 0.4 cm) and layering. The lumen of the stomach is mildly distended with echogenic non-shadowing luminal contents and gas consistent



**PATIENT**

Piper Wong

with normal ingesta. There is no evidence of obstruction, foreign material or infiltrative disease. Pyloric outflow tract appears patent.

**SPECIES**

Canine

The visible small intestines are normal in wall thickness and layering (canine duodenum < 0.5 cm and feline duodenum < 0.4 cm; other < 0.3 cm). Small intestinal motility appears adequate (1-3 contractions per min). The lumen of the small intestine is empty with no evidence of obstruction, foreign material or infiltrative disease.

**BREED**

Terrier X

The visible colon is normal in wall thickness (< 0.2 cm) and layering. Contents are consistent with normal formed feces and gas.

**SEX**

Spayed Female

***Pancreas***

The pancreatic parenchyma is appropriately isoechoic to surrounding tissue. Visible capsule is smooth and normal in contour. There is no visible pancreatic duct dilation. There is no evidence of active peripancreatic inflammation.

***Free Abdomen***

**AGE**

8.5 Years

There is no evidence of free peritoneal effusion noted in these images.

There is no apparent lymphadenopathy noted in these images.

**WEIGHT**

20 Pounds

**PRIMARY FINDINGS**

- Hyperechoic hepatomegaly – This appearance is non-specific and most consistent with a benign steroid (endocrine) or vacuolar hepatopathy or reactive or idiopathic hepatopathy. Inflammatory and/or infiltrative disease (such as round cell neoplasia) are also possible, but considered less likely.

**INTERPRETED BY**

Beth Johnson, DVM  
DACVIM

**SECONDARY FINDINGS**

- Age related kidney change – This finding is expected/consistent with age-related mild degenerative disease and should be interpreted clinically in combination with laboratory changes.

**IMAGING PERFORMED BY**

Dr. Christina Sitton

**INTERPRETATION OF THE FINDINGS & FURTHER RECOMMENDATIONS**

An obvious cause for the reported increased liver enzymes is not identified in these images. Microscopic disease such as Leptospirosis, bacterial cholangiohepatitis, chronic active hepatitis, copper-associated hepatotoxicity, other hepatotoxicity, infiltrative neoplasia (considered unlikely), etc. cannot be definitively ruled out.

**HOSPITAL NAME**

Sherwood Family PC

Recommendations include an “antigen search” for sources of reactive hepatopathy (including testing for Leptospirosis), followed by a course of empirical antibiotics and hepatic nutraceuticals, with monitoring of ALT for improvement. If improvement is not noted and/or enzyme increase progresses, a liver biopsy may be warranted.

**REFERRING VET**

Dr. Christina Sitton

Specifically for this patient, a fine needle aspirate of the liver is recommended, given the reported history of mast cell tumor, with pre-medication with diphenhydramine.

**INVOICE**

39264

**DATE**

7/6/22



**PATIENT**

Piper Wong

**SPECIES**

Canine

**BREED**

Terrier X

**SEX**

Spayed Female

**AGE**

8.5 Years

**WEIGHT**

20 Pounds

**INTERPRETED BY**

Beth Johnson, DVM  
DACVIM

**IMAGING PERFORMED BY**

Dr. Christina Sitton

**HOSPITAL NAME**

Sherwood Family PC

**REFERRING VET**

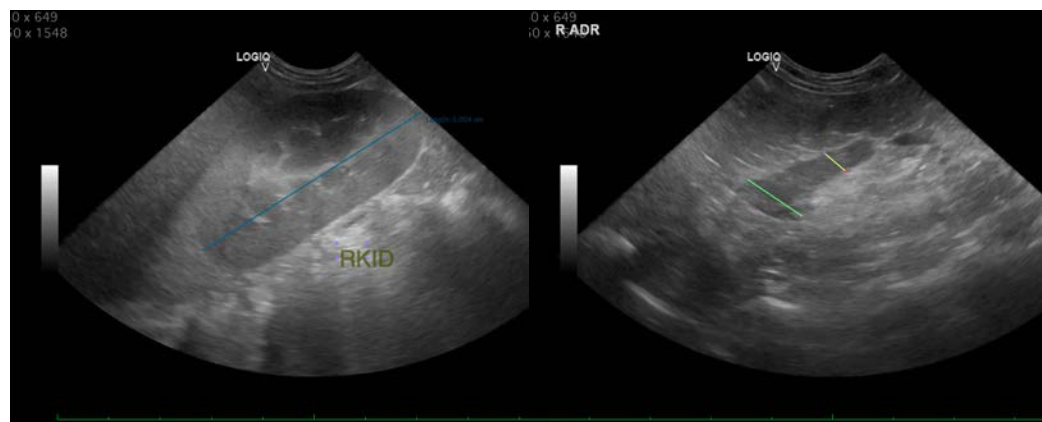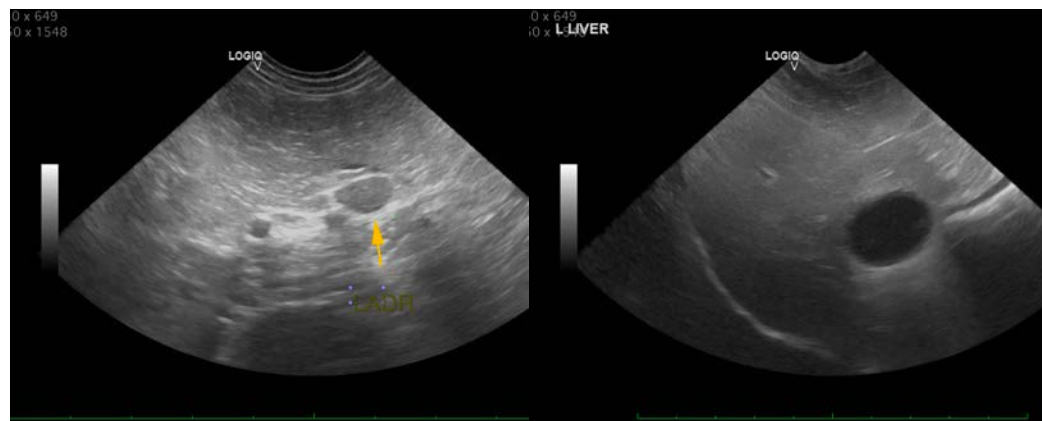
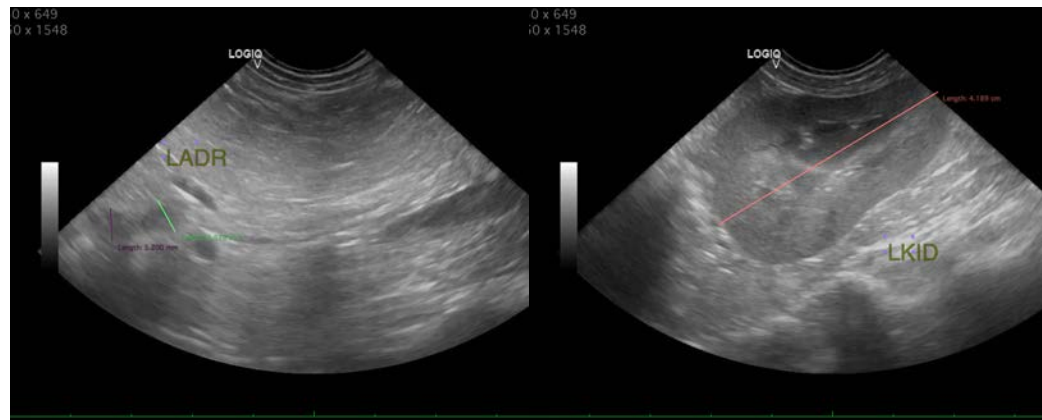Dr. Christina Sitton

**INVOICE**

39264

**DATE**

7/6/22





**PATIENT**

Piper Wong

**SPECIES**

Canine

**BREED**

Terrier X

**SEX**

Spayed Female

**AGE**

8.5 Years

**WEIGHT**

20 Pounds

**INTERPRETED BY**

Beth Johnson, DVM  
DACVIM

**IMAGING  
PERFORMED BY**

Dr. Christina Sitton

**HOSPITAL NAME**

Sherwood Family PC

**REFERRING VET**

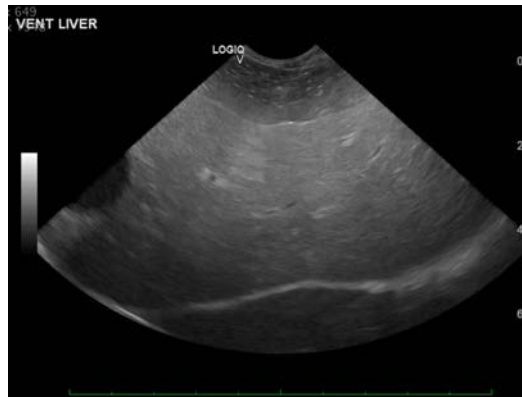Dr. Christina Sitton

**INVOICE**

39264

**DATE**

7/6/22



The information and recommendations provided are based on the images presented by the referring veterinarian/sonographer. No evaluation can be communicated regarding pathology that was not visible in the image/video clips provided.

Thank you for this referral. If the clinical or image interpretation does not parallel your findings or if I can be of any further assistance please contact me.

**Beth Johnson, DVM, DACVIM**  
Beth.Johnson@sonopath.com