

**DATE PRESENTING CLINICAL SIGNS**

7/5/22 Referral for ultrasound. Had 4dx, UA, CBC/chem/lytes /T4 abnormal below ALT 1,067 AST 218 ALP 606 GGT 41 Bilirubin - Total 1.3

**PATIENT** Bilirubin - Unconjugated 0.7 Bilirubin - Conjugated 0.6 Lipase 481 Creatine Kinase 326

Stella Vogt Current Medications: None listed.

Date of Previous IntraPet Ultrasound: No previous.

**SPECIES** Sedation: Not required to complete full diagnostic ultrasound.

Stat Report: Not requested.

Canine

**ULTRASONOGRAPHIC EXAMINATION OF THE ABDOMEN****BREED****Urinary System**

German Shorthair  
Pointer

The urinary bladder is moderately distended with anechoic contents. No masses, inflammatory changes, echogenic sediment or cystoliths are observed. The urinary bladder, trigone and visible pelvic urethra are normal in thickness with a smooth mucosal surface.

**SEX**

Spayed Female

The right kidney is normal in size (5.28 cm), shape and echogenicity. It has smooth peripheral margination. There is a normal 1:3 cortex to medulla ratio with appropriate corticomedullary distinction. There is no evidence of pyelectasia, mineral or infarcts observed.

**AGE**

3/1/10

The left kidney is normal in size (6.32 cm), shape and echogenicity. It has smooth peripheral margination. There is a normal 1:3 cortex to medulla ratio with appropriate corticomedullary distinction. There is no evidence of pyelectasia, mineral or infarcts observed.

**WEIGHT**

N/A

**Adrenal Glands****INTERPRETED BY**

Beth Johnson, DVM  
DACVIM

The right adrenal gland is normal in size (2.28 cm long x 0.95 cm at the cranial pole and 0.79 cm at the caudal pole), shape and contour. Corticomedullary structure is unremarkable. Visible surrounding vasculature appears normal.

The left adrenal gland is normal in size (2.55 cm long x 0.71 cm at the cranial pole and 0.82 cm at the caudal pole), shape and contour. Corticomedullary structure is unremarkable. Visible surrounding vasculature appears normal.

**IMAGING PERFORMED BY**

Rachel Brilhart RDMS

**Spleen****HOSPITAL NAME**

Animal Emergency  
Hospital

The spleen is subjectively large in size with a mildly swollen but smooth capsule. Parenchyma is normal and homogenous in echogenicity and echotexture. No focal nodules or masses are observed. Splenic vasculature appears normal.

**Liver****REFERRING VET**

Dr. King

The liver is subjectively enlarged with mildly irregular margins. Parenchyma is heterogenous characterized by multiple diffuse poorly defined hypoechoic nodules within otherwise hyperechoic liver parenchyma. A focal 6.0 cm x 8.0 cm, heterogeneous, partially cavitated mass is noted in the dorsocranial right liver. Visible vasculature and biliary tree appear normal without distension or congestion.

**INVOICE**

39205

The gallbladder is non-distended in size. The wall is smooth without visible thickening. Luminal contents are primarily anechoic. There is no evidence of cystic or common bile duct dilation.

**Gastrointestinal**

The stomach wall is normal in thickness (canine < 0.5 cm and feline < 0.4 cm) and layering. The lumen of the stomach is empty with no evidence of obstruction, foreign material or infiltrative disease. Pyloric outflow tract appears patent.

The visible small intestines are normal in wall thickness and layering (canine duodenum < 0.5 cm and feline duodenum < 0.4 cm; other < 0.3 cm). Small intestinal motility appears adequate (1-3 contractions per min). The lumen of the small intestine is empty with no evidence of obstruction, foreign material or infiltrative disease.

The visible colon is normal in wall thickness (< 0.2 cm) and layering. Contents are consistent with normal formed feces and gas.

### ***Pancreas***

The pancreatic parenchyma is appropriately isoechoic to surrounding tissue. Visible capsule is smooth and normal in contour. There is no visible pancreatic duct dilation. There is no evidence of active peripancreatic inflammation.

### ***Free Abdomen***

There is a scant amount of anechoic free fluid between liver lobes.

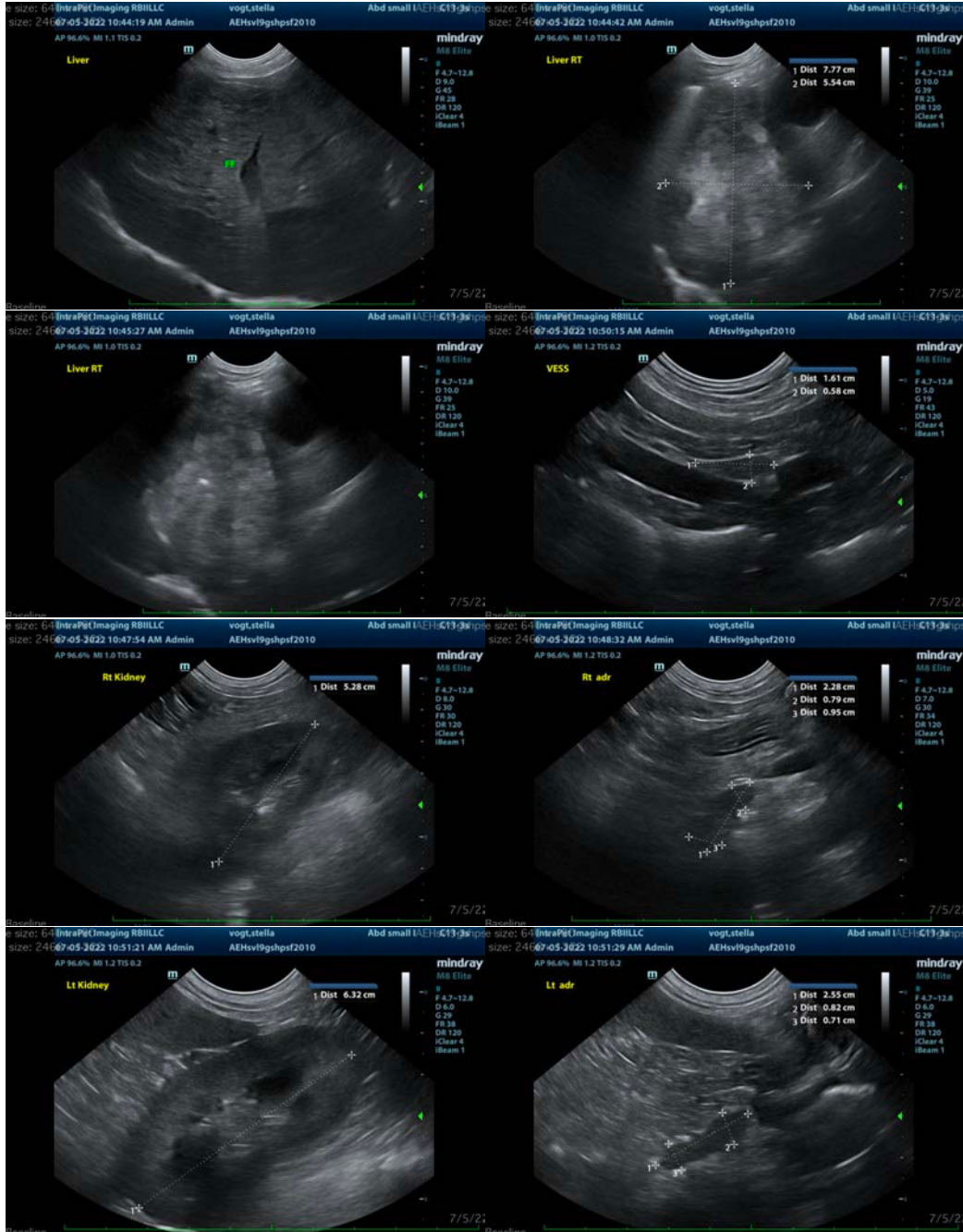
Medial iliac lymph nodes are prominent in size with swollen capsular contour. Normal elongated shape (length to width ratio) is maintained. There is no loss of parenchymal detail.

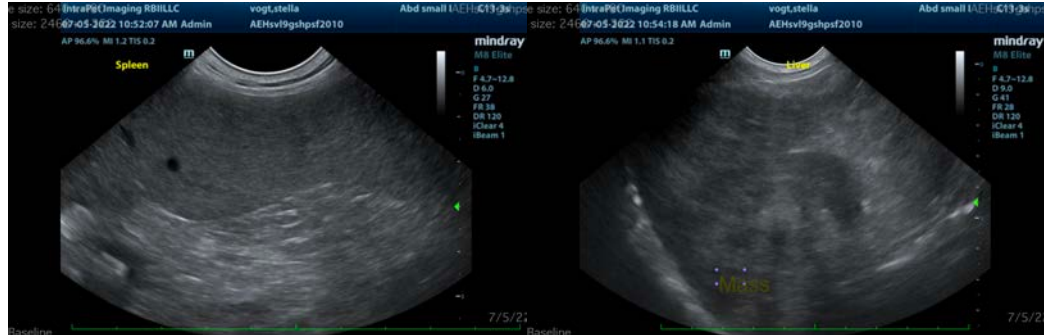## **ULTRASONOGRAPHIC FINDINGS**

- Heterogenous Liver – These changes are most consistent with benign processes such as nodular hyperplasia, steroid (vacuolar) hepatopathy, extramedullary hematopoiesis or possibly chronic inflammatory disease and less commonly infiltrative round cell or metastatic neoplasia.
- Focal heterogeneous liver mass - concerning for infiltrative neoplasia such as primary hepatocellular carcinoma versus hemangiosarcoma, versus other. Benign lesion is possible but considered less likely.
- Hypersplenism – can be associated with congestion caused by sedation (if sedated) but can also be associated with diffuse infiltrative disease. Both benign conditions such as extramedullary hematopoiesis, lymphoid hyperplasia, amyloidosis (leave amyloidosis out if canine) as well as infiltrative neoplastic diseases such as round cell neoplasia should be considered.
- Reactive medial iliac lymph nodes – infiltrative neoplastic disease cannot be ruled out but is considered less likely.

## **INTERPRETATION OF THE FINDINGS & FURTHER RECOMMENDATIONS**

- Three view thoracic radiographs are recommended for further assessment of cardio-pulmonary status as well as to further evaluate for any evidence of metastatic disease, if not recently evaluated.
- A fine needle aspirate of the liver mass could be considered if patient's coagulation status is appropriate. However, given the risk of hemorrhage, both from the aspirate as well as from the mass rupture in the future, surgical excisional biopsy/mass removal should be considered if an aggressive approach is elected. Given the likely difficulty of complete gross disease removal, a pre-surgical planning abdominal CT scan may be considered versus just understanding that full mass removal may not be possible at the time of surgery, if elected.





The information and recommendations provided are based on the images presented by the referring veterinarian/sonographer. No evaluation can be communicated regarding pathology that was not visible in the image/video clips provided.

Thank you for this referral. If the clinical or image interpretation does not parallel your findings or if I can be of any further assistance please contact me.

**Beth Johnson, DVM, DACVIM**  
Beth.Johnson@sonopath.com