



PATIENT

Annie Bryan

SPECIES

Canine

BREED

English Staffordshire Terrier

SEX

Spayed Female

AGE

9 Years 10 Months

WEIGHT

56.6 Pounds

INTERPRETED BY

Beth Johnson, DVM
DACVIM

IMAGING PERFORMED BY

Dr. Lucas Budden

HOSPITAL NAME

Frontier Vet Hospital

REFERRING VET

Dr. Lucas Budden

INVOICE

39226

DATE

7/5/22

PRESENTING CLINICAL SIGNS

Presented 5/24/2022 for vomiting once, decreased appetite, "balance issues," urinating intermittently in the house (postures, not when asleep). Fecal and GI supportive care started at that time. Presented again 6/12/2022 for vomiting, urinating in the house, not drinking much, staggering and running into things intermittently, and was leaning to one side. Lethargic for the week prior.

Abnormal PE/Chem/CBC/UA Results: Exam abnormalities 7/5/2022: moderate dental tartar, intrinsic staining 104, ambulatory with a stiff gait. Seems to lean to the left with a mild head tilt intermittently. Remainder of neuro exam normal. Full otic exam shows normal and intact TMs AU. Possible thinning of some retinal vessels on fundic exam OS, normal OD (menace present, PLRs normal/present indirect and direct OU). CBC/Chem/UA/T4 6/12/2022: Total protein high 7.6 ALP high 312 Creatinine normal 0.9 PSL high 219 Platelet high 440 USG 1.050 Protein 1+ Quiet sediment remainder CBC/Chem/T4/UA WNL Abdominal x-rays: CONCLUSIONS: -Mass like enlargement of the splenic body -The abdomen is normal otherwise -Consideration is made for a metabolic disorder. Particular consideration could be made for hypothyroidism or hyperproteinemia secondary to a protein-losing gastroenteropathy.

ULTRASONOGRAPHIC EXAMINATION OF THE ABDOMEN

Urinary System

The urinary bladder is moderately distended with anechoic contents. No masses, inflammatory changes, echogenic sediment or cystoliths are observed. The urinary bladder, trigone and visible pelvic urethra are normal in thickness with a smooth mucosal surface.

The right kidney is normal in size (6.68 cm) and shape with smooth peripheral margination. A normal 1:3 cortex to medulla ratio is maintained. The medulla and cortices are uniform in texture with some mild increased echogenicity and mild loss of corticomedullary distinction. There is no evidence of pyelectasia, mineral or infarcts observed.

The left kidney is normal in size (7.13 cm) and shape with smooth peripheral margination. A normal 1:3 cortex to medulla ratio is maintained. The medulla and cortices are uniform in texture with some mild increased echogenicity and mild loss of corticomedullary distinction. There is no evidence of pyelectasia, mineral or infarcts observed.

Adrenal Glands

The right adrenal gland is normal in size (0.76 cm at the cranial pole and 0.63 cm at the caudal pole), shape and contour. Corticomedullary structure is unremarkable. Visible surrounding vasculature appears normal.

The left adrenal gland is normal in size (0.63 cm at the cranial pole and 0.65 cm at the caudal pole), shape and contour. Corticomedullary structure is unremarkable. Visible surrounding vasculature appears normal.

Spleen

Spleen is subjectively enlarged in size with rounded margins but intact capsule. Parenchyma is homogeneously coarse/mottled in echotexture and normal to hypoechoic in echogenicity. Multifocal, well demarcated, discrete, hyperechoic, homogeneous nodules are noted throughout the parenchyma. Splenic vasculature appears normal.

Liver

The liver is subjectively normal in size with normal smooth curvilinear peripheral contour. Parenchyma is appropriately hypoechoic to the spleen in echogenicity and appropriately mildly coarse and



| | |
|-------------------------------|--|
| PATIENT | homogenous in echotexture. No focal lesions are observed. Visible vasculature and biliary tree appear normal without distension or congestion. |
| Annie Bryan | |
| SPECIES | The gallbladder is moderately distended with anechoic bile as well as suspended and gravity dependent echogenic debris. The wall is smooth without visible thickening. There is no evidence of cystic or CBD dilation. There is no evidence of effusion or inflammation. |
| Canine | |
| BREED | Gastrointestinal |
| English Staffordshire Terrier | The stomach wall is normal in thickness (canine < 0.5 cm and feline < 0.4 cm) and layering. The lumen of the stomach is mildly distended with echogenic non-shadowing luminal contents and gas consistent with normal ingesta. There is no evidence of obstruction, foreign material or infiltrative disease. Pyloric outflow tract appears patent. |
| SEX | The visible small intestines are normal in wall thickness and layering (canine duodenum < 0.5 cm and feline duodenum < 0.4 cm; other < 0.3 cm). Small intestinal motility appears adequate (1-3 contractions per min). The lumen of the small intestine is empty with no evidence of obstruction, foreign material or infiltrative disease. |
| Spayed Female | |
| AGE | The visible colon is normal in wall thickness (< 0.2 cm) and layering. Contents are consistent with normal formed feces and gas. |
| 9 Years 10 Months | |
| WEIGHT | Pancreas |
| 56.6 Pounds | The pancreatic parenchyma is appropriately isoechoic to surrounding tissue. Visible capsule is smooth and normal in contour. There is no visible pancreatic duct dilation. There is no evidence of active peripancreatic inflammation. |
| INTERPRETED BY | Free Abdomen |
| Beth Johnson, DVM DACVIM | There is no evidence of free peritoneal effusion noted in these images. |
| IMAGING PERFORMED BY | There is no apparent lymphadenopathy noted in these images. |
| Dr. Lucas Budden | |
| HOSPITAL NAME | PRIMARY FINDINGS |
| Frontier Vet Hospital | <ul style="list-style-type: none"> Coarse splenomegaly – can be associated with congestion caused by sedation (if sedated) but can also be associated with diffuse infiltrative disease. Both benign conditions such as extramedullary hematopoiesis, lymphoid hyperplasia, as well as infiltrative neoplastic diseases such as round cell neoplasia should be considered. Hyperechoic splenic nodules – may be faint myelolipomas. However, other differentials such as fibrosis of old hematomas or infarcts, chronic inflammation, granulomatous disease, or even metastatic disease cannot be ruled out. |
| REFERRING VET | SECONDARY FINDINGS |
| Dr. Lucas Budden | <ul style="list-style-type: none"> Age related kidney change – This finding is expected/consistent with age-related mild degenerative disease and should be interpreted clinically in combination with laboratory changes. Gallbladder debris - Cholecystic debris is of unknown clinical significance. It can be seen with biliary stasis from fasting or illness. Cholecystic debris is not necessarily related to hepatobiliary disease. Echogenic bile is most commonly an incidental finding in dogs and should be interpreted in combination with clinical signs such as nausea, inappetence, cranial abdominal discomfort and/or laboratory changes such as increased ALP and/or increased Tbili. |
| INVOICE | |
| 39226 | |
| DATE | |
| 7/5/22 | |



PATIENT

Annie Bryan

SPECIES

Canine

BREED

English Staffordshire Terrier

SEX

Spayed Female

AGE

9 Years 10 Months

WEIGHT

56.6 Pounds

INTERPRETED BY

Beth Johnson, DVM
DACVIM

IMAGING PERFORMED BY

Dr. Lucas Budden

HOSPITAL NAME

Frontier Vet Hospital

REFERRING VET

Dr. Lucas Budden

INVOICE

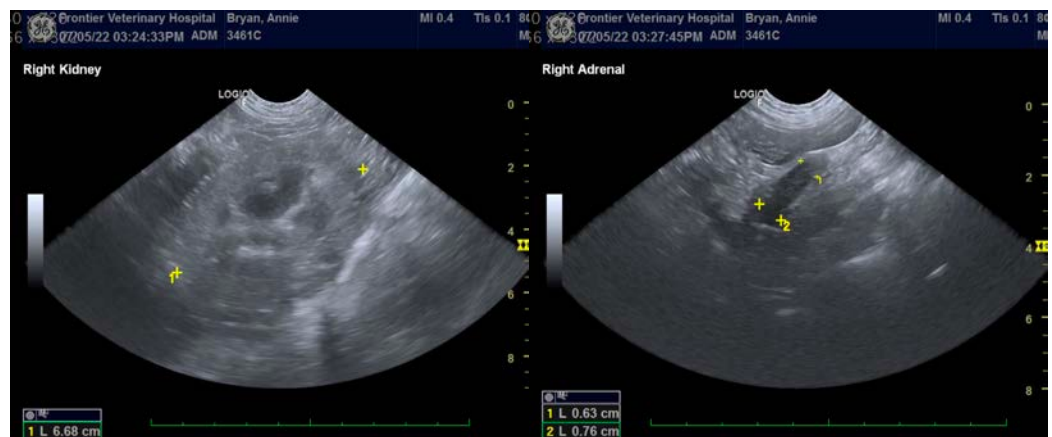
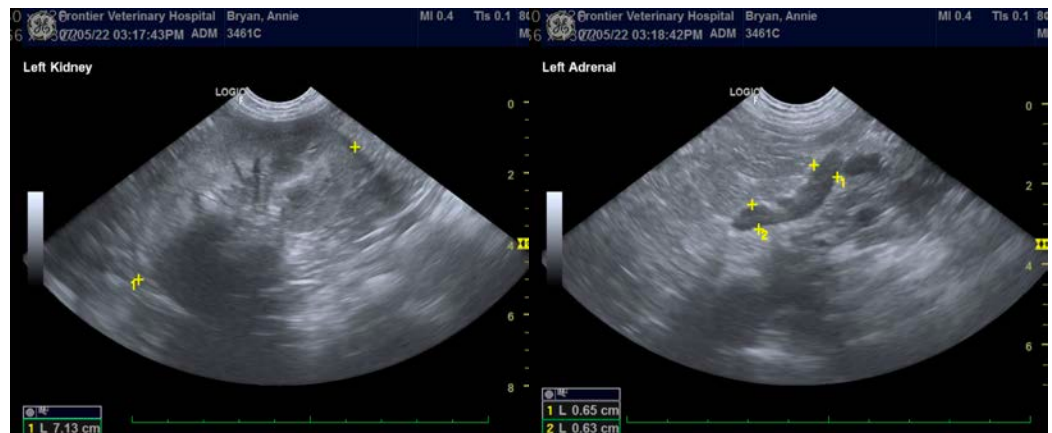
39226

DATE

7/5/22

INTERPRETATION OF THE FINDINGS & FURTHER RECOMMENDATIONS

- There is not an obvious ultrasonographic explanation for this patient's neurologic signs. To further evaluate possible underlying causes of vascular event/stroke activity, a urine protein to creatinine ratio is recommended if not recently evaluated, as is blood pressure.
- If clinical signs of hyperadrenocorticism are present, testing for hyperadrenocorticism in the form of a low-dose Dexamethasone suppression test could be evaluated to look for another underlying cause of a hypercoagulable state. However, testing is not indicated if clinical signs are not present. Without clinical signs, management is directed at hypertension, if present, and protein loss through the urine, if present.
- A fine needle aspirate of the spleen could be considered if patient's coagulation status is appropriate. However, the splenic changes are likely incidental and unrelated.
- If an underlying metabolic cause cannot be determined, follow up evaluation by a neurologist for potential advanced imaging such as MRI may be warranted.





PATIENT

Annie Bryan

SPECIES

Canine

BREED

English Staffordshire
Terrier

SEX

Spayed Female

AGE

9 Years 10 Months

WEIGHT

56.6 Pounds

INTERPRETED BY

Beth Johnson, DVM
DACVIM

**IMAGING
PERFORMED BY**

Dr. Lucas Budden

HOSPITAL NAME

Frontier Vet Hospital

REFERRING VET

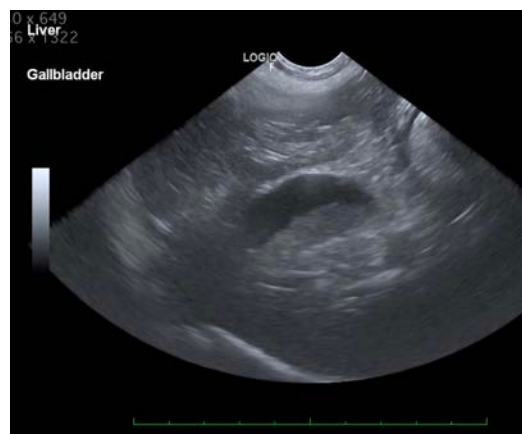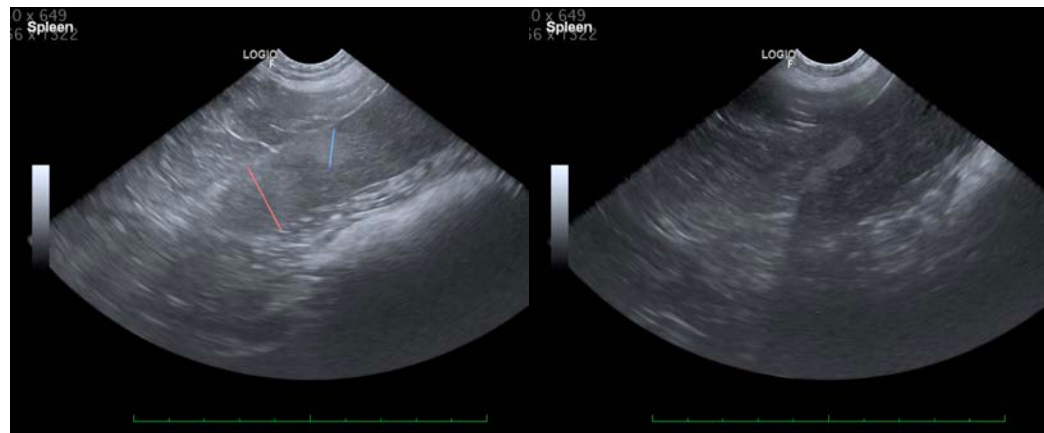
Dr. Lucas Budden

INVOICE

39226

DATE

7/5/22



The information and recommendations provided are based on the images presented by the referring veterinarian/sonographer. No evaluation can be communicated regarding pathology that was not visible in the image/video clips provided.

Thank you for this referral. If the clinical or image interpretation does not parallel your findings or if I can be of any further assistance please contact me.

Beth Johnson, DVM, DACVIM
Beth.Johnson@sonopath.com