



PATIENT PRESENTING CLINICAL SIGNS

Tucker Atkins
Patient adopted from a rescue age uncertain not as old as indicated probably around 10 years old Lethargic and hypoxic has had recurrent diarrhea and some vomiting. Has a hump in spine when walking. Also a history of bladder stones. On Urinary SO Painful To probe pressure in cranial abdomen.

SPECIES

Feline
Abnormal PE/Chem/CBC/UA Results: Had a normal T4 attending put on meds for hyperthyroid but discontinued now.

BREED

DSH

SEX

Neutered Male

AGE

15

WEIGHT

6.3 kg

INTERPRETED BY

Beth Johnson, DVM
DACVIM

IMAGING PERFORMED BY

Dr. Belan

HOSPITAL NAME

Ramsay Animal Clinic

REFERRING VET

Dr. Gupta

INVOICE

43727

DATE

7/4/23

ULTRASONOGRAPHIC EXAMINATION OF THE ABDOMEN

Urinary System

Urinary bladder is adequately distended. It has a normal uniform wall thickness. Contents include primarily anechoic fluid with occasional echogenic non-shadowing debris, most consistent with incidental suspended lipid in a cat, possibly combined with exfoliated cells, mucous and/or small blood clots. Both sterile inflammation as well as urinary tract infection can also present with echogenic debris. No masses or cystoliths are observed. The trigone and visible pelvic urethra are normal in thickness with a smooth mucosal surface. In the ventral bladder wall there is a 1.3 cm long x 0.16 cm thick hyperechoic foci reported to be a possible scar, potentially from a previous cystotomy given this patient's history of urinary bladder stones, but history of cystotomy is unknown.

The right kidney is normal in size (3.85 cm), shape and echogenicity. It has smooth peripheral margination. There is a normal 1:3 cortex to medulla ratio with appropriate corticomedullary distinction. A chronic infarct is noted in the cranial pole of the right kidney. There is no evidence of pyelectasia, mineral or infarcts observed.

The left kidney is normal in size (4.0 cm), shape and echogenicity. It has smooth peripheral margination. There is a normal 1:3 cortex to medulla ratio with appropriate corticomedullary distinction. There is no evidence of pyelectasia, mineral or infarcts observed.

Adrenal Glands

The right adrenal gland is normal in size (0.43 cm), shape and contour. Corticomedullary structure is unremarkable. Visible surrounding vasculature appears normal.

The left adrenal gland is normal in size (0.42 cm at the cranial pole and 0.29 cm at the caudal pole), shape and contour. Corticomedullary structure is unremarkable. Visible surrounding vasculature appears normal.

Spleen

The spleen is subjectively normal in size with a normal smooth capsular contour. Parenchyma is appropriately finely textured and homogenous with normal echogenicity relative to surrounding tissue (hyperechoic to liver). No focal nodules or masses are observed. Splenic vasculature appears normal.

Liver

The liver is subjectively normal in size with normal smooth curvilinear peripheral contour. Parenchyma is appropriately hypoechoic to the spleen in echogenicity and appropriately mildly coarse and homogenous in echotexture. No focal lesions are observed. Visible vasculature and biliary tree appear normal without distension or congestion.



PATIENT

Tucker Atkins

The gallbladder is non-distended in size. The wall is smooth without visible thickening. Luminal contents are primarily anechoic. The cystic and common bile duct are tortuous in appearance without pathologic distention, which is often a normal anatomic variant in senior cats.

SPECIES

Feline

Gastrointestinal

The stomach wall is normal in thickness (canine < 0.5 cm and feline < 0.4 cm) and layering. The lumen of the stomach is empty with no evidence of obstruction, foreign material or infiltrative disease. Pyloric outflow tract appears patent.

BREED

DSH

The visible small intestine demonstrates areas of thick muscularis layer relative to mucosa (disruption of the normal 1:3 muscularis:mucosa ratio). Small intestinal submucosa is slightly irregular, thick and hyperechoic, without evident loss of layering appreciated. The lumen is empty with no evidence of obstruction or foreign material.

SEX

Neutered Male

The visible colon is normal in wall thickness (< 0.2 cm) and layering. Contents are consistent with normal formed feces and gas.

AGE

15

Pancreas

The observed pancreas appears appropriately isoechoic to surrounding omental fat. The capsule is mildly irregular in shape. Parenchyma is mildly heterogenous and coarse. There is no visible pancreatic duct dilation. There is no evidence of active peripancreatic inflammation.

WEIGHT

6.3 kg

Free Abdomen

INTERPRETED BY

Beth Johnson, DVM
DACVIM

There is no evidence of free peritoneal effusion noted in these images.

The mesenteric lymph nodes are prominent in size with swollen capsular contour. Normal elongated shape (length to width ratio) is maintained. There is no loss of parenchymal detail.

IMAGING PERFORMED BY

Dr. Belan

PRIMARY FINDINGS

- **Inflammatory bowel disease (IBD) pattern** – Thick muscularis has been reported with infiltrative bowel disease including both benign inflammatory disease as well as infiltrative neoplasia such as lymphoma. No aggressive lymphadenopathy, loss of layering, etc. is noted to make lymphoma more probable, but lymphoma cannot be definitively ruled out without tissue sampling.
- **Reactive mesenteric lymph nodes** – infiltrative neoplastic disease cannot be ruled out but is considered less likely.
- **Pancreatic age-related remodeling** – Mild irregularities are consistent with benign age-related change. Low-grade smoldering chronic pancreatitis cannot be ruled out and should be suspected in the face of appropriate clinical signs.

HOSPITAL NAME

Ramsay Animal Clinic

REFERRING VET

Dr. Gupta

INVOICE

43727

DATE

7/4/23

SECONDARY FINDINGS

- Chronic infarct in the cranial pole of the right kidney
- Urinary bladder debris as well as a hyperechoic density in the ventral wall, consistent with the reported history of a possible scar.



PATIENT

Tucker Atkins

SPECIES

Feline

BREED

DSH

SEX

Neutered Male

AGE

15

WEIGHT

6.3 kg

INTERPRETED BY

Beth Johnson, DVM
DACVIM

IMAGING PERFORMED BY

Dr. Belan

HOSPITAL NAME

Ramsay Animal Clinic

REFERRING VET

Dr. Gupta

INVOICE

43727

DATE

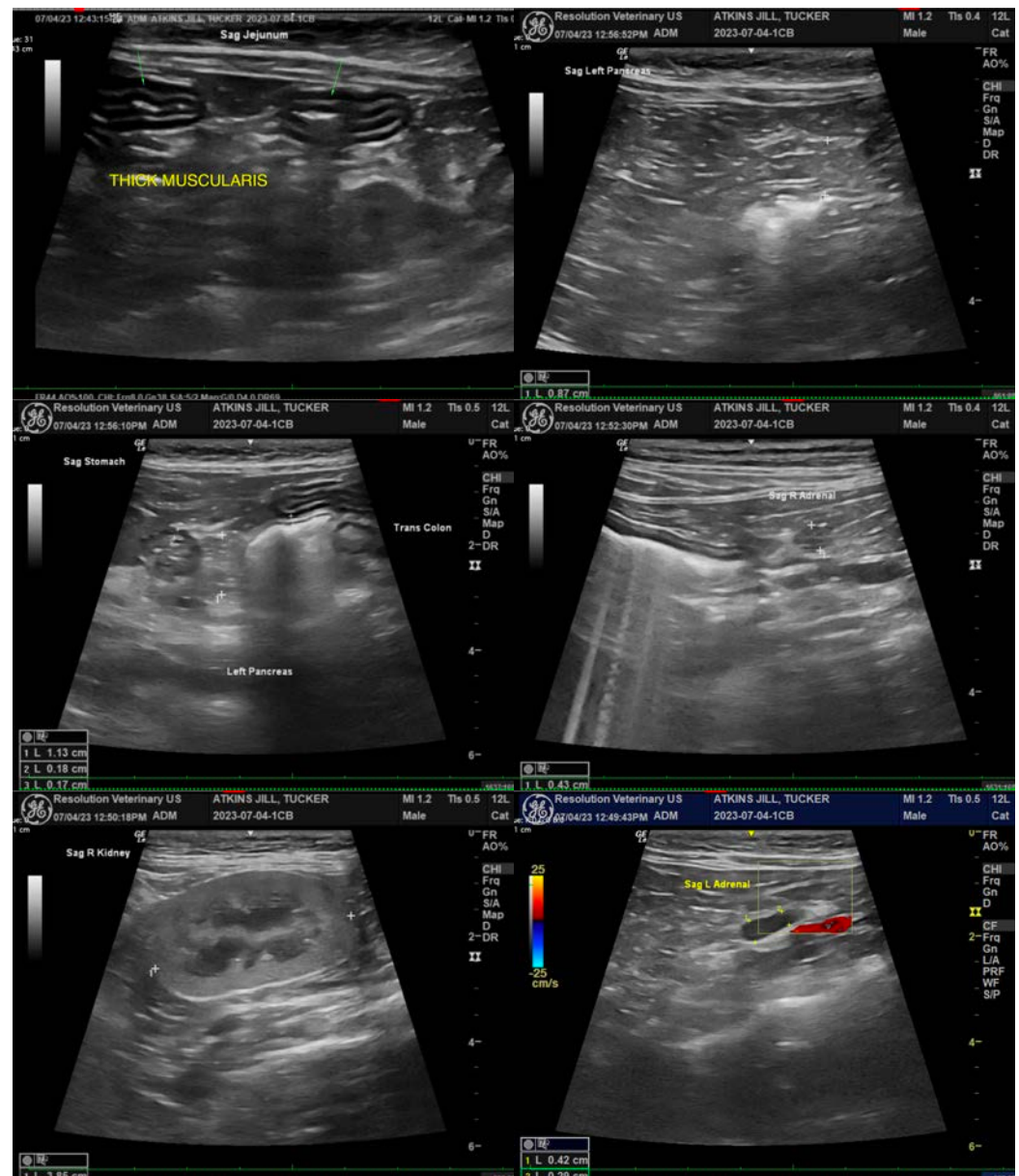
7/4/23

INTERPRETATION OF THE FINDINGS & FURTHER RECOMMENDATIONS

A gastrointestinal malabsorption panel (including cobalamin, folate, TLI and PLI) to Texas A&M GI Laboratory is recommended for further evaluation of GI and pancreatic function.

Ideally, biopsies of the GI tract, being sure to include ileum if possible, are recommended to definitively diagnose and therefore manage the infiltrative bowel disease.

If biopsies cannot be obtained, empirical therapies could include diet change, empirical deworming with a 5 day course of Panacur, cobalamin supplementation (unless cobalamin level is evaluated and supplementation is not warranted) and prednisolone (if not contraindicated based on patient contraindications, co-morbidities, etc.). Other supportive therapeutic considerations could include fiber supplementation, especially with large bowel diarrhea and/or a probiotic.





PATIENT

Tucker Atkins

SPECIES

Feline

BREED

DSH

SEX

Neutered Male

AGE

15

WEIGHT

6.3 kg

INTERPRETED BY

Beth Johnson, DVM
DACVIM

IMAGING PERFORMED BY

Dr. Belan

HOSPITAL NAME

Ramsay Animal Clinic

REFERRING VET

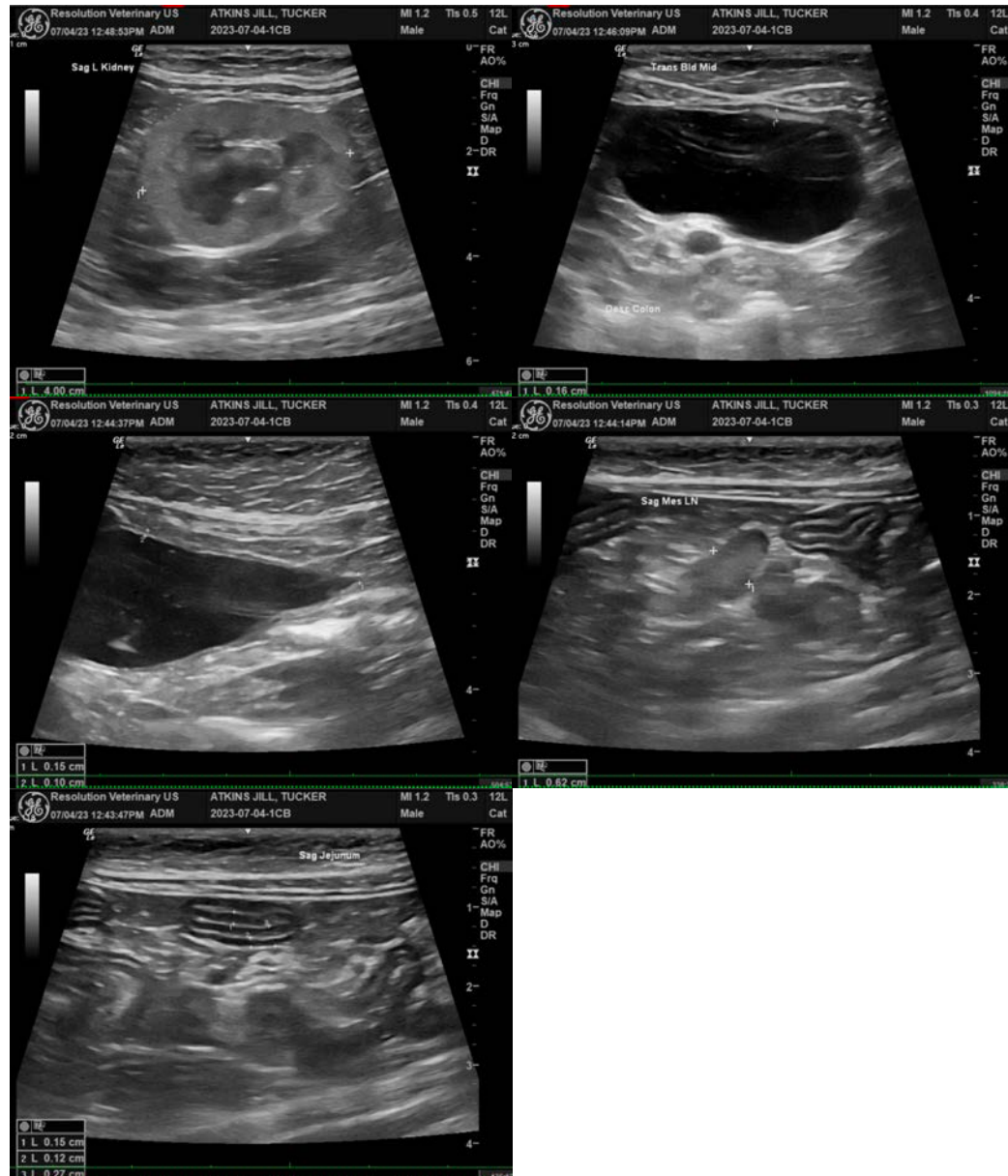Dr. Gupta

INVOICE

43727

DATE

7/4/23



The information and recommendations provided are based on the images presented by the referring veterinarian/sonographer. No evaluation can be communicated regarding pathology that was not visible in the image/video clips provided.

Thank you for this referral. If the clinical or image interpretation does not parallel your findings or if I can be of any further assistance please contact me.

Beth Johnson, DVM, DACVIM
info@sonopath.com