

**DATE PRESENTING CLINICAL SIGNS**

7/31/23

History: Painful in back end, having difficulty going up steps. Stiff hips, mild reaction to palpation of stifle and lumbar vertebrae. Many subcutaneous masses and adenomas.

PATIENT

Stella Mills

Current Medications: Gabapentin 100mg 2 caps BID, Dasuquin, Ellevet
 Lab Results: CBC WNL. Chem: ALP 513, history of elevated ALP 10/22= 619

SPECIES

Radiographs: Hip Displasia, stifle effusion mild; Much gas in intestines, ingesta in stomach. Mass effect mid abdomen, prominent spleen.

Canine

Date of Previous IntraPet Ultrasound: No previous.

BREED

Sedation: Not required to complete full diagnostic ultrasound.

Labradoodle

Stat Report: Not requested.

Imaging Performed By: Rachel Brillhart, RDMS.

SEX**ULTRASONOGRAPHIC EXAMINATION OF THE ABDOMEN**

Spayed Female

Urinary System

Urinary bladder is adequately distended with anechoic contents. No masses, inflammatory changes, echogenic sediment or cystoliths are observed. The urinary bladder, trigone and visible pelvic urethra are normal in thickness with a smooth mucosal surface.

AGE

11/2/11

Left kidney is normal is size (6.18 cm), shape and echogenicity. It has smooth peripheral margination. There is a normal 1:3 cortex to medulla ratio with appropriate corticomedullary distinction. There is no evidence of pyelectasia, mineral or infarcts observed.

WEIGHT

70.6 Pounds

Right kidney is normal is size (7.51 cm), shape and echogenicity. It has smooth peripheral margination. There is a normal 1:3 cortex to medulla ratio with appropriate corticomedullary distinction. There is no evidence of pyelectasia, mineral or infarcts observed.

INTERPRETED BYBeth Johnson, DVM
DACVIM**Adrenal Glands**

Left adrenal gland is normal in size (0.67 cm at cranial pole and 0.76 cm at caudal pole), shape and overall architecture, echogenicity and echotexture. Visible surrounding vasculature appears normal.

HOSPITAL NAME

Jacksonville VH

Right adrenal gland is normal in size (0.76 cm at cranial pole and 0.74 cm at caudal pole), shape and overall architecture, echogenicity and echotexture. Visible surrounding vasculature appears normal.

Spleen**REFERRING VET**

Dr. Burk

Spleen is subjectively large in size with a mildly swollen but smooth capsule. Parenchyma is normal and homogenous in echogenicity and echotexture. A 1.4 cm x 1.5 cm non-capsule-disrupting hypoechoic nodule is noted in the mid spleen. Splenic vasculature appears normal.

INVOICE

23734

Liver

Liver is subjectively normal in size with normal smooth curvilinear peripheral contour. Parenchyma is appropriately hypoechoic to the spleen in echogenicity and appropriately mildly coarse and homogenous in echotexture. No focal lesions are observed. Visible vasculature and biliary tree appear normal without distension or congestion.

Gallbladder is non-distended in size. The wall is smooth without visible thickening. Luminal contents are primarily anechoic. There is no evidence of cystic or common bile duct dilation.

Gastrointestinal

The visible stomach wall is normal in thickness and layering. The lumen of the stomach is mildly distended with very echogenic reverberation artifact from intraluminal gas. There is no evidence of obstruction, foreign material or infiltrative disease; however, complete visualization of far wall is partially inhibited by gas. Pyloric outflow tract appears patent.

The visible small intestines are normal in wall thickness and layering. Small intestinal motility appears adequate (1-3 contractions per min). The lumen of the small intestine is empty with no evidence of obstruction, foreign material or infiltrative disease.

The visible colon is normal in wall thickness and layering. Contents are consistent with normal formed feces and gas.

Pancreas

The observed pancreas appears appropriately isoechoic to surrounding omental fat. Visible capsule is smooth and normal in contour. Visible pancreatic parenchyma is homogenous and unremarkable. There is no visible pancreatic duct dilation. There is no evidence of active peripancreatic inflammation.

Free Abdomen

There is no evidence of peritoneal effusion. There is no apparent lymphadenopathy.

Other

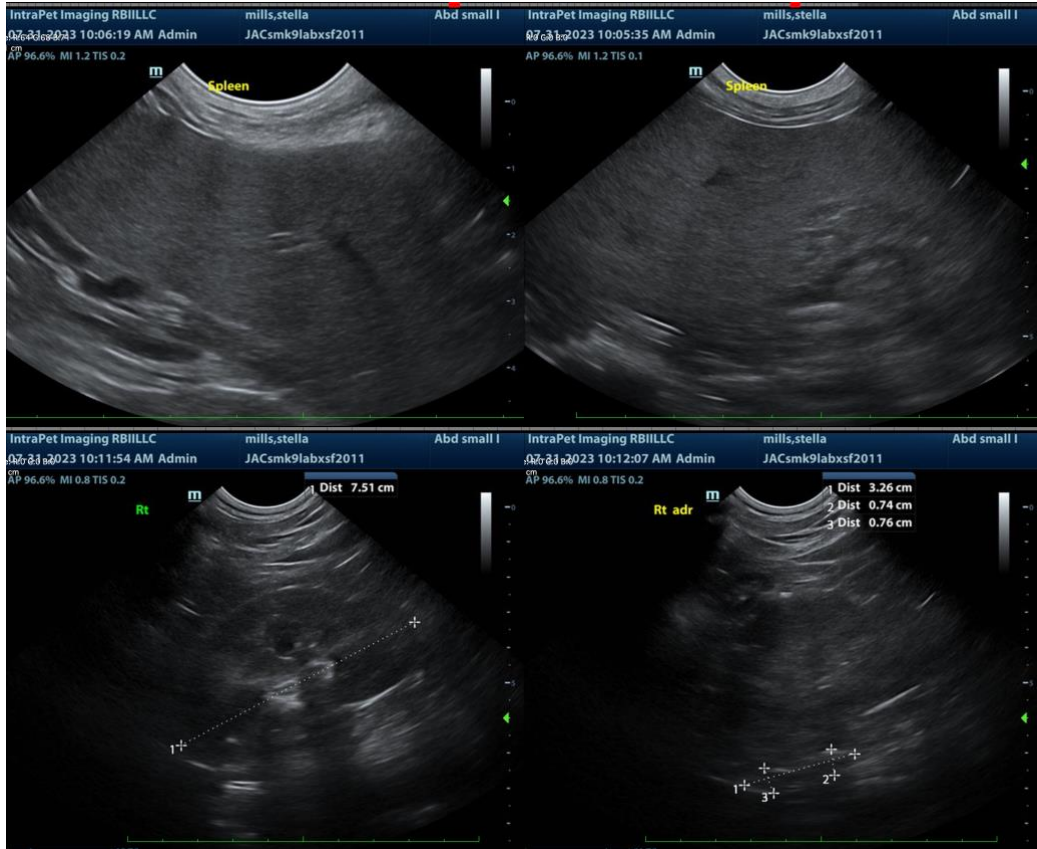
There is no evidence of heart base or pericardial pathology noted in these images at this time. If cardiac function evaluation is desired a full echocardiogram is recommended.

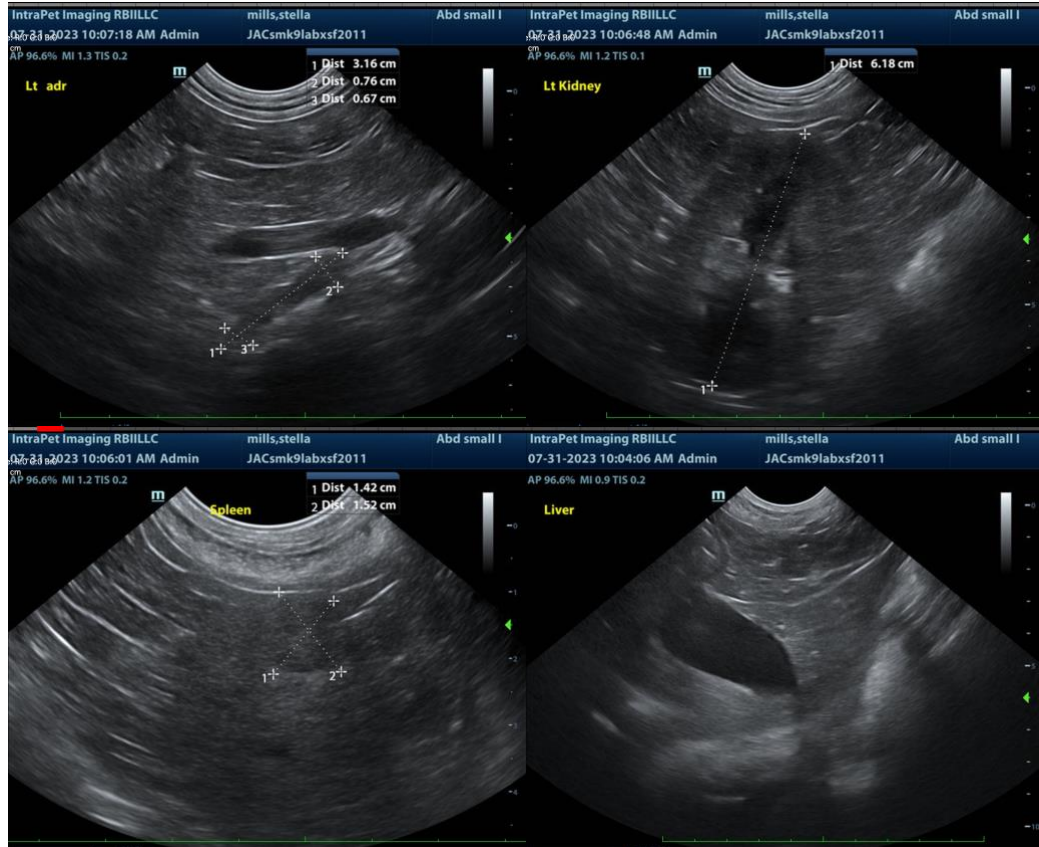
ULTRASONOGRAPHIC FINDINGS

- Hypersplenism with a hypo to anechoic splenic nodule – can be associated with congestion caused by sedation (if sedated) but can also be associated with diffuse infiltrative disease. Both benign conditions such as extramedullary hematopoiesis, lymphoid hyperplasia, as well as infiltrative neoplastic diseases such as round cell neoplasia should be considered. The hypo to anechoic splenic nodule likely represents a benign lesion such as a cyst, hematoma, nodular hyperplasia, extramedullary hematopoiesis, etc., however while considered less likely, infiltrative neoplasia can mimic benign lesions, and cannot be ruled out.

INTERPRETATION OF THE FINDINGS & FURTHER RECOMMENDATIONS

The appearance of the spleen trends toward benign, but a fine needle aspirate of the spleen could be considered if patients coagulation status is appropriate.





The information and recommendations provided are based on the images presented by the referring veterinarian. No evaluation can be communicated regarding pathology that was not visible in the image/video clips provided.

Thank you for this referral. If the clinical or image interpretation does not parallel your findings or if I can be of any further assistance please contact me.

Beth Johnson, DVM DACVIM
info@SonoPath.com