



<b>PATIENT</b>	<b>PRESENTING CLINICAL SIGNS</b>
Ace Gall	Referred for imaging for intermittent loose stool. Starting prescription weight loss food. Plucking fur out of his sides/stress grooming. Scooting.
<b>SPECIES</b>	
Feline	Abnormal PE/Chem/CBC/UA Results: CBC nsf Chem: Triglycerides- 194 (high), PSL 66 (high) Fecal negative; Felv/FIV negative; PE: BCS 9/9 obese, patchy hair thinning/loss on trunk of body.
<b>BREED</b>	<b>ULTRASONOGRAPHIC EXAMINATION OF THE ABDOMEN</b>
DLH	<b>Urinary System</b>
<b>SEX</b>	Urinary bladder is adequately distended. It has a normal uniform wall thickness. Contents include primarily anechoic fluid with occasional echogenic non-shadowing debris, most consistent with incidental suspended lipid in a cat, possibly combined with exfoliated cells, mucous and/or small blood clots. Both sterile inflammation as well as urinary tract infection can also present with echogenic debris. No masses or cystoliths are observed. The trigone and visible pelvic urethra are normal in thickness with a smooth mucosal surface.
Neutered Male	
<b>AGE</b>	
14 Years	Kidneys are overall normal in size and shape with smooth peripheral margination. A normal 1:3 cortex to medulla ratio is maintained. The medulla and cortices are uniform in texture with some mild increased cortical echogenicity and mild loss of corticomedullary distinction, expected in this age patient. There is no evidence of pyelectasia, mineral or infarcts observed. The right kidney measured 4.25 cm. The left kidney measured 4.17 cm.
<b>WEIGHT</b>	
18.5 Pounds	
<b>INTERPRETED BY</b>	<b>Adrenal Glands</b>
Beth Johnson, DVM DACVIM	The area of the right adrenal gland is examined without evident adrenal gland pathology.  The left adrenal gland is normal in size (0.32 cm at the cranial pole and 0.32 cm at the caudal pole), shape and contour. Corticomedullary structure is unremarkable. Visible surrounding vasculature appears normal.
<b>IMAGING PERFORMED BY</b>	<b>Spleen</b>
Brian Klug	Spleen is subjectively large in size with subtly scalloped or undulating capsular contour. Parenchyma is normal in echogenicity with a mildly coarse/heterogenous echotexture. No focal nodules or masses are observed. Splenic vasculature appears normal.
<b>HOSPITAL NAME</b>	<b>Liver</b>
Sondel Family VC	The liver is subjectively normal in size with normal smooth curvilinear peripheral contour. Parenchyma is appropriately hypoechoic to the spleen in echogenicity and appropriately mildly coarse and homogenous in echotexture. No focal lesions are observed. Visible vasculature and biliary tree appear normal without distension or congestion.
<b>REFERRING VET</b>	
Dr. Kara Wallisch	
<b>INVOICE</b>	
43719	The gallbladder is non-distended in size. The wall is smooth without visible thickening. Luminal contents are primarily anechoic. There is no evidence of cystic or common bile duct dilation.
<b>DATE</b>	<b>Gastrointestinal</b>
7/3/23	The stomach wall is normal in thickness (canine < 0.5 cm and feline < 0.4 cm) and layering. The lumen of the stomach is empty with no evidence of obstruction, foreign material or infiltrative disease. Pyloric outflow tract appears patent.



**PATIENT**

Ace Gall

The visible small intestine demonstrates areas of thick muscularis layer relative to mucosa (disruption of the normal 1:3 muscularis:mucosa ratio). Small intestinal submucosa is slightly irregular, thick and hyperechoic. In the mid abdomen there is a focal loop of believed to be jejunum measuring 1.2 cm long with loss of layering and an asymmetrical 0.70 cm hypoechoic wall thickening. The lumen is empty with no evidence of obstruction or foreign material.

**SPECIES**

Feline

The visible colon is normal in wall thickness (< 0.2 cm) and layering. Contents are consistent with normal formed feces and gas.

**BREED**

DLH

**Pancreas**

The pancreatic parenchyma is appropriately isoechoic to surrounding tissue. The visible capsule is smooth and normal in contour except for in the caudal left limb, where there is a 1.7 cm x 1.4 cm round anechoic structure that is believed to represent a pancreatic cyst/cystic lesion, as well as in the caudal right limb, where there is a 1.2 cm round hypoechoic nodule or potentially lymph node adjacent to the right pancreas. There is no visible pancreatic duct dilation. There is no evidence of active peripancreatic inflammation.

**SEX**

Neutered Male

**AGE**

14 Years

**Free Abdomen**

There is no evidence of free peritoneal effusion noted in these images.

**WEIGHT**

18.5 Pounds

The mesenteric lymph nodes are prominent in size with swollen capsular contour. Normal elongated shape (length to width ratio) is maintained. There is no loss of parenchymal detail.

**INTERPRETED BY**

Beth Johnson, DVM  
DACVIM

There is potentially an enlarged cranial lymph node adjacent to the right limb of the pancreas as described above.

**PRIMARY FINDINGS**

- Gastrointestinal lymphoma (suspect) pattern – Thick muscularis has been reported with infiltrative bowel disease including both benign inflammatory disease as well as infiltrative neoplasia such as lymphoma. Given the focal loss of layering described above, infiltrative neoplasia is considered more likely, but benign IBD cannot be ruled out without tissue sampling.
- Potential concurrent pancreatic nodular hyperplasia as well as a pancreatic cyst or potentially cranial abdominal lymphadenopathy, which is also concerning for lymphoma versus other.
- Scalloped spleen – can be associated with benign or malignant infiltrative disease. Common causes include a reactive spleen secondary to immune stimulus or early infiltrative round cell neoplasia such as lymphoma or mast cell tumor.

**IMAGING PERFORMED BY**

Brian Klug

**HOSPITAL NAME**

Sondel Family VC

**REFERRING VET**

Dr. Kara Wallisch

**INVOICE**

43719

**DATE**

7/3/23

**SECONDARY FINDINGS**

- Age related kidney changes
- Urinary bladder debris



**PATIENT**

Ace Gall

**SPECIES**

Feline

**BREED**

DLH

**SEX**

Neutered Male

**AGE**

14 Years

**WEIGHT**

18.5 Pounds

**INTERPRETED BY**

Beth Johnson, DVM  
DACVIM

**IMAGING PERFORMED BY**

Brian Klug

**HOSPITAL NAME**

Sondel Family VC

**REFERRING VET**

Dr. Kara Wallisch

**INVOICE**

43719

**DATE**

7/3/23

**INTERPRETATION OF THE FINDINGS & FURTHER RECOMMENDATIONS**

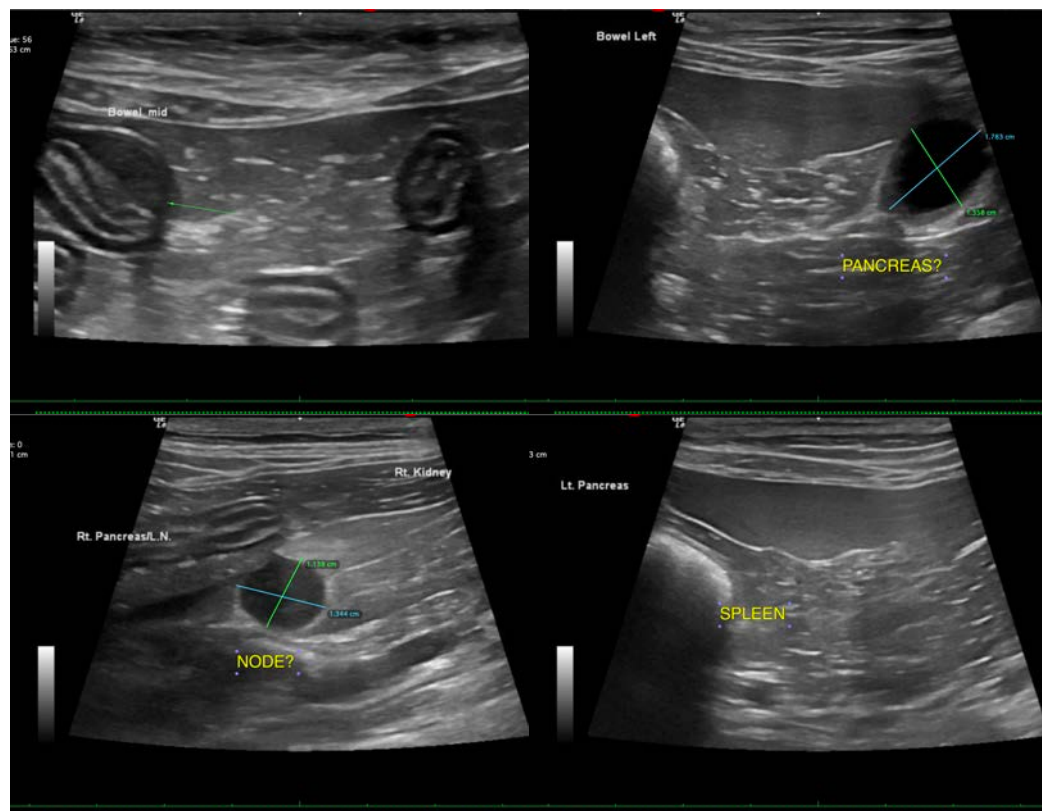
A gastrointestinal malabsorption panel (including cobalamin, folate, TLI and PLI) to Texas A&M GI Laboratory is recommended for further evaluation of GI and pancreatic function.

Tissue sampling is recommended to look for further evidence of infiltrative round cell disease such as lymphoma. Fine needle aspirates, if possible, of the focally thickened bowel as well as the cranial abdominal lymph nodes/pancreatic nodule +/- spleen, etc. could be considered if patient's coagulation status is appropriate.

If a cytologic diagnosis is not obtained, ideally, biopsies of the GI tract, being sure to include ileum if possible, are recommended to definitively diagnose and therefore manage the infiltrative bowel disease.

If biopsies cannot be obtained, empirical therapies could include a probiotic (if diarrhea is present, such as visbiome or proviable), empirical deworming with a 5-day course of Panacur and, if tolerated, a transition in diet, based on trial-and-error response, beginning with a hydrolyzed protein diet. Some patients respond to one brand/version of a hydrolyzed protein diet better than another brand, so several trials may be required.

Additional considerations could include cobalamin supplementation (unless cobalamin level is evaluated and supplementation is not warranted) and prednisolone (if not contraindicated based on patient contraindications, co-morbidities, etc.).





**PATIENT**

Ace Gall

**SPECIES**

Feline

**BREED**

DLH

**SEX**

Neutered Male

**AGE**

14 Years

**WEIGHT**

18.5 Pounds

**INTERPRETED BY**

Beth Johnson, DVM  
DACVIM

**IMAGING PERFORMED BY**

Brian Klug

**HOSPITAL NAME**

Sondel Family VC

**REFERRING VET**

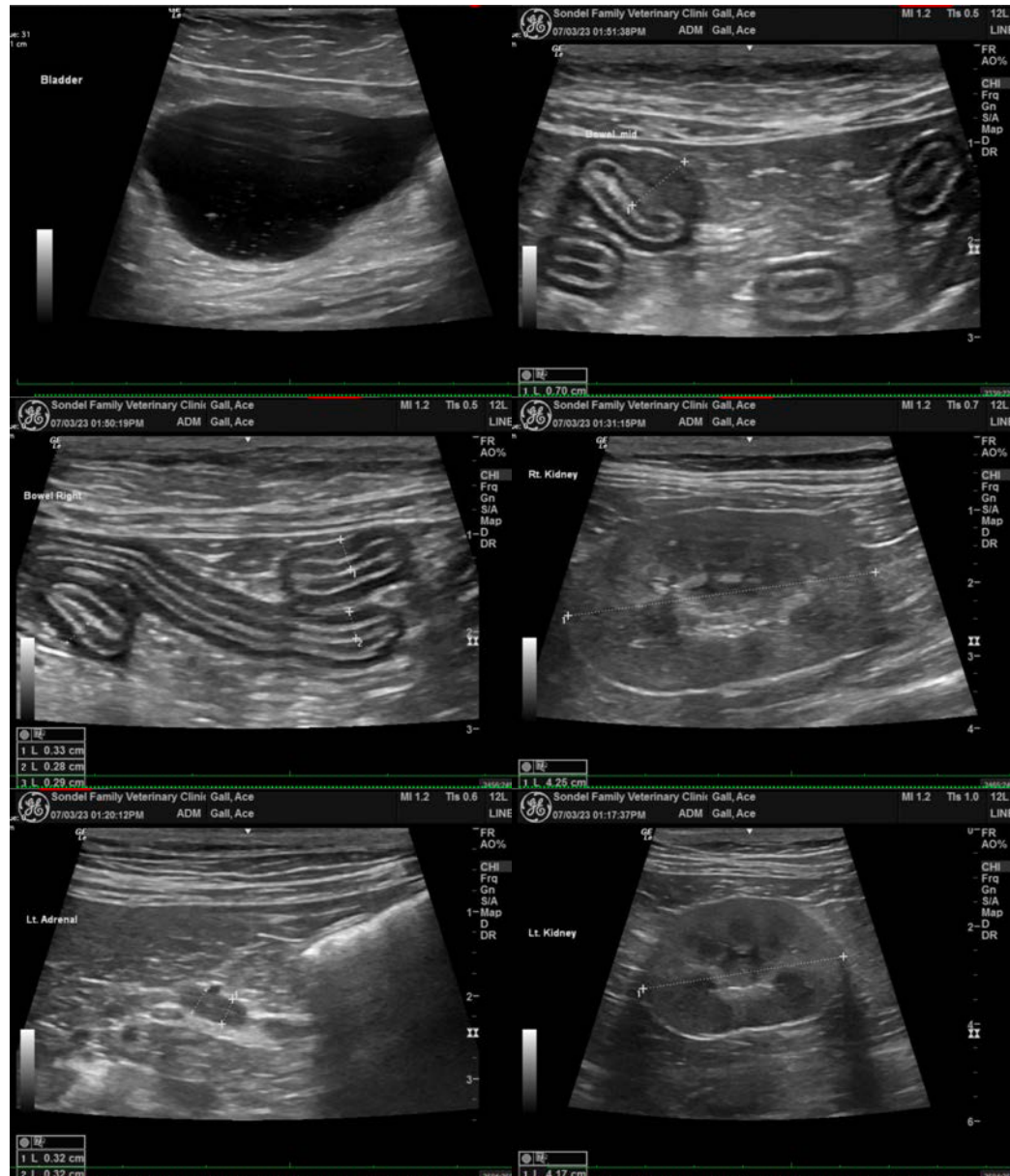Dr. Kara Wallisch

**INVOICE**

43719

**DATE**

7/3/23



The information and recommendations provided are based on the images presented by the referring veterinarian/sonographer. No evaluation can be communicated regarding pathology that was not visible in the image/video clips provided.

Thank you for this referral. If the clinical or image interpretation does not parallel your findings or if I can be of any further assistance please contact me.

**Beth Johnson, DVM, DACVIM**  
info@sonopath.com