**DATE**

7/29/22

PRESENTING CLINICAL SIGNS

William is 15 y/o MN Chihuahua who presents for vomiting, lethargy, bloody diarrhea - dx about 1.5 years ago - off insulin for 3 days - received BG curve yesterday, insulin changed from 1 U am 2 U pm to 1 U AM - two previous seizures, no medications started Medications: - Novalin 1 U AM

PATIENT

William Kazlow

Current Medications: None listed.

Lab Results: See attached.

Date of Previous IntraPet Ultrasound: No previous.

Sedation: Not required to complete full diagnostic ultrasound.

Stat Report: Not requested.

Imaging Performed By: Rachel Brillhart, RDMS.

SPECIES

Canine

BREED

Chihuahua

ULTRASONOGRAPHIC EXAMINATION OF THE ABDOMEN**Urinary System**

Urinary bladder is adequately distended with anechoic contents. No masses, inflammatory changes, echogenic sediment or cystoliths are observed. The urinary bladder, trigone and visible pelvic urethra are normal in thickness with a smooth mucosal surface.

SEX

Neutered male

The prostate is mildly enlarged and measured 2.0 cm wide. The parenchyma is diffusely heterogenous and mildly hyperechoic to the surrounding tissue. Normal distinct margins and symmetrical bilobed shape are maintained. Multi-focal, mineral foci are noted. This finding may be a normal patient variant/age related change; however, prostatitis or less likely infiltrative neoplasia cannot be ruled out. This finding should be interpreted in combination with clinical signs, urinalysis results, etc. and further investigated or monitored as indicated based on those results.

AGE

7/29/07

WEIGHT

8.9 lbs

Kidneys are overall normal in size and shape with smooth peripheral margination. A normal 1:3 cortex to medulla ratio is maintained. The medulla and cortices are uniform in texture with some mild increased cortical echogenicity and mild loss of corticomedullary distinction, expected in this age patient. There is no evidence of pyelectasia or infarcts observed. A hyperechoic band parallel to the corticomedullary border is present bilaterally. Non-obstructive areas of mineralization/nephroliths are noted. The left kidney measured 4.29 cm. The right kidney measured 4.44 cm.

INTERPRETED BYBeth Johnson, DVM
DACVIM**Adrenal Glands**

Adrenal glands are largely normal in size, shape and contour. Some parenchymal heterogeneity is present without concerning capsular distortion. These changes are likely normal for this age but should be monitored if there is any suspicion of adrenal disease. The left adrenal gland measured 1.72 cm long, 0.74 cm at the cranial pole and 0.74 cm at the caudal pole. The right adrenal gland measures 1.78 cm long, 1.09 cm at the cranial pole and 0.67 cm at the caudal pole.

HOSPITAL NAMEAnimal Emergency
Hospital**REFERRING VET**

Dr. Thompson

Spleen

Spleen is subjectively normal in size with a normal smooth capsular contour. Parenchyma is appropriately finely textured and homogenous with normal echogenicity relative to surrounding tissue (hyperechoic to liver). No focal nodules or masses are observed. Splenic vasculature appears normal.

INVOICE

32072

Liver

Liver is subjectively enlarged (swollen contour) without disruption of architecture. It has a normal homogenous echotexture. Parenchyma is diffusely hyperechoic characterized by less prominent than normal portal vein walls and increased echogenicity relative to the spleen and falciform fat. No focal lesions are observed. Visible vasculature and biliary tree appear normal without distension or congestion. In the mid

liver a liver lobe appears exceptionally rounded like an emerging mass may be developing or present measuring 3.0 x 4.0 cm in size. The mass is homogenous and isoechoic in appearance.

Gallbladder is moderately distended with anechoic bile as well as suspended and gravity dependent echogenic debris. The wall is smooth without visible thickening. There is no evidence of cystic or CBD dilation. There is no evidence of effusion or inflammation.

Gastrointestinal

The visible stomach wall is normal in thickness and layering. The lumen of the stomach is moderately fluid distended with some ingesta present and there is a focal area of the gastric wall that measures 1.0 x 1.5 cm in size and appears to contain a hypoechoic to anechoic lesion/nodule/mass. The lesion does not appear vascular. Pyloric outflow tract appears patent.

The visible small intestines are normal in wall thickness and layering. Small intestinal motility appears adequate (1-3 contractions per min). The lumen of the small intestine is empty with no evidence of obstruction, foreign material or infiltrative disease.

The visible colon is diffusely thick with normal intact layering. Contents are consistent with normal formed feces and gas.

Pancreas

The observed pancreas is prominent (enlarged) in size, hypoechoic to surrounding tissue and irregular in shape with a swollen undulating contour. Enhanced hyperechoic ill-defined surrounding fat is noted.

Free Abdomen

There is no evidence of free peritoneal effusion noted in these images.

There is no apparent lymphadenopathy noted in these images.

ULTRASONOGRAPHIC FINDINGS

Primary Findings

- Mild to moderate acute pancreatitis suspected.
- Focal, hypoechoic to anechoic gastric wall thickening. Differentials for which include edema secondary to pancreatitis versus infiltrative inflammatory or even neoplastic disease cannot be ruled out.
- Thick colonic wall, suggestive of colitis especially given the patient's reported hemorrhagic diarrhea. Benign infiltrative inflammatory, infectious, possibly parasitic, etc. disease is considered most likely. Infiltrative neoplasia cannot be ruled out, but is considered less likely.
- Hyperechoic hepatomegaly with possible emerging mass. Rule outs for which include both benign hepatoma, adenoma, nodular hyperplasia, etc. as well as a well differentiated primary hepatic neoplasia such as hepatocellular carcinoma.
- Mild prostatomegaly with mineralization. This is most consistent with normal patient variant, age related change or chronic prostatitis. However, infiltrative neoplasia cannot be definitively ruled out.

Secondary Findings

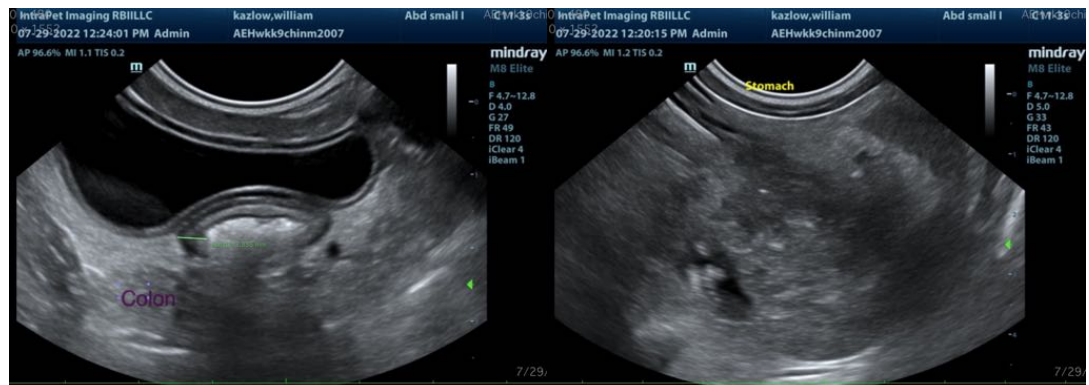- Age related renal change with bilateral, non-obstructive nephrolithiasis.
- Age related adrenal changes.
- Cholecystic debris is of unknown clinical significance. It can be seen with biliary stasis from fasting or illness. Cholecystic debris is not necessarily related to hepatobiliary disease. Echogenic bile is most commonly an incidental finding in dogs and should be interpreted in combination with clinical signs such as nausea, inappetence, cranial abdominal discomfort and/or laboratory changes such as increased ALP and/or increased Tbili.

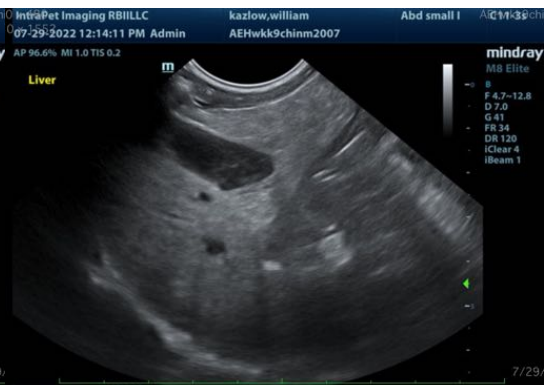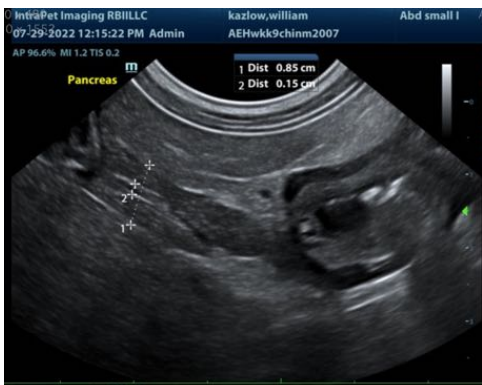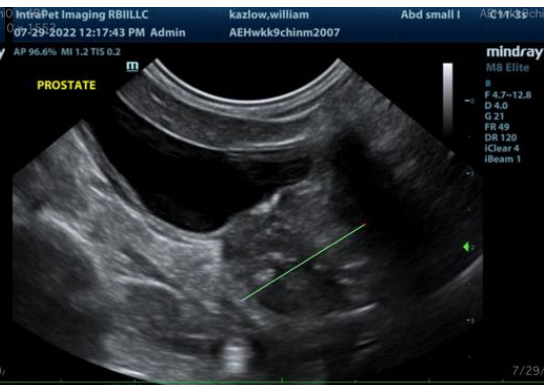
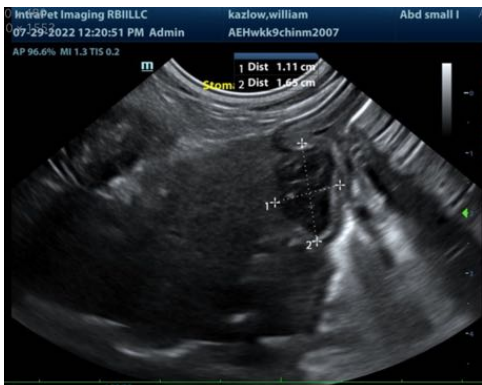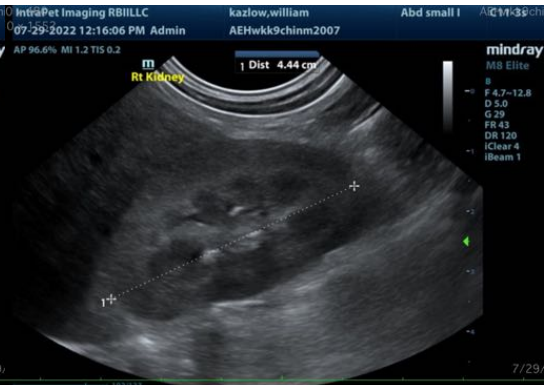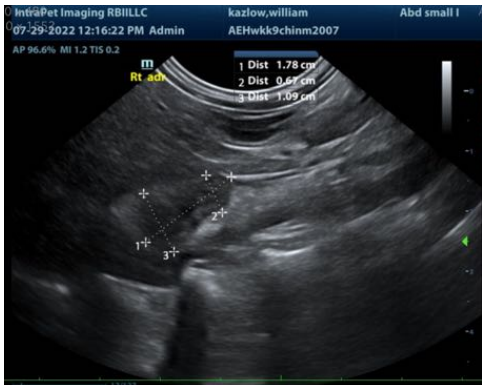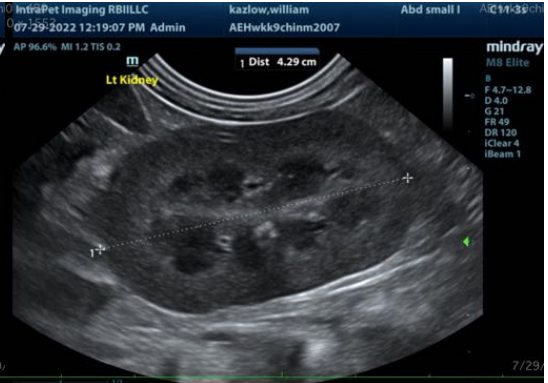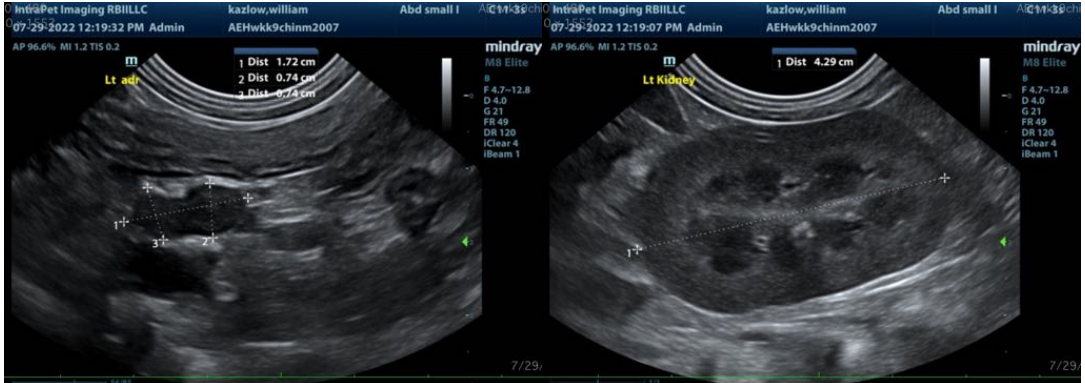
INTERPRETATION OF THE FINDINGS & FURTHER RECOMMENDATIONS

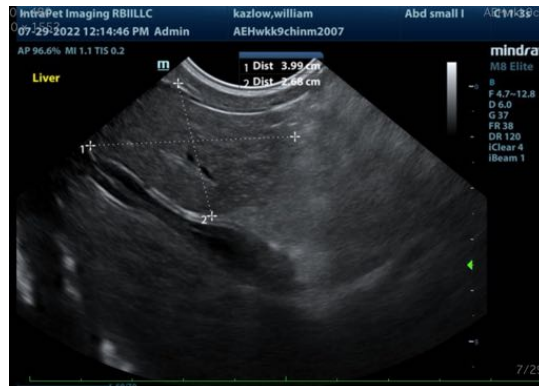Given the multitude of changes in this patient recommendations include medical management of the acute pancreatitis, gastroenteritis and reported DKA with fluid support, symptomatic support of gastrointestinal signs, frequent short acting insulin based on blood sugars and ketone status until ketones have resolved, at which time a longer acting insulin can be reinitiated, broad spectrum antibiotics, pain management if necessary, appetite stimulants, nutritional support as indicated, etc. followed by reassessment of the reported gastric lesion, thickened colon, etc. at that time. If the lesions persist and/or progress tissue sampling in the form of a FNA of the gastric lesion and/or biopsies from the stomach to the colon can be considered if the patient's coagulation status is appropriate. At that time a FNA of the emerging liver mass is also recommended.

In the meantime, if not recently evaluated:

- Urinalysis and, if indicated based on urinalysis results, urine culture are recommended. If protein is present in an otherwise quiet sediment, protein quantification with a urine protein to creatinine ration is recommended.
- A gastrointestinal malabsorption panel (including cobalamin, folate, TLI and PLI) to Texas A&M GI Laboratory is recommended for further evaluation of GI and pancreatic function.







The information and recommendations provided are based on the images presented by the referring veterinarian. No evaluation can be communicated regarding pathology that was not visible in the image/video clips provided.

Thank you for this referral. If the clinical or image interpretation does not parallel your findings or if I can be of any further assistance please contact me.

Beth Johnson, DVM DACVIM
Beth.Johnson@SonoPath.com