

**DATE**

7/29/22

**PRESENTING CLINICAL SIGNS**

History: Continual elevated liver enzymes.

**PATIENT**

Reese Hartman

Current Medications: Denamarin.

Lab Results: 7/20 - ALB 3.4, ALKP 99, ALT 224 H, GGT 5, TBIL 1.2

6/16 - ALB 3.2, ALKP PHOS 150, ALT 195, GGT 9.0, TBIL 0.3

Date of Previous IntraPet Ultrasound: No previous.

**SPECIES**

Canine

Sedation: Torbugesic and Midazolam IV.

Stat Report: Not requested.

Imaging Performed By: Stephanie Warga RDCS, RVT.

**BREED**

Weineraner

**ULTRASONOGRAPHIC EXAMINATION OF THE ABDOMEN****SEX**

Neutered Male

**Urinary System**

Urinary bladder is adequately distended with anechoic contents. No masses, inflammatory changes, echogenic sediment or cystoliths are observed. The urinary bladder, trigone and visible pelvic urethra are normal in thickness with a smooth mucosal surface.

**AGE**

3/16/12

The area of the residual prostate is examined without evident pathology.

**WEIGHT**

115 Pounds

Left kidney is normal is size (8.21 cm), shape and echogenicity. It has smooth peripheral margination. There is a normal 1:3 cortex to medulla ratio with appropriate corticomedullary distinction. There is no evidence of pyelectasia, mineral or infarcts observed.

Right kidney is normal is size (8.96 cm), shape and echogenicity. It has smooth peripheral margination. There is a normal 1:3 cortex to medulla ratio with appropriate corticomedullary distinction. There is no evidence of pyelectasia, mineral or infarcts observed.

**INTERPRETED BY**Beth Johnson, DVM  
DACVIM**Adrenal Glands**

Left adrenal gland is normal in size (2.93 cm long x 0.89 cm at cranial pole and 0.88 cm at caudal pole), shape and overall architecture, echogenicity and echotexture. Visible surrounding vasculature appears normal.

Right adrenal gland is normal in size (3.38 cm long x 0.81 cm at cranial pole and 0.9 cm at caudal pole), shape and overall architecture, echogenicity and echotexture. Visible surrounding vasculature appears normal.

**HOSPITAL NAME**

Banfield Abingdon

**Spleen****REFERRING VET**

Dr. Simpson

Spleen is subjectively normal in size with a normal smooth capsular contour. Parenchyma is appropriately finely textured and homogenous with normal echogenicity relative to surrounding tissue (hyperechoic to liver). Multifocal well-demarcated hyperechoic homogenous nodules are noted. Splenic vasculature appears normal. A 1.0 cm hyperechoic nodule is noted in the mid spleen that does not disrupt the capsule.

**INVOICE**

16607

**Liver**

Liver is subjectively normal in size with normal smooth curvilinear peripheral contour. Parenchyma is appropriately hypoechoic to the spleen in echogenicity and appropriately mildly coarse and homogenous in echotexture. A 2.0 cm discreet hyperechoic nodule is noted in the left liver, as well as an emerging mass like lesion (5.0 cm x 10.0 cm) in the deep right liver that is vascular in appearance, homogeneous and iso- to hypoechoic. Visible vasculature and biliary tree appear normal without distension or congestion.

Gallbladder is non-distended in size. The wall is smooth without visible thickening. Luminal contents are primarily anechoic. There is no evidence of cystic or common bile duct dilation.

### ***Gastrointestinal***

The visible stomach wall is normal in thickness and layering. The lumen of the stomach is mildly distended with echogenic non-shadowing luminal contents and gas consistent with normal ingesta. There is no evidence of obstruction, foreign material or infiltrative disease. Pyloric outflow tract appears patent.

The visible small intestines are normal in wall thickness and layering. Small intestinal motility appears adequate (1-3 contractions per min). The lumen of the small intestine is empty with no evidence of obstruction, foreign material or infiltrative disease.

The visible colon is normal in wall thickness and layering. Contents are consistent with normal formed feces and gas.

### ***Pancreas***

The observed pancreas appears appropriately isoechoic to surrounding omental fat. Visible capsule is smooth and normal in contour. Visible pancreatic parenchyma is homogenous and unremarkable. There is no visible pancreatic duct dilation. There is no evidence of active peripancreatic inflammation.

### ***Free Abdomen***

There is no evidence of peritoneal effusion. There is no apparent lymphadenopathy.

## **ULTRASONOGRAPHIC FINDINGS**

### **Primary Findings**

- An emerging liver mass, differentials for which include both benign lesion, such as hepatoma or adenoma, as well as vacuolar hepatopathy nodular hyperplasia, etc. versus a well differentiated primary hepatocellular carcinoma. Differentials for the hyperechoic liver nodule are similar with weight being given to nodular hyperplasia for the hyperechoic nodule.

### **Secondary Findings**

- Hyperechoic splenic nodules – most consistent with benign myelolipomas. Other differentials such as fibrosis or calcification caused by old hematomas or infarcts, chronic inflammation, granulomatous disease or metastatic disease cannot be ruled out, but are considered less likely.
- Hypo to anechoic splenic nodule – likely represents a benign lesion such as a cyst, hematoma, nodular hyperplasia, extramedullary hematopoiesis, etc., however while considered less likely, infiltrative neoplasia can mimic benign lesions, and cannot be ruled out.

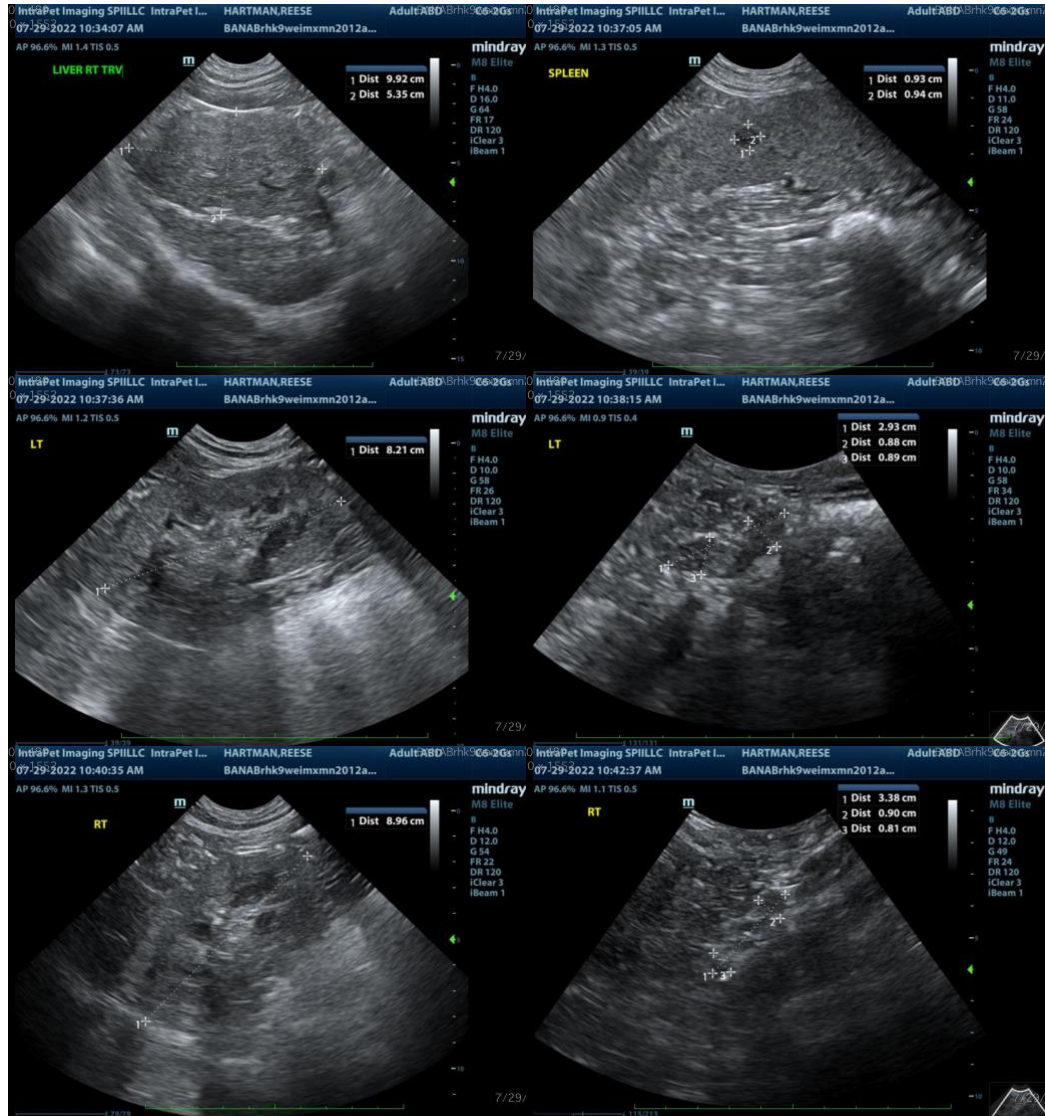
## **INTERPRETATION OF THE FINDINGS & FURTHER RECOMMENDATIONS**

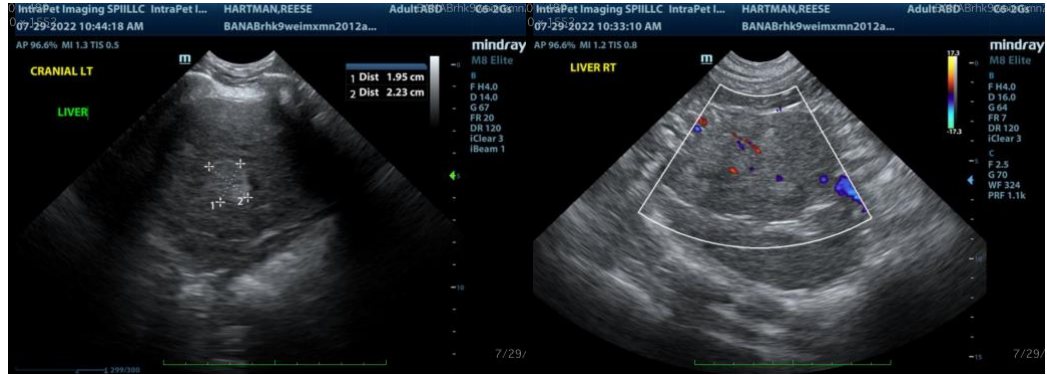
Recommendations for this patient:

Three view thoracic radiographs are recommended for further assessment of cardio-pulmonary status as well as to further evaluate for any evidence of metastatic disease, if not recently evaluated.

A fine needle aspirate of the deep right liver mass is recommended, if patients coagulation status is appropriate.

In the meantime, given the progressively increased liver enzymes, empirical therapy with broad spectrum antibiotics, as well as hepatic nutraceuticals could be considered.





The information and recommendations provided are based on the images presented by the referring veterinarian. No evaluation can be communicated regarding pathology that was not visible in the image/video clips provided.

Thank you for this referral. If the clinical or image interpretation does not parallel your findings or if I can be of any further assistance please contact me.

**Beth Johnson, DVM DACVIM**  
Beth.Johnson@SonoPath.com