



PATIENT PRESENTING CLINICAL SIGNS

Lady Ruh Presented on Tues for not eating for 4 days. Small bowel diarrhea and vomiting. Sr profile submitted and pet was treated symptomatically. Pet stopped vomiting but still not eating 2 days later. A path review of the CBC did not diagnose lymphocytic leukemia.

SPECIES Abnormal PE/Chem/CBC/UA Results: **Canine** Cranial abdomen is firm on palpation. Abdominal mass confirmed on abdominal radiographs. Pet is QAR. 2 pound weight loss. Not clinically icteric. BCS 4/9. No teeth, mature cataracts. Has otherwise been a healthy dog most of her life.

BREED ULTRASONOGRAPHIC EXAMINATION OF THE ABDOMEN

Papillon *Urinary System*

The urinary bladder is moderately distended with anechoic contents. No masses, inflammatory changes, echogenic sediment or cystoliths are observed. The urinary bladder, trigone and visible pelvic urethra are normal in thickness with a smooth mucosal surface.

SEX

Spayed Female

The right kidney is normal in size (4.2 cm), shape and echogenicity. It has smooth peripheral margination. There is a normal 1:3 cortex to medulla ratio with appropriate corticomedullary distinction. There is no evidence of pyelectasia, mineral or infarcts observed.

AGE

15 Years

The left kidney is normal in size (3.8 cm), shape and echogenicity. It has smooth peripheral margination. There is a normal 1:3 cortex to medulla ratio with appropriate corticomedullary distinction. There is no evidence of pyelectasia, mineral or infarcts observed.

WEIGHT

9.8 Pounds

Adrenal Glands

The adrenal glands are unable to be well visualized in these images.

INTERPRETED BY

Beth Johnson, DVM
DACVIM

Spleen

In the mid left abdomen, in the area of the spleen, there is a large 6.0 cm x 8.0 cm mixed heterogeneous, primarily solid mass that appears to be in the area of the spleen. However, normal spleen cannot be well visualized, and definitive tissue origin cannot be determined, with a caudal liver mass also being a possible differential.

IMAGING PERFORMED BY

Dr. Laurel Logas

Liver

Aside from the possibility of a caudal liver mass, the liver is subjectively enlarged with mildly irregular margins. Parenchyma is heterogenous characterized by multiple poorly defined hypoechoic nodules within otherwise hyperechoic liver parenchyma. Visible vasculature and biliary tree appear normal without distension or congestion.

HOSPITAL NAME

Bradentown VH

The gallbladder is unable to be well visualized in these images.

REFERRING VET

Dr. Laurel Logas

Gastrointestinal

The visible stomach wall is normal in thickness and layering. The lumen of the stomach is mildly distended with echogenic non-shadowing luminal contents and gas consistent with normal ingesta. There is no evidence of obstruction, foreign material or infiltrative disease. Pyloric outflow tract appears patent.

INVOICE

39949

The visible small intestines are normal in wall thickness and layering (canine duodenum < 0.5 cm and feline duodenum < 0.4 cm; other < 0.3 cm). Small intestinal motility appears adequate (1-3 contractions per min). The lumen of the small intestine is empty with no evidence of obstruction, foreign material or infiltrative disease.

DATE

7/29/22



PATIENT

Lady Ruh

The visible colon is normal in wall thickness (< 0.2 cm) and layering. Contents are consistent with normal formed feces and gas.

Pancreas

SPECIES

Canine

The pancreatic parenchyma is appropriately isoechoic to surrounding tissue. Visible capsule is smooth and normal in contour. There is no visible pancreatic duct dilation. There is no evidence of active peripancreatic inflammation.

BREED

Papillon

Free Abdomen

There is a moderate amount of anechoic free fluid in the cranial abdomen around the mass, as well as hypo- to anechoic round structures consistent with lymph nodes .

SEX

Spayed Female

ULTRASONOGRAPHIC FINDINGS

AGE

15 Years

- **Cranial mid abdominal mass** – presumably associated with the spleen. However, definitive tissue origin cannot be determined based on these images. Other differentials include caudal liver mass, or even bowel, omentum or lymph node origin. Top differential for the mass is infiltrative neoplasia.
- **Surrounding lymphadenopathy** – concerning for infiltrative neoplasia.
- **Free fluid** – rule out hemorrhage versus other.
- **Heterogenous Liver** – These changes are most consistent with benign processes such as nodular hyperplasia, steroid (vacuolar) hepatopathy, extramedullary hematopoiesis or possibly chronic inflammatory disease and less commonly infiltrative round cell or metastatic neoplasia.

WEIGHT

9.8 Pounds

INTERPRETED BY

Beth Johnson, DVM
DACVIM

INTERPRETATION OF THE FINDINGS & FURTHER RECOMMENDATIONS

Three view thoracic radiographs are recommended for further assessment of cardio-pulmonary status as well as to further evaluate for any evidence of metastatic disease, if not recently evaluated.

IMAGING PERFORMED BY

Dr. Laurel Logas

A sample of the free abdominal fluid is recommended to look for evidence of a hemoabdomen with submission of the fluid of cytology +/- culture recommended if not a hemoabdomen.

HOSPITAL NAME

Bradentown VH

If patient's coagulation status is appropriate, a fine needle aspirate of the mass could be considered to look for evidence of round cell neoplasia. However, if a hemoabdomen is diagnosed, exploratory laparotomy for mass removal is recommended over cytology to stabilize and prevent further hemorrhage.

REFERRING VET

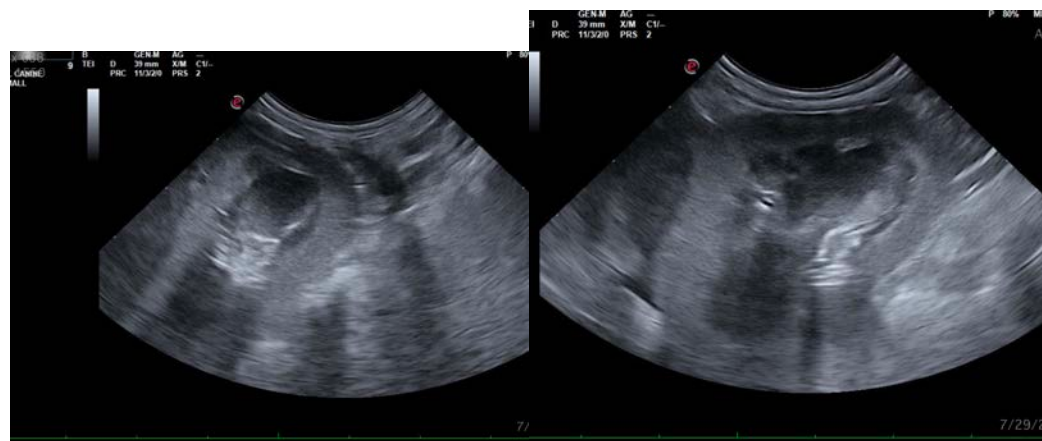Dr. Laurel Logas

INVOICE

39949

DATE

7/29/22





PATIENT

Lady Ruh

SPECIES

Canine

BREED

Papillon

SEX

Spayed Female

AGE

15 Years

WEIGHT

9.8 Pounds

INTERPRETED BY

Beth Johnson, DVM
DACVIM

IMAGING PERFORMED BY

Dr. Laurel Logas

HOSPITAL NAME

Bradentown VH

REFERRING VET

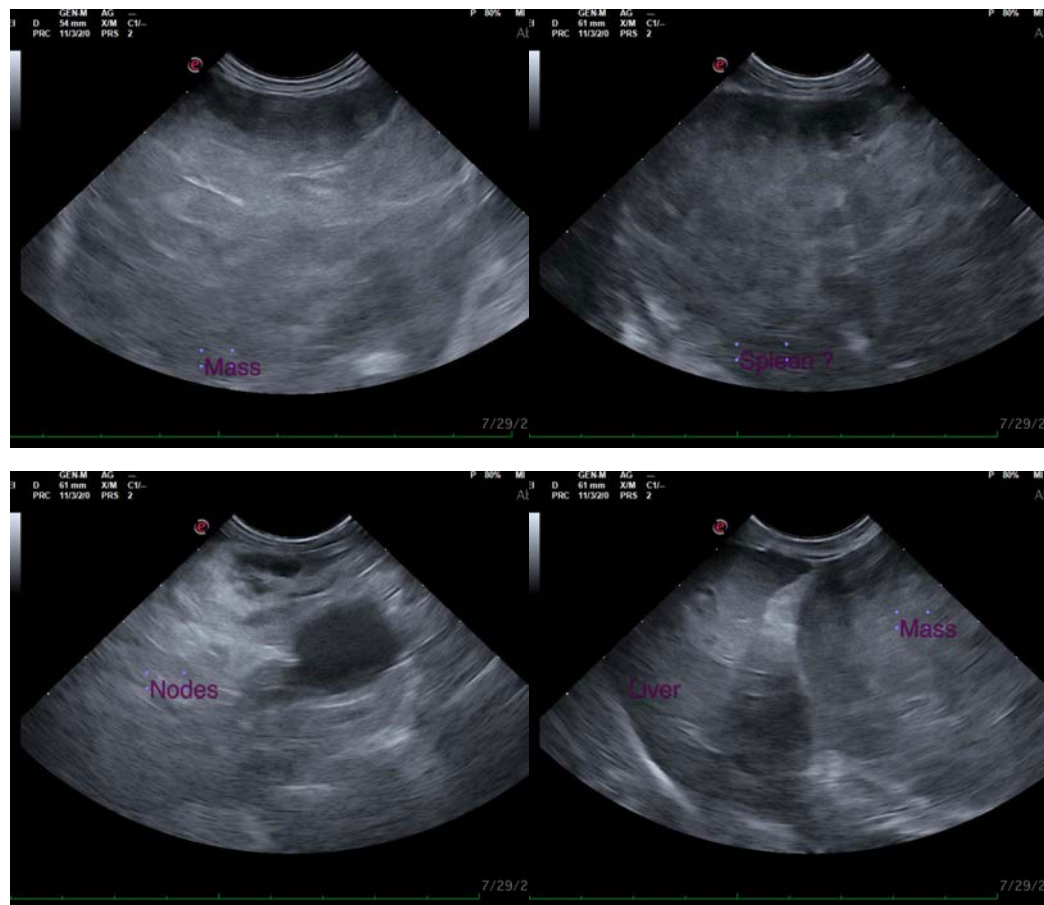
Dr. Laurel Logas

INVOICE

39949

DATE

7/29/22



The information and recommendations provided are based on the images presented by the referring veterinarian/sonographer. No evaluation can be communicated regarding pathology that was not visible in the image/video clips provided.

Thank you for this referral. If the clinical or image interpretation does not parallel your findings or if I can be of any further assistance please contact me.

Beth Johnson, DVM, DACVIM
Beth.Johnson@sonopath.com