



PATIENT

Arwin Coyle

PRESENTING CLINICAL SIGNS

History of elevated Bilirubin. AUS advised and performed
Abnormal PE/Chem/CBC/UA Results: Bilirubin 0.5 was 0.4 three weeks ago

SPECIES

Canine

ULTRASONOGRAPHIC EXAMINATION OF THE ABDOMEN

Urinary System

Urinary bladder is only mildly distended (empty). Visible contents are anechoic. Urinary bladder wall is unable to be fully assessed for pathology without further distension. No visible masses or cystoliths are observed. The trigone and visible pelvic urethra are normal thickness with a smooth mucosal surface. If there are urinary signs and/or concern for urinary bladder pathology, reassessment after complete filling is recommended.

BREED

Greyhound

SEX

Neutered Male

The prostate is unable to be visualized in these images.

AGE

9 Years

The right kidney is normal in size (6.67 cm), shape and echogenicity. It has smooth peripheral margination. There is a normal 1:3 cortex to medulla ratio with appropriate corticomedullary distinction. There is no evidence of pyelectasia or infarcts observed. Non-obstructive areas of mineralization/nephroliths are noted.

WEIGHT

90 Pounds

The left kidney is normal in size (5.29 cm), shape and echogenicity. It has smooth peripheral margination. There is a normal 1:3 cortex to medulla ratio with appropriate corticomedullary distinction. There is no evidence of pyelectasia or infarcts observed. Non-obstructive areas of mineralization/nephroliths are noted.

Adrenal Glands

INTERPRETED BY

Beth Johnson, DVM
DACVIM

The right adrenal gland is normal in size (0.52 cm at the cranial pole and 0.70 cm at the caudal pole), shape and contour. Corticomedullary structure is unremarkable. Visible surrounding vasculature appears normal.

IMAGING PERFORMED BY

Dr. Ray Caughman

The left adrenal gland is normal in size (0.59 cm at the cranial pole and 0.64 cm at the caudal pole), shape and contour. Corticomedullary structure is unremarkable. Visible surrounding vasculature appears normal.

Spleen

HOSPITAL NAME

Dogwood AH

Spleen is subjectively large in size with a mildly swollen but smooth capsule. Parenchyma is normal and homogenous in echogenicity and echotexture. No focal nodules or masses are observed. Splenic vasculature appears normal.

Liver

REFERRING VET

Dr. Ray Caughman

The liver is subjectively normal in size with normal smooth curvilinear peripheral contour. Parenchyma is appropriately hypoechoic to the spleen in echogenicity and appropriately mildly coarse and homogenous in echotexture. No focal lesions are observed. Visible vasculature and biliary tree appear normal without distension or congestion.

INVOICE

39965

The gallbladder is non-distended in size. The wall is smooth without visible thickening. Luminal contents are primarily anechoic. There is no evidence of cystic or common bile duct dilation.

DATE

7/29/22



PATIENT

Arwin Coyle

SPECIES

Canine

BREED

Greyhound

SEX

Neutered Male

AGE

9 Years

WEIGHT

90 Pounds

INTERPRETED BY

Beth Johnson, DVM
DACVIM

IMAGING PERFORMED BY

Dr. Ray Caughman

HOSPITAL NAME

Dogwood AH

REFERRING VET

Dr. Ray Caughman

INVOICE

39965

DATE

7/29/22

Gastrointestinal

The stomach wall is normal in thickness (canine < 0.5 cm and feline < 0.4 cm) and layering. The lumen of the stomach is empty with no evidence of obstruction, foreign material or infiltrative disease. Pyloric outflow tract appears patent.

The visible small intestines are normal in wall thickness and layering (canine duodenum < 0.5 cm and feline duodenum < 0.4 cm; other < 0.3 cm). Small intestinal motility appears adequate (1-3 contractions per min). The lumen of the small intestine is empty with no evidence of obstruction, foreign material or infiltrative disease.

The visible colon is normal in wall thickness (< 0.2 cm) and layering. Contents are consistent with normal formed feces and gas.

Pancreas

The pancreatic parenchyma is appropriately isoechoic to surrounding tissue. Visible capsule is smooth and normal in contour. There is no visible pancreatic duct dilation. There is no evidence of active peripancreatic inflammation.

Free Abdomen

There is no evidence of free peritoneal effusion noted in these images.

There is no apparent lymphadenopathy noted in these images.

PRIMARY FINDINGS

- **Hypersplenism** – can be associated with congestion caused by sedation (if sedated) but can also be associated with diffuse infiltrative disease. Both benign conditions such as extramedullary hematopoiesis, lymphoid hyperplasia, as well as infiltrative neoplastic diseases such as round cell neoplasia should be considered. This may be normal patient variant, given the breed.

SECONDARY FINDINGS

- Non-obstructive nephrolithiasis bilaterally

INTERPRETATION OF THE FINDINGS & FURTHER RECOMMENDATIONS

There are no ultrasonographically visible reasons to explain this patient's mildly high bilirubin. Given the minimal increase, differentials such as a hemolyzed or lipemic sample are considered likely, or this may be a normal value in this patient, given the patient breed. No further recommendations are present at this time. However, if the bilirubin continues to gradually increase, recheck imaging is recommended.



PATIENT

Arwin Coyle

SPECIES

Canine

BREED

Greyhound

SEX

Neutered Male

AGE

9 Years

WEIGHT

90 Pounds

INTERPRETED BY

Beth Johnson, DVM
DACVIM

IMAGING PERFORMED BY

Dr. Ray Caughman

HOSPITAL NAME

Dogwood AH

REFERRING VET

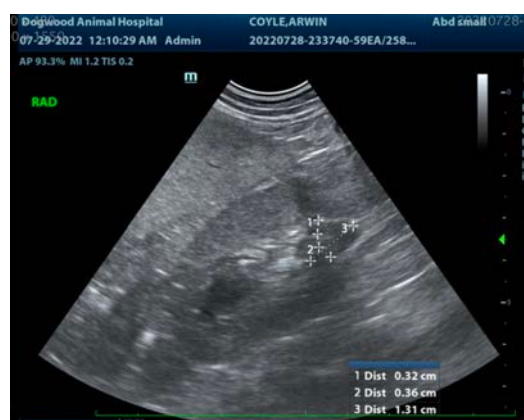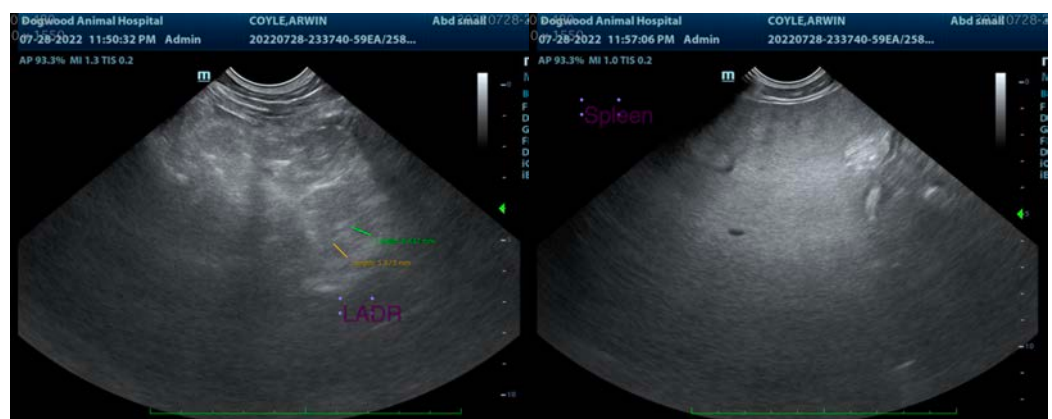
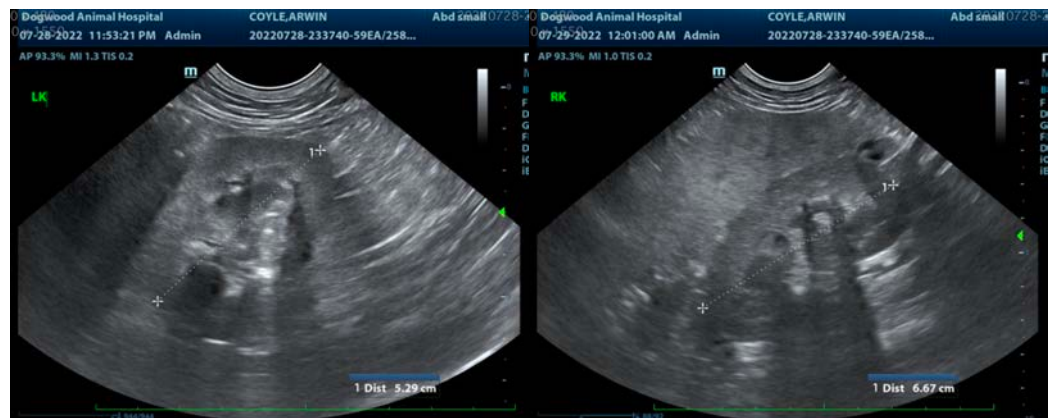
Dr. Ray Caughman

INVOICE

39965

DATE

7/29/22



The information and recommendations provided are based on the images presented by the referring veterinarian/sonographer. No evaluation can be communicated regarding pathology that was not visible in the image/video clips provided.

Thank you for this referral. If the clinical or image interpretation does not parallel your findings or if I can be of any further assistance please contact me.

Beth Johnson, DVM, DACVIM
Beth.Johnson@sonopath.com