

**DATE PRESENTING CLINICAL SIGNS**

7/28/22 Losing weight, vomiting liquid. Decreased appetite. On physical exam >10% weight loss in one year. Dehydrated. History of CRF.

PATIENT

Tonks Torbit

Current Medications: 100mL SQ Fluids once daily, Cerenia 8mg once daily, Mirtazapine 15mg 1/4 by mouth SID

Lab Results: Severe azotemia/end stage renal failure.

Date of Previous IntraPet Ultrasound: No previous.

SPECIES

Feline

Sedation: Not required to complete full diagnostic ultrasound.

Stat Report: Not requested.

BREED

DSH

ULTRASONOGRAPHIC EXAMINATION OF THE ABDOMEN**Urinary System**

The urinary bladder is moderately distended with anechoic contents. No masses, inflammatory changes, echogenic sediment or cystoliths are observed. The urinary bladder, trigone and visible pelvic urethra are normal in thickness with a smooth mucosal surface.

SEX

Intact Female

The right kidney is normal in size (4.09 cm), shape and echogenicity. It has smooth peripheral margination. There is a normal 1:3 cortex to medulla ratio with appropriate corticomedullary distinction. There is no evidence of pyelectasia, mineral or infarcts observed.

AGE

5/7/08

The left kidney is small, irregular and diffusely echogenic with decreased corticomedullary distinction and poor visualization of internal architecture. There is no pyelectasia noted. Non-obstructive areas of mineralization/nephroliths are noted. The left kidney measures 2.7 cm.

WEIGHT

6.6 Pounds

Adrenal Glands**INTERPRETED BY**Beth Johnson, DVM
DACVIM

The right adrenal gland is normal in size (0.59 cm), shape and contour. Corticomedullary structure is unremarkable. Visible surrounding vasculature appears normal.

The left adrenal gland is normal in size (0.48 cm), shape and contour. Corticomedullary structure is unremarkable. Visible surrounding vasculature appears normal.

IMAGING PERFORMED BY

Andi Parkinson RDMS

Spleen

The spleen is subjectively normal in size with a normal smooth capsular contour. Parenchyma is appropriately finely textured and homogenous with normal echogenicity relative to surrounding tissue (hyperechoic to liver). No focal nodules or masses are observed. Splenic vasculature appears normal.

HOSPITAL NAME

Abbey AH

Liver

The liver is subjectively normal in size with normal smooth curvilinear peripheral contour. Parenchyma is appropriately hypoechoic to the spleen in echogenicity and appropriately mildly coarse and homogenous in echotexture. No focal lesions are observed. Visible vasculature and biliary tree appear normal without distension or congestion.

REFERRING VET

Dr. Kluttz

INVOICE

39944

The gallbladder is non-distended in size. The wall is smooth without visible thickening. Luminal contents are primarily anechoic. There is no evidence of cystic or common bile duct dilation.

Gastrointestinal

The stomach wall is normal in thickness (canine < 0.5 cm and feline < 0.4 cm) and layering. The lumen of the stomach is empty with no evidence of obstruction, foreign material or infiltrative disease. Pyloric outflow tract appears patent.

The visible small intestine demonstrates areas of thick muscularis layer relative to mucosa (disruption of the normal 1:3 muscularis:mucosa ratio). Small intestinal submucosa is slightly irregular, thick and hyperechoic, without evident loss of layering appreciated. The lumen is empty with no evidence of obstruction or foreign material. In the mid abdomen, adjacent to enlarged mesenteric lymph nodes, there are some bowel loops with suspected early emerging loss of layering.

The visible colon is normal in wall thickness (< 0.2 cm) and layering. Contents are consistent with normal formed feces and gas.

Pancreas

The observed pancreas appears appropriately isoechoic to surrounding omental fat. The capsule is mildly irregular in shape. Parenchyma is mildly heterogenous and coarse. There is no visible pancreatic duct dilation. There is no evidence of active peripancreatic inflammation.

Free Abdomen

There is no evidence of free peritoneal effusion noted in these images.

Prominent, hypoechoic mesenteric lymph nodes are noted. Both reactive lymph nodes as well as infiltrative neoplasia are considered differentials.

ULTRASONOGRAPHIC FINDINGS

- **Gastrointestinal lymphoma (suspect) pattern** – Thick muscularis has been reported with infiltrative bowel disease including both benign inflammatory disease as well as infiltrative neoplasia such as lymphoma. Given the suspected early or emerging loss of layering, infiltrative neoplasia is considered more likely, but benign IBD cannot be ruled out without tissue sampling.
- **Mesenteric lymphadenopathy** – Reactive as well as infiltrative neoplasia are considered differentials.
- **Pancreatic age-related remodeling** – Mild irregularities are consistent with benign age-related change. Low-grade smoldering chronic pancreatitis cannot be ruled out and should be suspected in the face of appropriate clinical signs.
- **Chronic Kidney Disease with small left kidney and compensatory hypertrophy of the right kidney** – This appearance of the kidneys is consistent with chronic kidney disease such as chronic glomerular or interstitial nephritis, chronic pyelonephritis, etc.

INTERPRETATION OF THE FINDINGS & FURTHER RECOMMENDATIONS

Urinalysis and, if indicated based on urinalysis results, urine culture are recommended. If protein is present in an otherwise quiet sediment, protein quantification with a urine protein to creatinine ration is recommended.

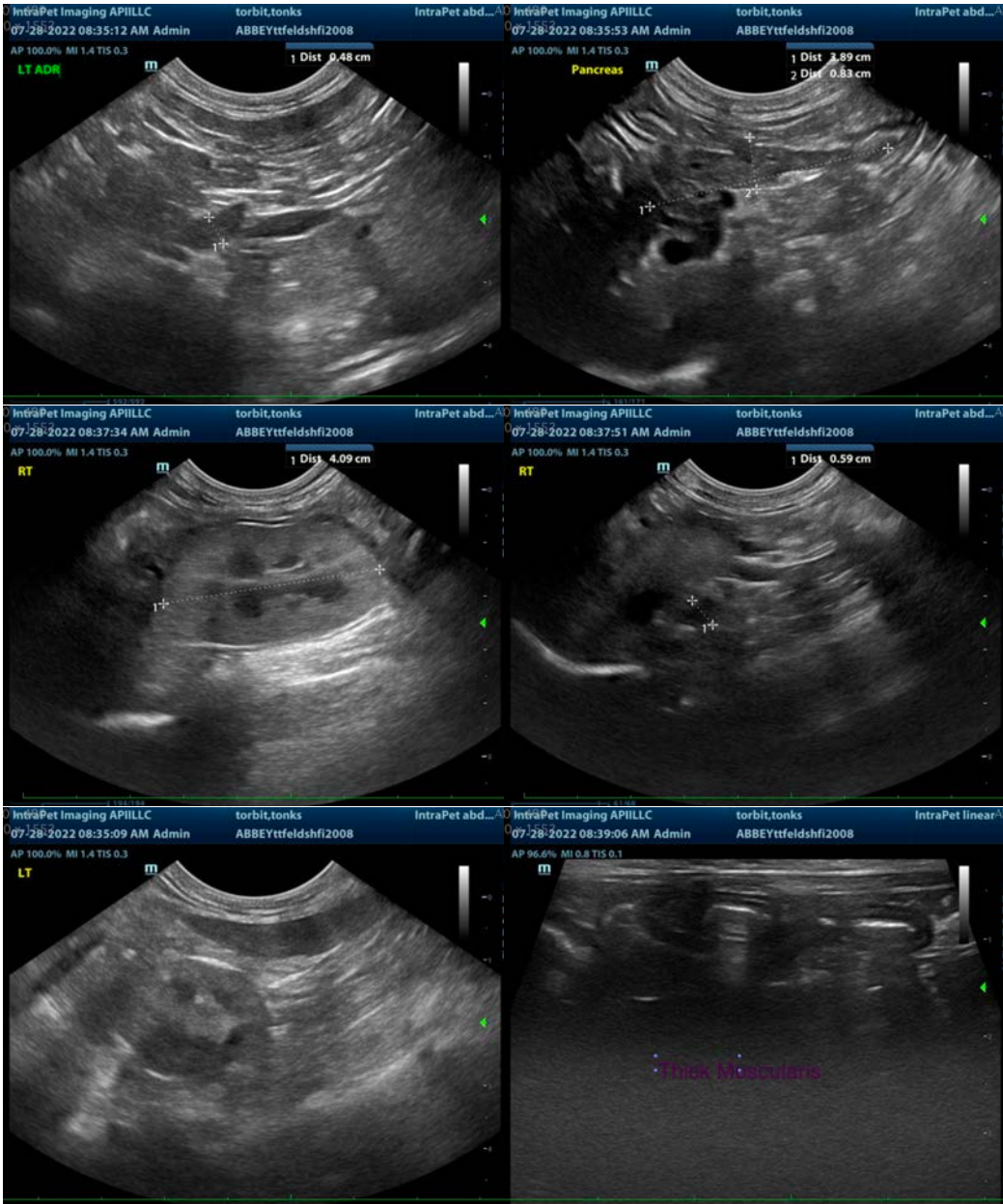
Blood pressure is recommended if not recently evaluated, given the azotemia and suspect kidney disease.

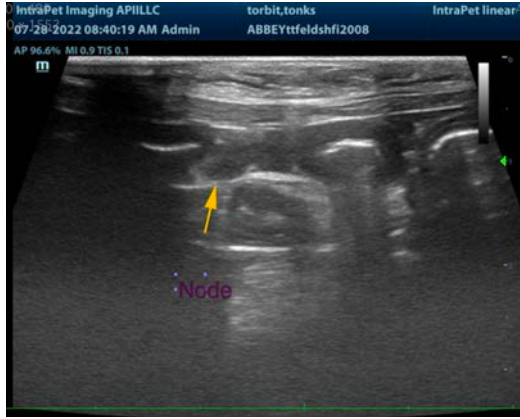
A gastrointestinal malabsorption panel (including cobalamin, folate, TLI and PLI) to Texas A&M GI Laboratory is recommended for further evaluation of GI and pancreatic function.

Ideally, biopsies of the GI tract, being sure to include ileum, if possible, are recommended to definitively diagnose and therefore manage the infiltrative bowel disease.

Given this patient's marked azotemia, however, supportive medical management of suspected acute on chronic kidney disease is recommended prior to considering anesthesia or anything that might further insult the kidneys.

In the meantime, therapeutic recommendations include diuresis for rehydration and management of the acute on chronic crisis, symptomatic support of gastrointestinal signs with antiemetics, gastroprotectants, appetite stimulants, etc., broad-spectrum antibiotics, as well as supportive therapeutic considerations for the diarrhea that could include fiber supplementation and/or a probiotic until the patient is stable and further evaluation of the gastrointestinal disease can be pursued.





The information and recommendations provided are based on the images presented by the referring veterinarian/sonographer. No evaluation can be communicated regarding pathology that was not visible in the image/video clips provided.

Thank you for this referral. If the clinical or image interpretation does not parallel your findings or if I can be of any further assistance please contact me.

Beth Johnson, DVM, DACVIM
Beth.Johnson@sonopath.com