



PATIENT PRESENTING CLINICAL SIGNS

Penny Johnson

SPECIES

Canine

BREED

Labradoodle

SEX

Spayed Female

AGE

2 Years

WEIGHT

27.6 Pounds

Intermittent episodes of vomiting +/- diarrhea +/- inappetence IBD test thru Antech in March 2021 was negative for IBD Resting Cortisol was 3.0 on 06/14/2022 Last fecal (on 06/14/2022) was negative for GI Ova/Parasites and Negative on the Giardia ELISA. She's had 4 fecals in the last 15 months that have all been negative for GI Ova/Parasites and Negative on the Giardia ELISA Bloodwork to include WBC, Hct, ALT, Alk Phos, BUN, Cr, Glu, TP, was normal in March 2021 and April 2021 Eats Royal CaninHydrolyzed Protein Dry and Canned and is on Trifexis Current Medications Apoquel 5.4 mg, 1 tab by mouth bid started 07/25/22 Primary Question/Differential to Be Answered in This Exam trying to determine cause of intermittent vomiting/diarrhea/inappetence

ULTRASONOGRAPHIC EXAMINATION OF THE ABDOMEN

Urinary System

The urinary bladder is moderately distended with anechoic contents. No masses, inflammatory changes, echogenic sediment or cystoliths are observed. The urinary bladder, trigone and visible pelvic urethra are normal in thickness with a smooth mucosal surface.

The right kidney is normal in size (4.89 cm), shape and echogenicity. It has smooth peripheral margination. There is a normal 1:3 cortex to medulla ratio with appropriate corticomedullary distinction. There is no evidence of pyelectasia, mineral or infarcts observed.

The left kidney is normal in size (4.36 cm), shape and echogenicity. It has smooth peripheral margination. There is a normal 1:3 cortex to medulla ratio with appropriate corticomedullary distinction. There is no evidence of pyelectasia, mineral or infarcts observed.

Adrenal Glands

The right adrenal gland is normal in size (1.9 cm long x 1.06 cm at the cranial pole and 0.43 cm at the caudal pole), shape and contour. Corticomedullary structure is unremarkable. Visible surrounding vasculature appears normal.

The left adrenal gland is normal in size (2.26 cm long x 0.34 cm at the cranial pole and 0.37 cm at the caudal pole), shape and contour. Corticomedullary structure is unremarkable. Visible surrounding vasculature appears normal.

Spleen

The spleen is subjectively normal in size with a normal smooth capsular contour. Parenchyma is appropriately finely textured and homogenous with normal echogenicity relative to surrounding tissue (hyperechoic to liver). No focal nodules or masses are observed. Splenic vasculature appears normal.

Liver

The liver is subjectively normal in size with normal smooth curvilinear peripheral contour. Parenchyma is appropriately hypoechoic to the spleen in echogenicity and appropriately mildly coarse and homogenous in echotexture. No focal lesions are observed. Visible vasculature and biliary tree appear normal without distension or congestion.

The gallbladder is non-distended in size. The wall is smooth without visible thickening. Luminal contents are primarily anechoic. There is no evidence of cystic or common bile duct dilation.

INTERPRETED BY

Beth Johnson, DVM
DACVIM

IMAGING PERFORMED BY

Jenna Walsh, CVT

HOSPITAL NAME

VCA Vitality AH

REFERRING VET

Dr. Surroz

INVOICE

39952

DATE

7/28/22



PATIENT *Gastrointestinal*

Penny Johnson The visible stomach wall is normal in thickness and layering. The lumen of the stomach is mildly distended with echogenic non-shadowing luminal contents and gas consistent with normal ingesta. There is no evidence of obstruction, foreign material or infiltrative disease. Pyloric outflow tract appears patent.

SPECIES

Canine

BREED

Labradoodle

SEX

Spayed Female

AGE

2 Years

WEIGHT

27.6 Pounds

The visible small intestines are normal in wall thickness and layering. Small intestinal motility appears adequate (1-3 contractions per min). The lumen of the small intestine is mildly distended with echogenic non-shadowing luminal contents and gas consistent with normal ingesta. There is no evidence of obstruction, foreign material or infiltrative disease.

The visible colon is normal in wall thickness (< 0.2 cm) and layering. Contents are consistent with normal formed feces and gas.

Pancreas

The pancreatic parenchyma is appropriately isoechoic to surrounding tissue. Visible capsule is smooth and normal in contour. There is no visible pancreatic duct dilation. There is no evidence of active peripancreatic inflammation.

Free Abdomen

There is no evidence of free peritoneal effusion noted in these images.

There is no apparent lymphadenopathy noted in these images.

INTERPRETED BY

Beth Johnson, DVM
DACVIM

ULTRASONOGRAPHIC FINDINGS

- Unremarkable/normal abdomen.

INTERPRETATION OF THE FINDINGS & FURTHER RECOMMENDATIONS

There are no definitive ultrasonographic explanations present for this patient's chronic intermittent gastrointestinal signs. Recommendations include:

A gastrointestinal malabsorption panel (including cobalamin, folate, TLI and PLI) to Texas A&M GI Laboratory is recommended for further evaluation of GI and pancreatic function.

A fecal enteropathogen PCR panel to Texas A&M GI Laboratory could be considered for further evaluation of possible infectious disease.

In the meantime, a diet transition to a different hydrolyzed or novel protein diet could be attempted on a trial and error basis, as some dogs respond better to one versus the other, or stop responding to one and need a new novel or hydrolyzed protein diet. A probiotic could be considered.

IMAGING PERFORMED BY

Jenna Walsh, CVT

HOSPITAL NAME

VCA Vitality AH

REFERRING VET

Dr. Surroz

INVOICE

39952

DATE

7/28/22



PATIENT

Penny Johnson

SPECIES

Canine

BREED

Labradoodle

SEX

Spayed Female

AGE

2 Years

WEIGHT

27.6 Pounds

INTERPRETED BY

Beth Johnson, DVM
DACVIM

IMAGING PERFORMED BY

Jenna Walsh, CVT

HOSPITAL NAME

VCA Vitality AH

REFERRING VET

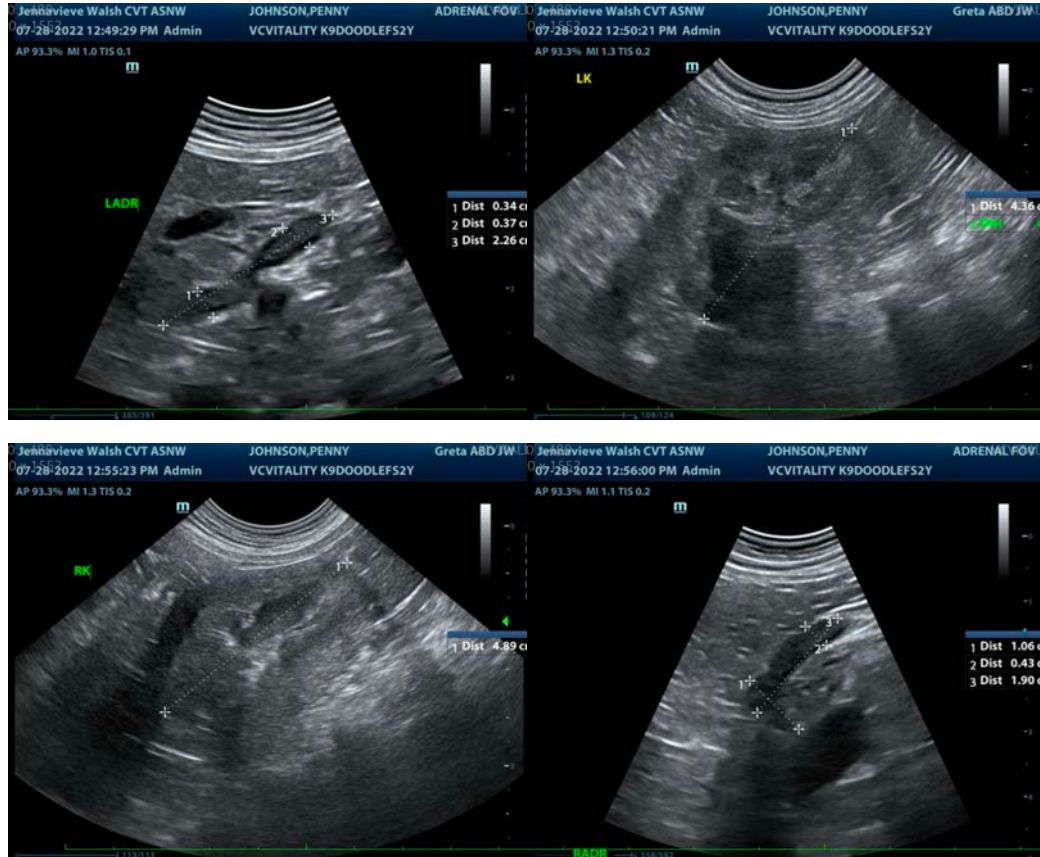
Dr. Surroz

INVOICE

39952

DATE

7/28/22



The information and recommendations provided are based on the images presented by the referring veterinarian/sonographer. No evaluation can be communicated regarding pathology that was not visible in the image/video clips provided.

Thank you for this referral. If the clinical or image interpretation does not parallel your findings or if I can be of any further assistance please contact me.

Beth Johnson, DVM, DACVIM
Beth.Johnson@sonopath.com