

IMAGING PERFORMED BY

IntraPet.com



SonoPath

Clinical Sonography & Telecytology

EDUCATIONAL TELECONSULTATION SERVICES™

1-800-838-4268 info@sonopath.com SonoPath.com

DATE PRESENTING CLINICAL SIGNS

7/28/22 Intermittent inappetence, shaking, lethargic.

PATIENT Current Medications: Gabapentin 50mg q8-12 hrs since 6/30.
Lab Results: See attached.

Alvin Ward-Dyer Date of Previous IntraPet Ultrasound: No previous.
Sedation: Not required to complete full diagnostic ultrasound.
Stat Report: Not requested.

SPECIES

Canine

BREED

Maltese

SEX

Neutered Male

AGE

4/26/09

WEIGHT

7 Pounds

INTERPRETED BY

Beth Johnson, DVM
DACVIM

IMAGING PERFORMED BY

Rachel Brilhart RDMS

HOSPITAL NAME

Bay Country VH

REFERRING VET

Dr. McLean

INVOICE

39940

ULTRASONOGRAPHIC EXAMINATION OF THE ABDOMEN

Urinary System

The urinary bladder is moderately distended with anechoic contents. No masses, inflammatory changes, echogenic sediment or cystoliths are observed. The urinary bladder, trigone and visible pelvic urethra are normal in thickness with a smooth mucosal surface.

Prostate is normal in size, echotexture and echogenicity for a neutered male.

Kidneys are overall normal in size and shape with smooth peripheral margination. A normal 1:3 cortex to medulla ratio is maintained. The medulla and cortices are uniform in texture with some mild increased cortical echogenicity and mild loss of corticomedullary distinction, expected in this age patient. There is no evidence of pyelectasia or infarcts observed. Non-obstructive areas of mineralization/nephroliths are noted. The left kidney measured 3.19 cm. The right kidney measured 2.88 cm.

Adrenal Glands

The right adrenal gland is normal in size (1.22 cm long x 0.45 cm at the cranial pole and 0.39 cm at the caudal pole), shape and contour. Corticomedullary structure is unremarkable. Visible surrounding vasculature appears normal.

The left adrenal gland is normal in size (1.45 cm long x 0.51 cm at the cranial pole and 0.54 cm at the caudal pole), shape and contour. Corticomedullary structure is unremarkable. Visible surrounding vasculature appears normal.

Spleen

Spleen is subjectively normal in size with a normal smooth capsular contour. Parenchyma is appropriately finely textured and homogenous with normal echogenicity relative to surrounding tissue (hyperechoic to liver). Multifocal well-demarcated hyperechoic homogenous nodules are noted. Splenic vasculature appears normal.

Liver

Liver is subjectively enlarged (swollen contour) without disruption of architecture. It has a normal homogenous echotexture. Parenchyma is diffusely hyperechoic characterized by less prominent than normal portal vein walls and increased echogenicity relative to the spleen and falciform fat. Multifocal discrete, hypoechoic nodules of varying sizes are noted throughout the parenchyma. Visible vasculature and biliary tree appear normal without distension or congestion.

The gallbladder is non-distended in size. The wall is smooth without visible thickening. Luminal contents are primarily anechoic. There is no evidence of cystic or common bile duct dilation.

Gastrointestinal

The stomach wall is normal in thickness (canine < 0.5 cm and feline < 0.4 cm) and layering. The lumen of the stomach is empty with no evidence of obstruction, foreign material or infiltrative disease. Pyloric outflow tract appears patent.

The visible small intestines are normal in wall thickness and layering. Hyperechoic mucosal fogging or speckling is noted. Small intestinal motility appears adequate (1-3 contractions per min). The lumen is empty with no evidence of obstruction or foreign material.

The visible colon is normal in wall thickness (< 0.2 cm) and layering. Contents are consistent with normal formed feces and gas.

Pancreas

The pancreatic parenchyma is appropriately isoechoic to surrounding tissue. Visible capsule is smooth and normal in contour. There is no visible pancreatic duct dilation. There is no evidence of active peripancreatic inflammation.

Free Abdomen

There is no evidence of free peritoneal effusion noted in these images.

There is no apparent lymphadenopathy noted in these images.

PRIMARY FINDINGS

- **Hyperechoic hepatomegaly with multifocal hypoechoic nodules** - This appearance is non-specific and most consistent with a benign steroid (endocrine) or vacuolar hepatopathy or reactive or idiopathic hepatopathy. Inflammatory and/or infiltrative disease (such as round cell neoplasia) are also possible, but considered less likely. Differentials for the hypoechoic nodules include both benign disease such as nodular hyperplasia as well as infiltrative or metastatic neoplasia, which can't be ruled out without tissue sampling.
- **Mucosal speckling** - Mucosal speckling is often present with inflammatory bowel disease (IBD). It is not specific for type or severity of disease. Mild speckling change can occur as a normal patient variant in the post-prandial state.

SECONDARY FINDINGS

- **Hyperechoic splenic nodules** - most consistent with benign myelolipomas. Other differentials such as fibrosis or calcification caused by old hematomas or infarcts, chronic inflammation, granulomatous disease or metastatic disease cannot be ruled out, but are considered less likely.
- Age related kidney changes with non-obstructive nephrolithiasis bilaterally

INTERPRETATION OF THE FINDINGS & FURTHER RECOMMENDATIONS

Three view thoracic radiographs are recommended for further assessment of cardio-pulmonary status as well as to further evaluate for any evidence of metastatic disease, if not recently evaluated.

A fine needle aspirate of the liver is recommended if patient's coagulation status is appropriate.

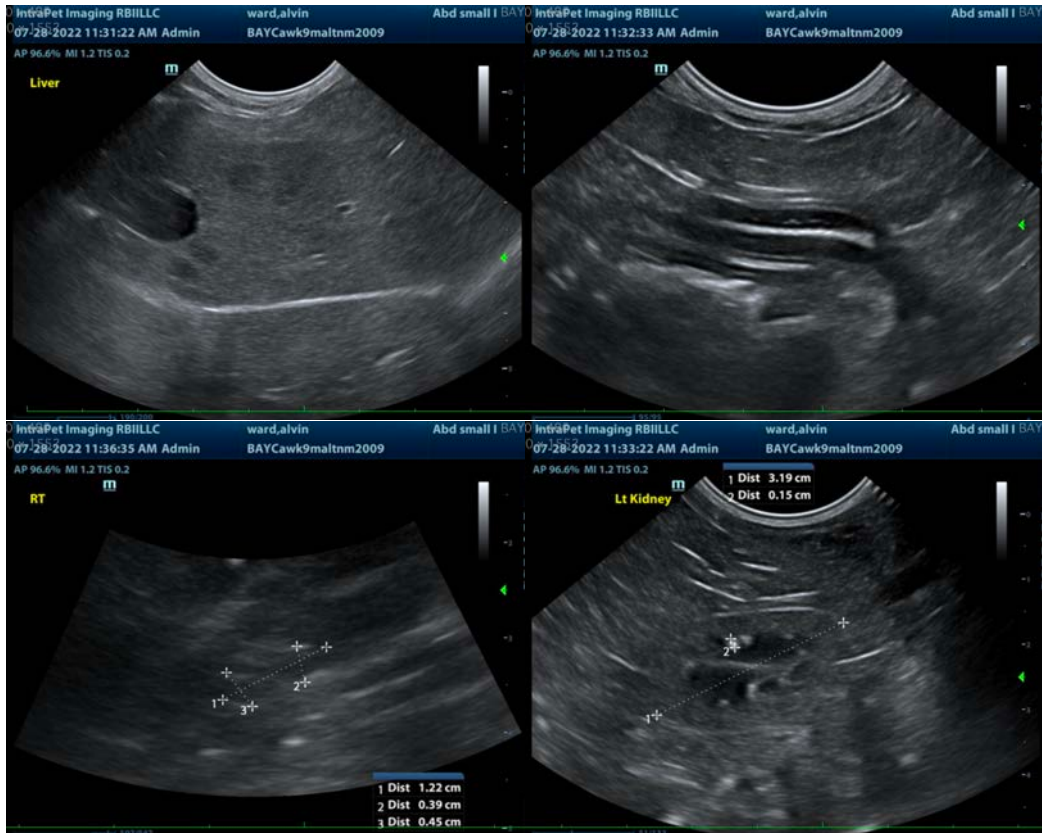
Given the reported inappetence combined with the mucosal speckling, a gastrointestinal malabsorption panel (including cobalamin, folate, TLI and PLI) to Texas A&M GI Laboratory is recommended for further evaluation of GI and pancreatic function.

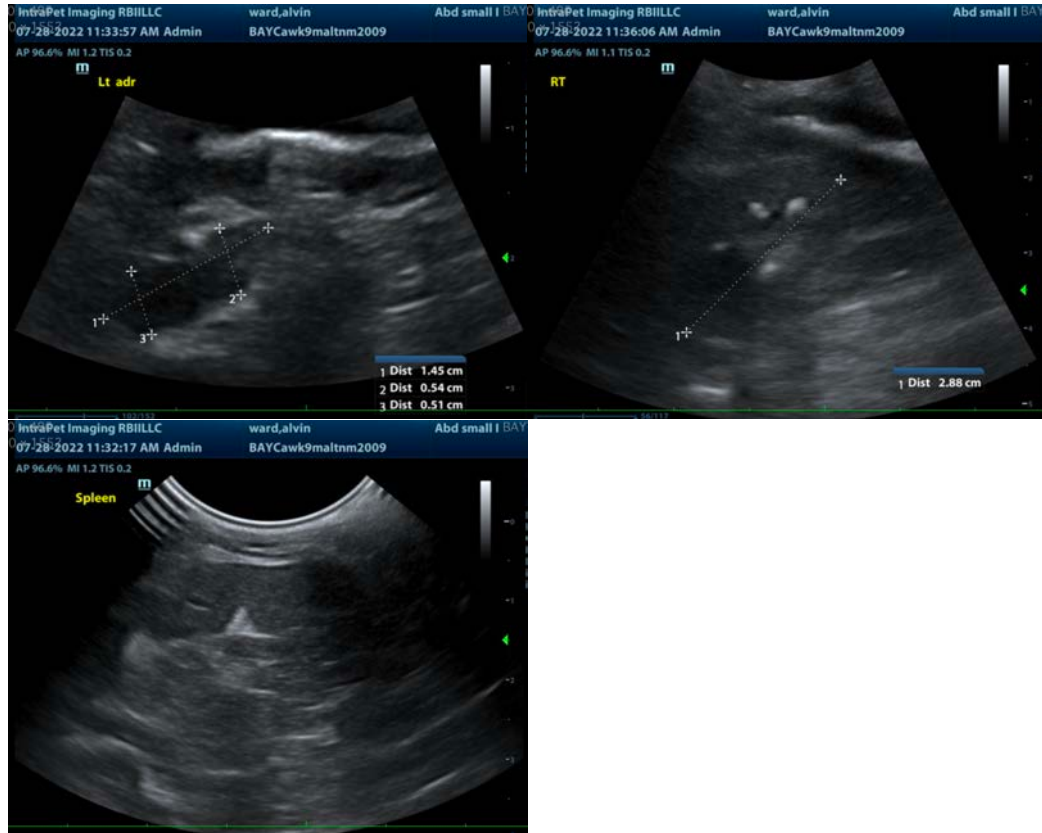
Given the reported shaking combined with proteinuria noted, a urine protein to creatinine ratio is recommended to quantify the proteinuria. A blood pressure is recommended if not recently evaluated, both indicated to look for a possible underlying of a potential vascular event that could result in shaking and/or neurologic signs.

A baseline cortisol is recommended. If baseline cortisol is less than 2, a full ACTH stimulation test is recommended to rule out hypoadrenocorticism.

In the meantime, supportive symptomatic management is recommended in the form of antiemetics, gastroprotectants, appetite stimulants, as well as at least a short term transition to a low-fat diet pending tests.

Empirical deworming with a 5-day course of Panacur could be considered if not recently done.





The information and recommendations provided are based on the images presented by the referring veterinarian/sonographer. No evaluation can be communicated regarding pathology that was not visible in the image/video clips provided.

Thank you for this referral. If the clinical or image interpretation does not parallel your findings or if I can be of any further assistance please contact me.

Beth Johnson, DVM, DACVIM
Beth.Johnson@sonopath.com