

**DATE**

7/27/22

**PRESENTING CLINICAL SIGNS**

Patient was presented for vomiting. Blood work revealed mild anemia (37.1) but was otherwise unremarkable. Radiographs were NSF.  
Current Medications: None.

**PATIENT**

Darcy Smith

Date of Previous IntraPet Ultrasound: No previous.  
Sedation: Not required to complete full diagnostic ultrasound.  
Stat Report: Not requested.  
Imaging Performed By: Rachel Brillhart, RDMS

**SPECIES**

Canine

**ULTRASONOGRAPHIC EXAMINATION OF THE ABDOMEN****Urinary System****BREED**

Mix

Urinary bladder is adequately distended with anechoic contents. No masses, inflammatory changes, echogenic sediment or cystoliths are observed. The urinary bladder, trigone and visible pelvic urethra are normal in thickness with a smooth mucosal surface.

**SEX**

Spayed female

Left kidney is normal is size (5.8 cm), shape and echogenicity. It has smooth peripheral margination. There is a normal 1:3 cortex to medulla ratio with appropriate corticomedullary distinction. There is no evidence of pyelectasia, mineral or infarcts observed.

**AGE**

2/14/10

Right kidney is normal is size (4.81 cm), shape and echogenicity. It has smooth peripheral margination. There is a normal 1:3 cortex to medulla ratio with appropriate corticomedullary distinction. There is no evidence of pyelectasia, mineral or infarcts observed.

**WEIGHT**

54 lbs

**Adrenal Glands**

Left adrenal gland is normal in size (3.03 cm long, 0.84 cm at cranial pole and 0.68 cm at caudal pole), shape and overall architecture, echogenicity and echotexture. Visible surrounding vasculature appears normal. A small, hyperechoic nodule was noted in the cranial pole of the left adrenal gland was noted and does not disrupt normal shape and/or architecture.

**INTERPRETED BY**Beth Johnson, DVM  
DACVIM

Right adrenal gland is normal in size (3.26 cm long, 0.77 cm at cranial pole and 0.79 cm at caudal pole), shape and overall architecture, echogenicity and echotexture. Visible surrounding vasculature appears normal.

**HOSPITAL NAME**

Madonna VC

**Spleen**

Spleen is subjectively large in size with a mildly swollen but smooth capsule. Parenchyma is normal and homogenous in echogenicity and echotexture. No focal nodules or masses are observed. Splenic vasculature appears normal.

**REFERRING VET**

Dr. Smith

**Liver**

Liver is relatively normal in size and contour. Parenchyma is mildly heterogenous and coarse with mild likely age-related parenchymal remodeling noted. No focal lesions are observed. Visible vasculature and biliary tree appear normal without distension or congestion. Gallbladder is non-distended in size. The wall is smooth without visible thickening. Luminal contents are primarily anechoic with some echogenic debris noted. There is no evidence of cystic or common bile duct dilation.

**INVOICE**

31991

**Gastrointestinal**

The visible stomach wall is normal in thickness and layering. The lumen of the stomach is empty with no evidence of obstruction, foreign material or infiltrative disease. Pyloric outflow tract appears patent.  
OR

The visible small intestines are normal in wall thickness and layering. Small intestinal motility appears adequate (1-3 contractions per min). The lumen of the small intestine is empty with no evidence of obstruction, foreign material or infiltrative disease.

The visible colon is normal in wall thickness (< 0.2 cm) and layering. Contents are consistent with normal formed feces and gas.

### ***Pancreas***

The observed pancreas appears appropriately isoechoic to surrounding omental fat. The capsule is mildly irregular in shape. Parenchyma is mildly heterogenous, coarse and hyperechoic. Very mild duct dilation is present. There is no evidence of active peripancreatic inflammation.

### ***Free Abdomen***

There is no evidence of free peritoneal effusion noted in these images.

There is no apparent lymphadenopathy noted in these images.

## **ULTRASONOGRAPHIC FINDINGS**

### **Primary Findings**

- **Pancreatic age-related remodeling with concurrent hyperechoic pancreas** – Mild irregularities are consistent with benign age-related change. Low-grade smoldering chronic pancreatitis cannot be ruled out and should be suspected in the face of appropriate clinical signs. The hyperechoic pancreas finding is suggestive of pancreatic fibrosis, possibly secondary to chronic pancreatitis. A TLI is recommended to rule out exocrine pancreatic insufficiency (EPI), especially if clinical signs (weight loss, diarrhea, etc.) are present.
- **Hypersplenism** – can be associated with congestion caused by sedation (if sedated) but can also be associated with diffuse infiltrative disease. Both benign conditions such as extramedullary hematopoiesis, lymphoid hyperplasia, amyloidosis (leave amyloidosis out if canine) as well as infiltrative neoplastic diseases such as round cell neoplasia should be considered.

### **Secondary Findings**

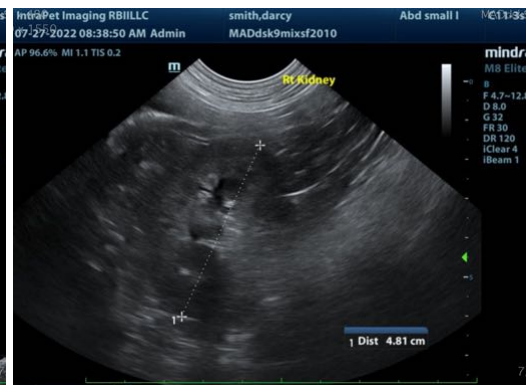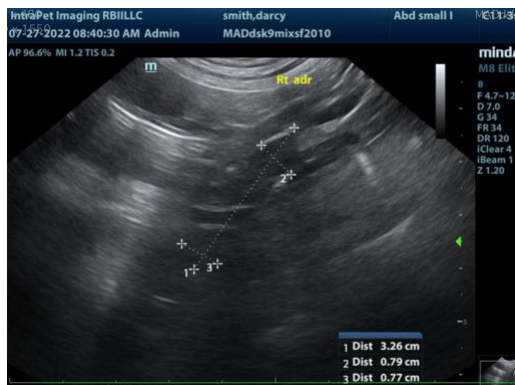
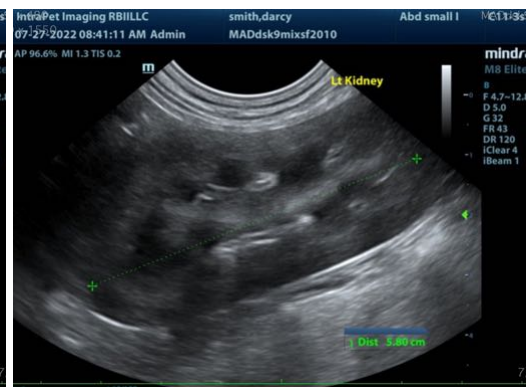
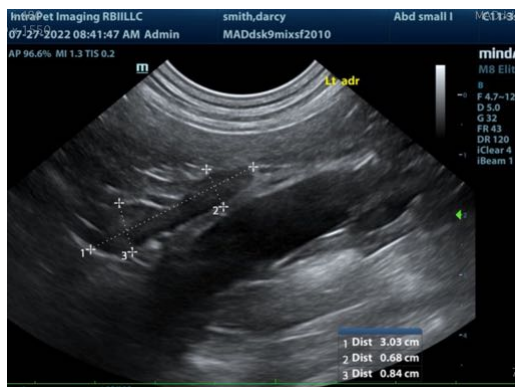
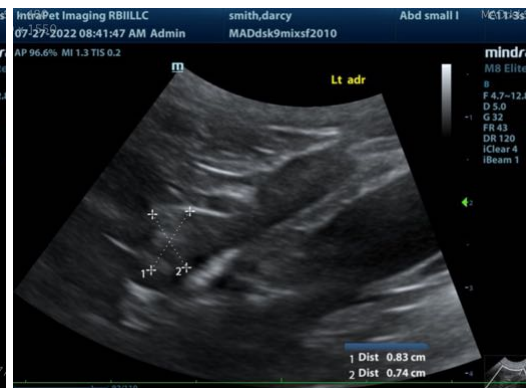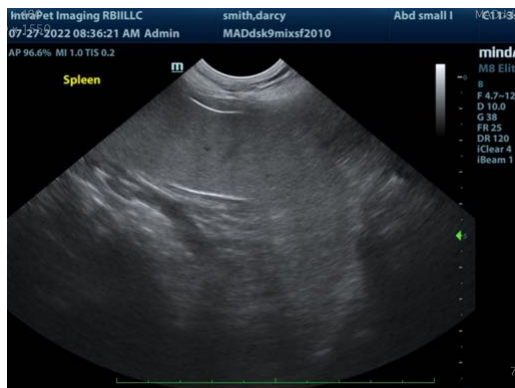- **Hyperechoic adrenal nodule in the left adrenal gland** – Differentials include primary adrenal cortical adenoma or adenocarcinoma, pheochromocytoma, myelolipoma, adrenal hyperplasia secondary to pituitary disease or metastatic disease. Ultrasound alone cannot differentiate between functional and non-functional nodules and/or between benign and malignant disease. Small nodules without other evidence of abdominal disease (to suggest metastatic disease) and/or clinical signs (to suggest adrenal disease) are most often incidental and should be monitored.
- **Age related hepatic changes.**

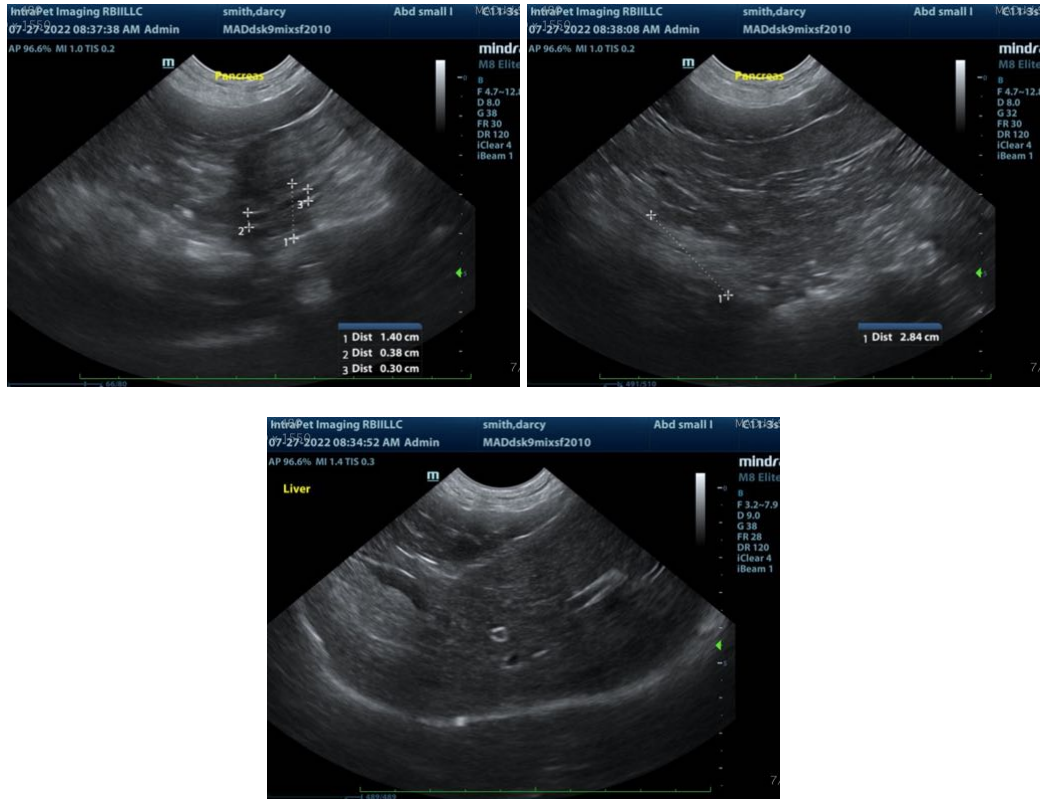
## **INTERPRETATION OF THE FINDINGS & FURTHER RECOMMENDATIONS**

The described ultrasound changes are non-specific and likely benign in nature without an obvious cause for the patient's reported vomiting and/or anemia. Recommendations include:

1. A gastrointestinal malabsorption panel (including cobalamin, folate, TLI and PLI) to Texas A&M GI Laboratory is recommended for further evaluation of GI and pancreatic function.

2. FNA of the spleen can be considered if the patient's coagulation status is appropriate.
3. In the meantime, given the reported anemia and vomiting a fecal exam is recommended if not recently evaluated followed by empirical deworming with a 5 day course of Panacur combined with supportive symptomatic therapy of acute gastroenteritis, antiemetics, gastroprotectants including Sucralfate, etc. If clinical signs persist and/or progress recheck imaging is recommended.
4. In addition to supportive care, given the pancreatic changes, temporary transition to a low-fat diet can also be considered.





The information and recommendations provided are based on the images presented by the referring veterinarian. No evaluation can be communicated regarding pathology that was not visible in the image/video clips provided.

Thank you for this referral. If the clinical or image interpretation does not parallel your findings or if I can be of any further assistance please contact me.

**Beth Johnson, DVM DACVIM**  
Beth.Johnson@SonoPath.com