

IMAGING PERFORMED BYSVS Mobile Imaging MI 734-637-7711
svsimagingmi@gmail.comEDUCATIONAL TELECONSULTATION SERVICES™
1-800-838-4268 info@sonopath.com SonoPath.com**PATIENT**

Walter Palmer

SPECIES

Canine

BREEDBlack & Tan
Coonhound**SEX**

Neutered Male

AGE

1 Year 2 Months

WEIGHT

68.6 Pounds

INTERPRETED BYBeth Johnson, DVM
DACVIM**IMAGING PERFORMED BY**

Amy Mayhew, LVT

HOSPITAL NAME

SVS Imaging MI

REFERRING VET

Dr. Coleman

INVOICE

44364

DATE

7/27/23

PRESENTING CLINICAL SIGNS

Chronic diarrhea of eight weeks duration

Abnormal PE/Chem/CBC/UA Results: Approximately eight weeks ago patient acutely developed large bowel diarrhea. The initial onset occurred when transitioning from puppy to adult food but persisted even when owner transitioned back to original diet. Patient was seen elsewhere, and a fecal sample was Giardia ELISA positive. Patient was treated with panacea and pro-pectalin. Patient did not improve. Metronidazole (12mg/kg BID for 10 days) was prescribed. The stool began to firm up but did not return to normal prior to stopping treatment. A recheck fecal on 06/28/2023 was no parasites seen and Giardia ELISA negative. Panacur (50mg/kg PO SID x 5 days) was repeated despite fecal result. Patient was also started on Royal Canin GI Low Fat canned food but again did not improve. A second 10 day course of metronidazole (12mg/kg PO BID) was repeated beginning on 07/01/2023. The stool did not improve. The patient was seen on 07/10/2023 for a Total Health blood panel to Idexx and GI Panel to Texas A&M University (see attached results). A third fecal was NPS and Giardia ELISA negative on 07/18/2023. This sample was also submitted for a Diarrhea PCR Panel to Idexx (see attached results) that was positive for Clostridium perfringens. Patient started Hill's GI Biome diet on 07/16/2023. By 07/21/2023 patients stool was formed and there was no urgency to defecate, straining or blood noted in his stool.

ULTRASONOGRAPHIC EXAMINATION OF THE ABDOMEN**Urinary System**

The urinary bladder is moderately distended with anechoic contents. No masses, inflammatory changes, echogenic sediment or cystoliths are observed. The urinary bladder, trigone and visible pelvic urethra are normal in thickness with a smooth mucosal surface.

Prostate is normal in size, echotexture and echogenicity for a neutered male.

The right kidney is normal in size (7.13 cm), shape and echogenicity. It has smooth peripheral margination. There is a normal 1:3 cortex to medulla ratio with appropriate corticomedullary distinction. There is no evidence of pyelectasia, mineral or infarcts observed.

The left kidney is normal in size (6.95 cm), shape and echogenicity. It has smooth peripheral margination. There is a normal 1:3 cortex to medulla ratio with appropriate corticomedullary distinction. There is no evidence of pyelectasia, mineral or infarcts observed.

Adrenal Glands

Adrenal glands are small (flattened contour). Corticomedullary structure is unremarkable. Visible surrounding vasculature appears normal. The left adrenal gland measures 0.34 cm at the cranial pole and 0.43 cm at the caudal pole. The right adrenal gland measured 0.35 cm at the caudal pole. The cranial pole of the right adrenal gland is difficult to fully visualize in these images.

Spleen

The spleen is subjectively normal in size with a normal smooth capsular contour. Parenchyma is appropriately finely textured and homogenous with normal echogenicity relative to surrounding tissue (hyperechoic to liver). No focal nodules or masses are observed. Splenic vasculature appears normal.

IMAGING PERFORMED BY

SVS Mobile Imaging MI 734-637-7711
svsimagingmi@gmail.com

**PATIENT**

Walter Palmer

SPECIES

Canine

BREEDBlack & Tan
Coonhound**SEX**

Neutered Male

AGE

1 Year 2 Months

WEIGHT

68.6 Pounds

INTERPRETED BYBeth Johnson, DVM
DACVIM**IMAGING PERFORMED BY**

Amy Mayhew, LVT

HOSPITAL NAME

SVS Imaging MI

REFERRING VET

Dr. Coleman

INVOICE

44364

DATE

7/27/23

Liver

The liver is subjectively normal in size with normal smooth curvilinear peripheral contour. Parenchyma is appropriately hypoechoic to the spleen in echogenicity and appropriately mildly coarse and homogenous in echotexture. No focal lesions are observed. Visible vasculature and biliary tree appear normal without distension or congestion.

The gallbladder is non-distended in size. The wall is smooth without visible thickening. Luminal contents are primarily anechoic. There is no evidence of cystic or common bile duct dilation.

Gastrointestinal

The stomach wall is normal in thickness (canine < 0.5 cm and feline < 0.4 cm) and layering. The lumen of the stomach is empty with no evidence of obstruction, foreign material or infiltrative disease. Pyloric outflow tract appears patent.

The visible small intestines are normal in wall thickness and layering (canine duodenum < 0.5 cm and feline duodenum < 0.4 cm; other < 0.3 cm). Small intestinal motility appears adequate (1-3 contractions per min). The lumen of the small intestine is largely empty. However, in several small bowel loops there are intraluminal echogenic densities with strong acoustic shadow without evidence of obstruction, plication, etc.

The visible colon is normal in wall thickness (< 0.2 cm) and layering. Contents are consistent with normal formed feces and gas.

Pancreas

The pancreatic parenchyma is appropriately isoechoic to surrounding tissue. Visible capsule is smooth and normal in contour. There is no visible pancreatic duct dilation. There is no evidence of active peripancreatic inflammation.

Free Abdomen

There is no evidence of free peritoneal effusion noted in these images.

The mesenteric and medial iliac lymph nodes are prominent in size with swollen capsular contour. Normal elongated shape (length to width ratio) is maintained. There is no loss of parenchymal detail.

ULTRASONOGRAPHIC FINDINGS

- Flat adrenal glands – This can be a normal patient variant and/or a sign of exogenous cortisol administration. If exogenous steroids are not being administered, hypoadrenocorticism (either relative or absolute) should be considered. **This may be a normal patient variant, given the young age.
- Reactive mesenteric and medial iliac lymph nodes – infiltrative neoplastic disease cannot be ruled out but is considered less likely. This may be in part normal patient variant, given the young age.
- Several non-obstructive suspect foreign objects noted throughout the small bowel – These likely represent incidental passing foreign material/debris or even a pill, etc. This finding should be interpreted in combination with the development of clinical signs or lack thereof.

IMAGING PERFORMED BY

SVS Mobile Imaging MI 734-637-7711
svsimagingmi@gmail.com



PATIENT

Walter Palmer

SPECIES

Canine

BREED

Black & Tan
Coonhound

SEX

Neutered Male

AGE

1 Year 2 Months

WEIGHT

68.6 Pounds

INTERPRETED BY

Beth Johnson, DVM
DACVIM

IMAGING PERFORMED BY

Amy Mayhew, LVT

HOSPITAL NAME

SVS Imaging MI

REFERRING VET

Dr. Coleman

INVOICE

44364

DATE

7/27/23

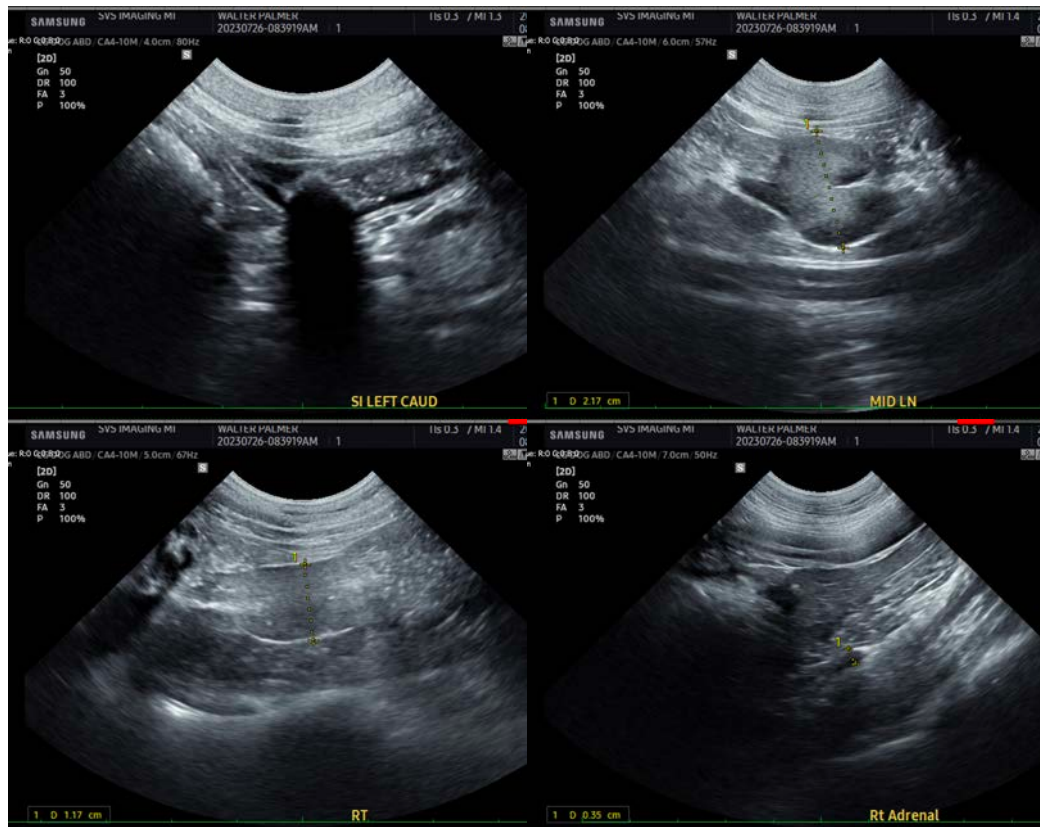
INTERPRETATION OF THE FINDINGS & FURTHER RECOMMENDATIONS

Given this patient's current improved clinical status, the differentials for the diarrhea include the combination of infectious organisms (i.e., giardia, clostridium, etc.), as well as potentially other underlying dietary insensitivity/allergy, etc., given the lack of improvement with infectious organism therapy alone.

Having said that, some cases of clostridium require a variety of antibiotics and/or a longer treatment course, and if clinical signs in this patient return, a course of Tylosin therapy (6-8 weeks) could be considered.

If the GI Biome diet is not continued, an alternative could include probiotic such as daily Visbiome or Provable. Ultimately, however, some young dogs similar to this patient ultimately need a fecal transplant.

Given this patient's flat adrenal glands and low baseline cortisol, a full ACTH stimulation test is also recommended.



IMAGING PERFORMED BY

SVS Mobile Imaging MI 734-637-7711
svsimagingmi@gmail.com



EDUCATIONAL TELECONSULTATION SERVICES™
1-800-838-4268 info@sonopath.com SonoPath.com

PATIENT

Walter Palmer

SPECIES

Canine

BREED

Black & Tan
Coonhound

SEX

Neutered Male

AGE

1 Year 2 Months

WEIGHT

68.6 Pounds

INTERPRETED BY

Beth Johnson, DVM
DACVIM

IMAGING PERFORMED BY

Amy Mayhew, LVT

HOSPITAL NAME

SVS Imaging MI

REFERRING VET

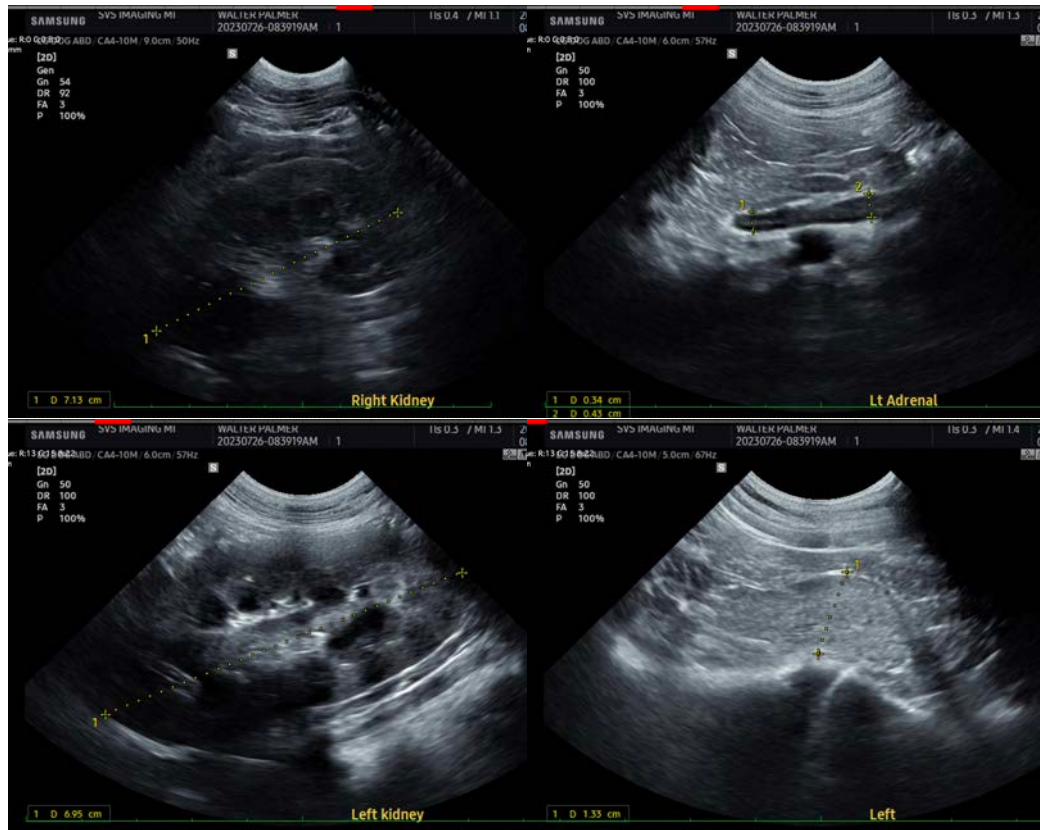
Dr. Coleman

INVOICE

44364

DATE

7/27/23



The information and recommendations provided are based on the images presented by the referring veterinarian/sonographer. No evaluation can be communicated regarding pathology that was not visible in the image/video clips provided.

Thank you for this referral. If the clinical or image interpretation does not parallel your findings or if I can be of any further assistance please contact me.

Beth Johnson, DVM, DACVIM
info@sonopath.com