

**PATIENT PRESENTING CLINICAL SIGNS**

**Todd Smith**  
**SPECIES** Canine  
**BREED** Yorkshire Terrier  
**SEX** Neutered Male  
**AGE** 9 Years  
**WEIGHT** 7.7 kg

Diabetic patient with abdominal tension previously diagnosed by other vet at Banfield. Abdominal radiographs revealed enlarged liver but also a questionable proximal ureterolith vs retroperitoneal mineralization in a lymph node. Recommended ultrasound to further investigate urinate tract. repeated rads after AUS and did not see a proximal hyperechoic foci in retroperitoneal area- MEDSVetsulin 6 units BID; Gabapentin 100 mg PO BID; Rimadyl 25 mg 0.5 tab PO BID

**ULTRASONOGRAPHIC EXAMINATION OF THE ABDOMEN**

**Urinary System**

The urinary bladder is adequately distended with primarily anechoic contents as well as a small amount of echogenic debris, including some sand/mineral debris and one punctate cystolith that measures 0.16 cm in diameter. No masses or inflammatory changes are observed. The urinary bladder, trigone and visible pelvic urethra are normal in thickness with a smooth mucosal surface.

Prostate is normal in size, echotexture and echogenicity for a neutered male.

The right kidney is normal in size (5.1 cm), shape and echogenicity. It has smooth peripheral margination. There is a normal 1:3 cortex to medulla ratio with appropriate corticomedullary distinction. There is no evidence of pyelectasia, mineral or infarcts observed.

The left kidney is normal in size (5.4 cm), shape and echogenicity. It has smooth peripheral margination. There is a normal 1:3 cortex to medulla ratio with appropriate corticomedullary distinction. There is no evidence of pyelectasia, mineral or infarcts observed.

**Adrenal Glands**

The right adrenal gland is normal in size (0.74 cm at the cranial pole and 0.45 cm at the caudal pole), shape and contour. Corticomedullary structure is unremarkable. Visible surrounding vasculature appears normal.

The left adrenal gland is normal in size (0.40 cm at the cranial pole and 0.56 cm at the caudal pole), shape and contour. Corticomedullary structure is unremarkable. Visible surrounding vasculature appears normal.

**Spleen**

The spleen is subjectively normal in size with a normal smooth capsular contour. Parenchyma is appropriately finely textured and homogenous with normal echogenicity relative to surrounding tissue (hyperechoic to liver). No focal nodules or masses are observed. Splenic vasculature appears normal.

**Liver**

The liver is subjectively normal in size with normal smooth curvilinear peripheral contour. Parenchyma is appropriately hypoechoic to the spleen in echogenicity and appropriately mildly coarse and homogenous in echotexture. No focal lesions are observed. Visible vasculature and biliary tree appear normal without distension or congestion.

Gallbladder is moderately distended with anechoic bile as well as suspended and gravity dependent echogenic debris. The wall is smooth without visible thickening. There is no evidence of cystic or CBD dilation. There is no evidence of effusion or inflammation.

**INTERPRETED BY**

Beth Johnson, DVM  
DACVIM

**IMAGING PERFORMED BY**

Loetitia Saint-Jacques,  
LVT

**HOSPITAL NAME**

Peavine AH

**REFERRING VET**

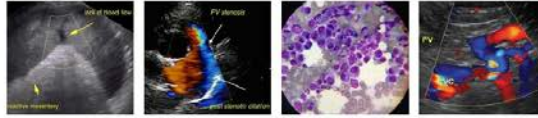
Dr. Brittany Spurling

**INVOICE**

44367

**DATE**

7/26/23



**PATIENT** *Gastrointestinal*

Todd Smith The stomach wall is normal in thickness (canine < 0.5 cm and feline < 0.4 cm) and layering. The lumen of the stomach is empty with no evidence of obstruction, foreign material or infiltrative disease. Pyloric outflow tract appears patent.

**SPECIES**

Canine Diffusely, the visible small intestines are normal in wall thickness and layering (canine duodenum < 0.5 cm and feline duodenum < 0.4 cm; other < 0.3 cm). Small intestinal motility appears adequate (1-3 contractions per min). However, in the mid abdomen there is a mildly hyperperistaltic/corrugated small bowel loop of unknown significant. The lumen of the small intestine is empty with no evidence of obstruction, foreign material or infiltrative disease.

**BREED**

Yorkshire Terrier

**SEX**

The visible colon is normal in wall thickness (< 0.2 cm) and layering. Contents are consistent with normal formed feces and gas.

Neutered Male

**Pancreas**

**AGE**

The pancreatic parenchyma is appropriately isoechoic to surrounding tissue. Visible capsule is smooth and normal in contour. There is no visible pancreatic duct dilation. There is no evidence of active peripancreatic inflammation.

9 Years

**WEIGHT**

**Free Abdomen**

7.7 kg

There is no evidence of free peritoneal effusion noted in these images.

**INTERPRETED BY**

The mesenteric and medial iliac lymph nodes are prominent in size with swollen capsular contour. Normal elongated shape (length to width ratio) is maintained. There is no loss of parenchymal detail.

Beth Johnson, DVM  
DACVIM

**ULTRASONOGRAPHIC FINDINGS**

**IMAGING PERFORMED BY**

- Some mineral urinary bladder debris is noted as well as one tiny cystolith measuring 0.16 cm in diameter that can likely pass on its own. There is no evidence in these images of ureteroliths.
- Reactive mesenteric and medial iliac lymph nodes – infiltrative neoplastic disease cannot be ruled out but is considered less likely.
- Focal mildly hyperperistaltic corrugated small bowel loop was noted and is likely an incidental finding. However, gastroenteritis secondary to dietary indiscretion, parasitic disease, infectious disease, etc. can't be definitively ruled out.
- Mild gallbladder debris - Cholecystic debris is of unknown clinical significance. It can be seen with biliary stasis from fasting or illness. Cholecystic debris is not necessarily related to hepatobiliary disease. Echogenic bile is most commonly an incidental finding in dogs and should be interpreted in combination with clinical signs such as nausea, inappetence, cranial abdominal discomfort and/or laboratory changes such as increased ALP and/or increased Tbili.

Loetitia Saint-Jacques,  
LVT

**HOSPITAL NAME**

Peavine AH

**REFERRING VET**

Dr. Brittany Spurling

**INVOICE**

**INTERPRETATION OF THE FINDINGS & FURTHER RECOMMENDATIONS**

44367

Further recommendations are dependent on patient's continuing clinical signs or lack thereof. Again, there is no ultrasonographically visible evidence in these images of the previously questioned ureterolith. If this patient has abdominal pain and/or gastrointestinal signs, further evaluation of the mild/subtle bowel changes described above could be considered.

**DATE**

7/26/23



**PATIENT**

Todd Smith

**SPECIES**

Canine

**BREED**

Yorkshire Terrier

**SEX**

Neutered Male

**AGE**

9 Years

**WEIGHT**

7.7 kg

**INTERPRETED BY**

Beth Johnson, DVM  
DACVIM

**IMAGING PERFORMED BY**

Loetitia Saint-Jacques,  
LVT

**HOSPITAL NAME**

Peavine AH

**REFERRING VET**

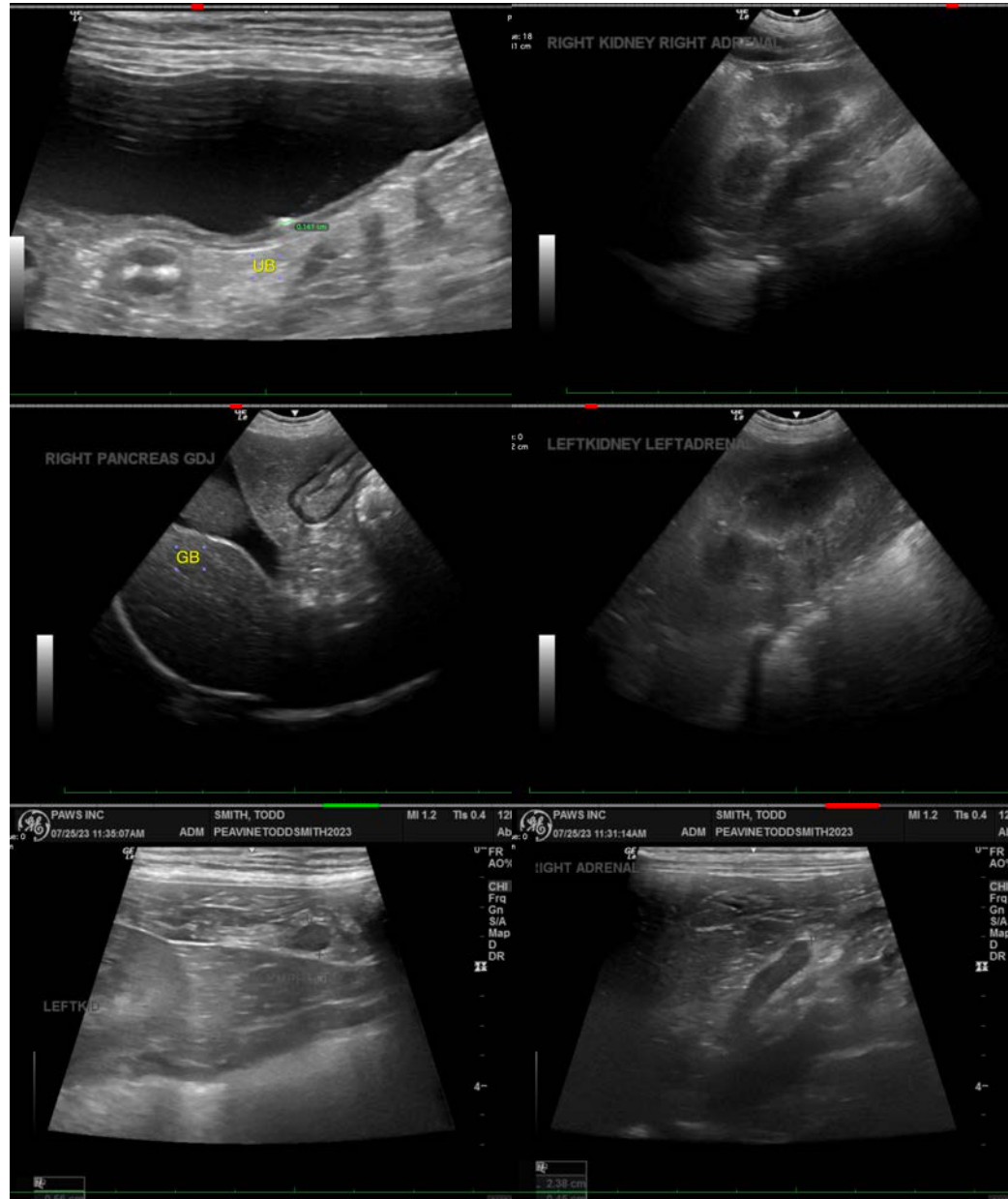
Dr. Brittany Spurling

**INVOICE**

44367

**DATE**

7/26/23





**PATIENT**

Todd Smith

**SPECIES**

Canine

**BREED**

Yorkshire Terrier

**SEX**

Neutered Male

**AGE**

9 Years

**WEIGHT**

7.7 kg

**INTERPRETED BY**

Beth Johnson, DVM  
DACVIM

**IMAGING PERFORMED BY**

Loetitia Saint-Jacques,  
LVT

**HOSPITAL NAME**

Peavine AH

**REFERRING VET**

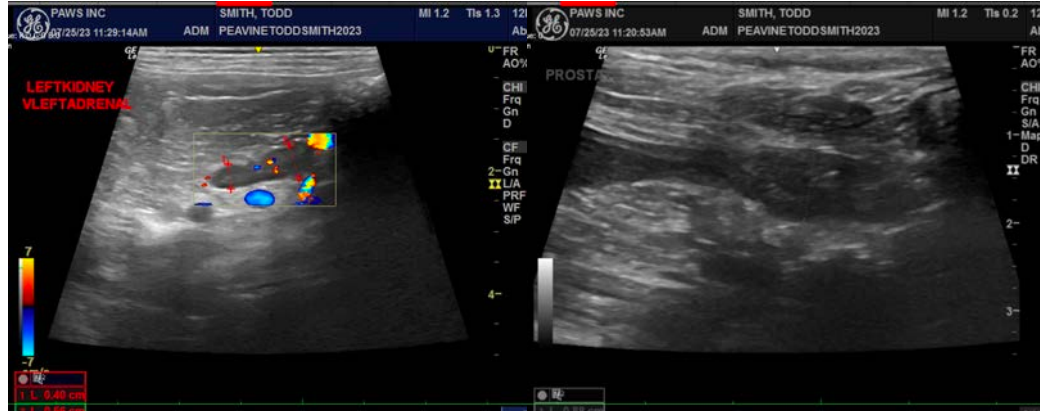Dr. Brittany Spurling

**INVOICE**

44367

**DATE**

7/26/23



The information and recommendations provided are based on the images presented by the referring veterinarian/sonographer. No evaluation can be communicated regarding pathology that was not visible in the image/video clips provided.

Thank you for this referral. If the clinical or image interpretation does not parallel your findings or if I can be of any further assistance please contact me.

Beth Johnson, DVM, DACVIM  
info@sonopath.com