

**DATE**

7/25/22

**PRESENTING CLINICAL SIGNS**

History: O reports weight gain (12 lbs in 6 months) and lethargy for about 1-1.5 months. Just "doesn't seem himself" Recent episodes of aggression towards strangers now. Feeding same amt of food (Nature's Logic -- not grain free--feeding 2.5-3 cups--420 kcal/cup RER about 1000kcal/day). Weight gain of 12 lbs in 6 months (questionably too much food-husband may be feeding too much?)

**PATIENT**

Quinn Roussil

**SPECIES**

Canine

**BREED**

Labrador

**SEX**

Neutered Male

**AGE**

8/15/16

**WEIGHT**

91.5 Pounds

**INTERPRETED BY**Beth Johnson, DVM  
DACVIM**HOSPITAL NAME**

Alexander AH

**REFERRING VET**

Dr. Alexander

**INVOICE**

16537

Current Medications: None listed.

Lab Results: BUN = 33, rest of BW WNL.

Date of Previous IntraPet Ultrasound: No previous.

Sedation: Not required to complete full diagnostic ultrasound.

Stat Report: Not requested.

Imaging Performed By: Stephanie Pearce RDCS, RVT.

**ULTRASONOGRAPHIC EXAMINATION OF THE ABDOMEN****Urinary System**

Urinary bladder is adequately distended with anechoic contents. No masses, inflammatory changes, echogenic sediment or cystoliths are observed. The urinary bladder, trigone and visible pelvic urethra are normal in thickness with a smooth mucosal surface.

Prostate (neutered) is normal in size, echotexture and echogenicity for a neutered male.

Left kidney is normal is size (6.98 cm), shape and echogenicity. It has smooth peripheral margination. There is a normal 1:3 cortex to medulla ratio with appropriate corticomedullary distinction. There is no evidence of pyelectasia, mineral or infarcts observed.

Right kidney is normal is size (7.08 cm), shape and echogenicity. It has smooth peripheral margination. There is a normal 1:3 cortex to medulla ratio with appropriate corticomedullary distinction. There is no evidence of pyelectasia, mineral or infarcts observed.

**Adrenal Glands**

Left adrenal gland is normal in size (2.35 cm long x 0.53 cm at cranial pole and 0.6 cm at caudal pole), shape and overall architecture, echogenicity and echotexture. Visible surrounding vasculature appears normal.

Right adrenal gland is normal in size (3.27 cm long x 0.78 cm at cranial pole and 0.57 cm at caudal pole), shape and overall architecture, echogenicity and echotexture. Visible surrounding vasculature appears normal.

**Spleen**

Spleen is subjectively normal in size with a normal smooth capsular contour. Parenchyma is appropriately finely textured and homogenous with normal echogenicity relative to surrounding tissue (hyperechoic to liver). No focal nodules or masses are observed. Splenic vasculature appears normal.

**Liver**

Liver is subjectively normal in size with normal smooth curvilinear peripheral contour. Parenchyma is appropriately hypoechoic to the spleen in echogenicity and appropriately mildly coarse and homogenous in echotexture. No focal lesions are observed. Visible vasculature and biliary tree appear normal without distension or congestion.

Gallbladder is non-distended in size. The wall is smooth without visible thickening. Luminal contents are primarily anechoic. There is no evidence of cystic or common bile duct dilation.

### ***Gastrointestinal***

The visible stomach wall is normal in thickness and layering. The lumen of the stomach is empty with no evidence of obstruction, foreign material or infiltrative disease. Pyloric outflow tract appears patent.

The visible small intestines are normal in wall thickness and layering. Hyperechoic mucosal fogging or speckling is noted. Small intestinal motility appears adequate (1-3 contractions per min). The duodenum is mildly distended with echogenic non-shadowing luminal contents and gas consistent with normal ingesta, and empty beyond that. There is no evidence of obstruction, foreign material or infiltrative disease.

The visible colon is normal in wall thickness and layering. Contents are consistent with normal formed feces and gas.

### ***Pancreas***

The observed pancreas appears appropriately isoechoic to surrounding omental fat. Visible capsule is smooth and normal in contour. Visible pancreatic parenchyma is homogenous and unremarkable. There is no visible pancreatic duct dilation. There is no evidence of active peripancreatic inflammation.

### ***Free Abdomen***

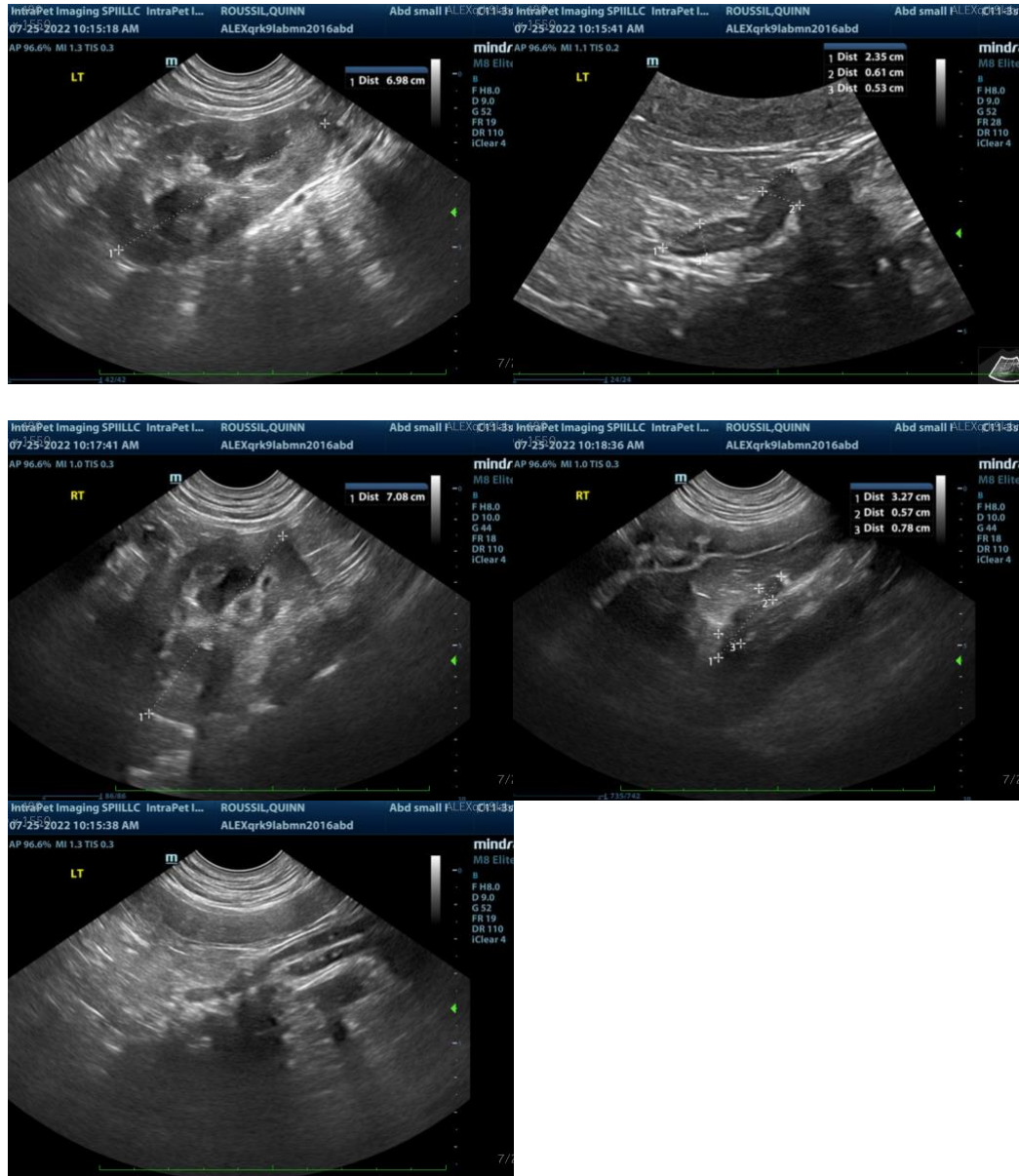
There is no evidence of peritoneal effusion. There is no apparent lymphadenopathy.

## **ULTRASONOGRAPHIC FINDINGS**

- Mucosal speckling – Mucosal speckling is often present with inflammatory bowel disease (IBD). It is not specific for type or severity of disease. Mild speckling change can occur as a normal patient variant in the post-prandial state. The speckling is just present in the portion of the bowel that also contains normal chyme/ingesta, so a postprandial state is considered most likely.

## **INTERPRETATION OF THE FINDINGS & FURTHER RECOMMENDATIONS**

- Given the mild mucosal speckling, a gastrointestinal malabsorption panel (including cobalamin, folate, TLI and PLI) to Texas A&M GI Laboratory, could be considered for further evaluation of GI and pancreatic function.
- If the reported weight gain is not able to be attributed to over-feeding, further evaluation of thyroid status with a T4, TSH, etc., could be considered.
- Given the concurrently reported behavior change, further neurologic evaluation could also be considered with advanced imaging of the brain a possibility.



The information and recommendations provided are based on the images presented by the referring veterinarian. No evaluation can be communicated regarding pathology that was not visible in the image/video clips provided.

Thank you for this referral. If the clinical or image interpretation does not parallel your findings or if I can be of any further assistance please contact me.

**Beth Johnson, DVM DACVIM**  
Beth.Johnson@SonoPath.com