

**DATE**

7/25/22

PRESENTING CLINICAL SIGNS**PATIENT**

Bella Herlehy

History: DM not well controlled. O reports pet still PU/PD with frequent urinary accidents. Insulin increased from 22 --> 24 U SQ BID last week due to recent BG curve. O reports episodes of collapse and laying her head down/panting. Pet always seems BAR here. No pain appreciated on abdominal palpation. Numerous lipomas and yellow diarrhea around anus. Last two days pet has had V/D, decreased appetite.

SPECIES

Canine

Current Medications: Vetsulin 24 U BID SQ, cerenia, metro and proviable for recent GI upset, Eats OM food
 Lab Results: ALT (199), AST (79), ALKP (163), U/A usg = 1.054, pro = 2+, glu = 3+, trace ketones. BG curve with 22 U prior to GI upset (but after "collapsing episodes" 9:15 466, 11:15 510, 1:15 505, 3:15 434.

BREED

Labrador

Date of Previous IntraPet Ultrasound: No previous.

Sedation: Not required to complete full diagnostic ultrasound.

Stat Report: Not requested.

Imaging Performed By: Stephanie Pearce RDCS, RVT.

SEX

Spayed Female

ULTRASONOGRAPHIC EXAMINATION OF THE ABDOMEN**AGE**

7/22/12

Urinary System

Urinary bladder is adequately distended with anechoic contents. No masses, inflammatory changes, echogenic sediment or cystoliths are observed. The urinary bladder, trigone and visible pelvic urethra are normal in thickness with a smooth mucosal surface.

WEIGHT

73.5 Pounds

Left kidney is normal is size (6.46 cm), shape and echogenicity. It has smooth peripheral margination. There is a normal 1:3 cortex to medulla ratio with appropriate corticomedullary distinction. There is no evidence of pyelectasia, mineral or infarcts observed.

Right kidney is normal is size (6.95 cm), shape and echogenicity. It has smooth peripheral margination. There is a normal 1:3 cortex to medulla ratio with appropriate corticomedullary distinction. There is no evidence of pyelectasia, mineral or infarcts observed.

INTERPRETED BYBeth Johnson, DVM
DACVIM**Adrenal Glands**

Adrenal glands are largely normal in size, shape and contour. Some parenchymal heterogeneity is present without concerning capsular distortion. These changes are likely normal for this age but should be monitored if there is any suspicion of adrenal disease. The left adrenal gland measures 2.85 cm long x 0.65 cm at the cranial pole and 0.72 cm at the caudal pole. The right adrenal gland measures 3.25 cm long x 1.4 cm at the cranial pole and 0.85 cm at the caudal pole.

HOSPITAL NAME

Alexander AH

Spleen

Spleen is subjectively normal in size with a normal smooth capsular contour. Parenchyma is appropriately finely textured and homogenous with normal echogenicity relative to surrounding tissue (hyperechoic to liver). No focal nodules or masses are observed. Splenic vasculature appears normal.

REFERRING VET

Dr. Alexander

Liver

Liver is subjectively enlarged with mildly irregular margins. Parenchyma is heterogenous characterized by multiple poorly defined hypoechoic nodules within otherwise hyperechoic liver parenchyma. Visible vasculature and biliary tree appear normal without distension or congestion.

INVOICE

16535

Gallbladder is non-distended in size. The wall is smooth without visible thickening. Luminal contents are primarily anechoic. There is no evidence of cystic or common bile duct dilation.

Gastrointestinal

The visible stomach wall is normal in thickness and layering. The lumen of the stomach is empty with no evidence of obstruction, foreign material or infiltrative disease. Pyloric outflow tract appears patent. The visible small intestines are normal in wall thickness and layering. Small intestinal motility appears adequate (1-3 contractions per min). The lumen of the small intestine is empty with no evidence of obstruction, foreign material or infiltrative disease.

The visible colon is normal in wall thickness and layering. Contents are consistent with normal formed feces and gas.

Pancreas

Pancreas is prominent (enlarged) in size and mildly irregular in shape with a slightly undulating contour. Parenchyma is coarse in echotexture and heterogenous to hypoechoic in echogenicity.

Free Abdomen

There is no evidence of peritoneal effusion. There is no apparent lymphadenopathy.

ULTRASONOGRAPHIC FINDINGS

Primary Findings

- Heterogenous Liver – These changes are most consistent with benign processes such as nodular hyperplasia, steroid (vacuolar) hepatopathy, extramedullary hematopoiesis or possibly chronic inflammatory disease and less commonly infiltrative round cell or metastatic neoplasia.
- Chronic active pancreatitis

Secondary Findings

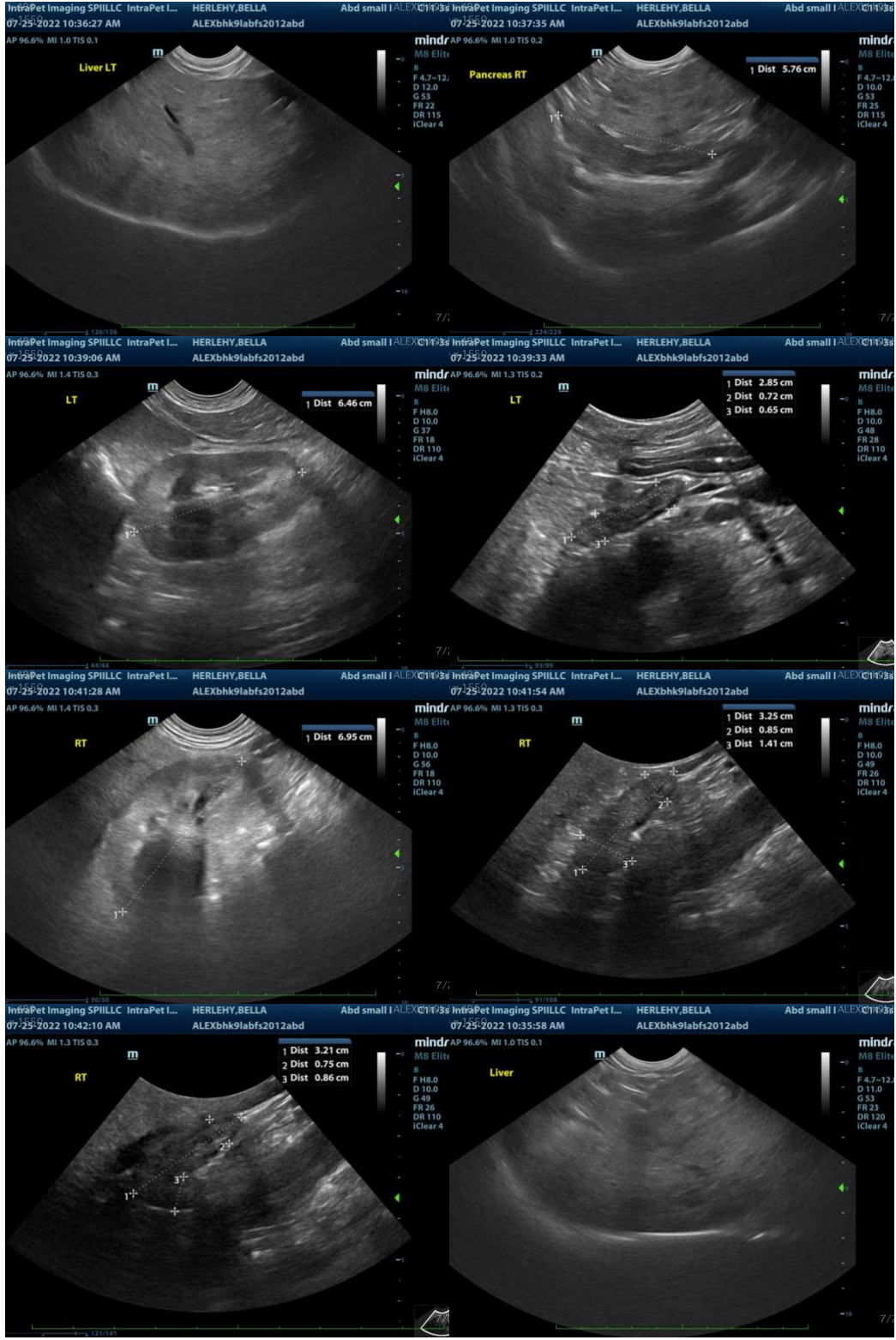
- Age-related adrenal gland changes

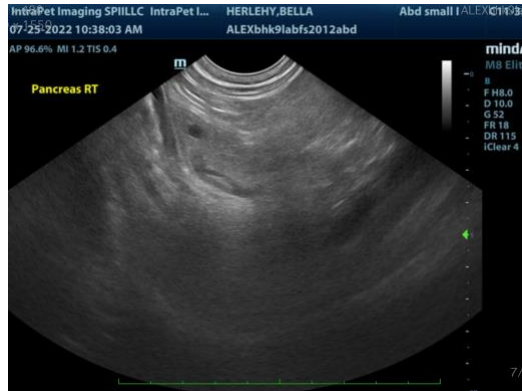INTERPRETATION OF THE FINDINGS & FURTHER RECOMMENDATIONS

A gastrointestinal malabsorption panel (including cobalamin, folate, TLI and PLI) to Texas A&M GI Laboratory is recommended for further evaluation of GI and pancreatic function.

A urine culture is recommended to rule out an occult urinary tract infection, if not recently evaluated.

Given this patient's reported weight and dose of insulin, the cause of the reported collapse, being secondary to hypoglycemia, seems unlikely. However, dogs can somogyi or develop episodes of hypoglycemia at this dose. Therefore, a consideration could be a longer-term blood glucose curve or even placement of a freestyle Libre sensor for at-home monitoring, to rule out hypoglycemia as a contributing factor. Again, however, at this patient's reported weight and dose, the poor regulation is likely due to not enough versus too much insulin and the collapse, secondary to something else. Therefore, further workup of the gastrointestinal +/- pancreatic disease, as mentioned, is recommended, as well as a fine needle aspirate of the liver, as was reportedly performed with cytology pending. A blood pressure is recommended, if not recently evaluated.





The information and recommendations provided are based on the images presented by the referring veterinarian. No evaluation can be communicated regarding pathology that was not visible in the image/video clips provided.

Thank you for this referral. If the clinical or image interpretation does not parallel your findings or if I can be of any further assistance please contact me.

Beth Johnson, DVM DACVIM
Beth.Johnson@SonoPath.com