

**DATE PRESENTING CLINICAL SIGNS**

7/25/22

History: Anorexia/hyporexia 3 days, occasional vomiting, significant weight loss

PATIENT

Current Medications: IVFT, cerenia, convenia started 7/25.

Lab Results: creat 2.0, evidence of dehydration, glu 268- r/p stress, pending u/a.

Radiographs: no evidence of obstruction, colon gas dilated.

Date of Previous IntraPet Ultrasound: No previous.

Sedation: Not required to complete full diagnostic ultrasound.

Stat Report: Not requested.

Imaging Performed By: Stephanie Pearce RDCS, RVT.

Anna Nicole McBurney

SPECIES

Feline

BREED

DSH

SEX

Spayed Female

AGE

2/21/07

WEIGHT

6.9 Pounds

INTERPRETED BYBeth Johnson, DVM
DACVIM**HOSPITAL NAME**

Eastern AH

REFERRING VET

Dr. Sole

INVOICE

16536

ULTRASONOGRAPHIC EXAMINATION OF THE ABDOMEN**Urinary System**

Urinary bladder is adequately distended with anechoic contents. No masses, inflammatory changes, echogenic sediment or cystoliths are observed. The urinary bladder, trigone and visible pelvic urethra are normal in thickness with a smooth mucosal surface.

Kidneys are overall normal in size and shape with smooth peripheral margination. A normal 1:3 cortex to medulla ratio is maintained. The medulla and cortices are uniform in texture with some mild increased cortical echogenicity and mild loss of corticomedullary distinction, expected in this age patient. There is no evidence of pyelectasia, mineral or infarcts observed. The left kidney measures 3.4 cm. The right kidney measures 3.55 cm.

Adrenal Glands

Adrenal glands are bilaterally uniformly plump egg-shaped adrenals, hypoechoic in echogenicity. This is most likely a benign age-related change. This change can be caused by chronic stress/disease, so investigation for/management of other disease (chronic kidney disease, hyperthyroidism, etc.) is recommended. The left adrenal gland measures 0.5 cm. The right adrenal gland measures 0.52 cm.

Spleen

Spleen is subjectively normal in size with a normal smooth capsular contour. Parenchyma is appropriately finely textured and homogenous with normal echogenicity relative to surrounding tissue (hyperechoic to liver). No focal nodules or masses are observed. Splenic vasculature appears normal.

Liver

Liver is subjectively normal in size with normal smooth curvilinear peripheral contour. Parenchyma is appropriately hypoechoic to the spleen in echogenicity and appropriately mildly coarse and homogenous in echotexture. A small anechoic cyst is noted, as well as an approximately 1.0 cm in diameter discrete hyperechoic nodule in the left cranial liver. Visible vasculature and biliary tree appear normal without distension or congestion.

Gallbladder is moderately distended with anechoic bile as well as suspended and gravity dependent echogenic debris. The wall is smooth without visible thickening. There is no evidence of cystic or CBD dilation. There is no evidence of effusion or inflammation. A mildly tortuous but not overly distended cystic and common bile duct noted, which is often a normal age-related variant in cats.

Gastrointestinal

The visible stomach wall is normal in thickness and layering. The lumen of the stomach is empty with no evidence of obstruction, foreign material or infiltrative disease. Pyloric outflow tract appears patent.

The visible small intestines are normal in wall thickness and layering. Small intestinal motility appears adequate (1-3 contractions per min). The lumen of the small intestine is empty with no evidence of obstruction, foreign material or infiltrative disease.

The visible colon is normal in wall thickness and layering. Contents are consistent with normal formed feces and gas.

Pancreas

Pancreas is prominent (enlarged) in size, hypoechoic to surrounding tissue and has a mildly irregular undulating contour. Parenchyma is coarse with mixed echogenic remodeling noted. Pancreatic duct dilation is noted.

Free Abdomen

Mesenteric lymph nodes are prominent in size with swollen capsular contour. Normal elongated shape (length to width ratio) is maintained. There is no loss of parenchymal detail. No free fluid present.

ULTRASONOGRAPHIC FINDINGS

Primary Findings

- Hyperechoic liver nodule, which, in a senior cat, could be consistent with a benign biliary cystadenoma. Other differentials include fibrosis or calcification caused by an old hematoma or infarct, chronic inflammation, granulomatous disease, etc. Infiltrative neoplasia or even metastatic disease can't be ruled out but is considered less likely.
- Chronic active pancreatitis

Secondary Findings

- Age-related kidney and adrenal changes
- Reactive mesenteric lymph nodes – infiltrative neoplastic disease cannot be ruled out but is considered less likely
- Gallbladder debris (feline) – Cholecystic debris is of unknown clinical significance. It can be seen with biliary stasis from fasting or illness, however, it can also be associated with hepatobiliary disease in cats and should be interpreted in combination with clinical signs such as nausea, inappetence, cranial abdominal discomfort and/or laboratory changes such as increased ALP and/or increased Tbili.

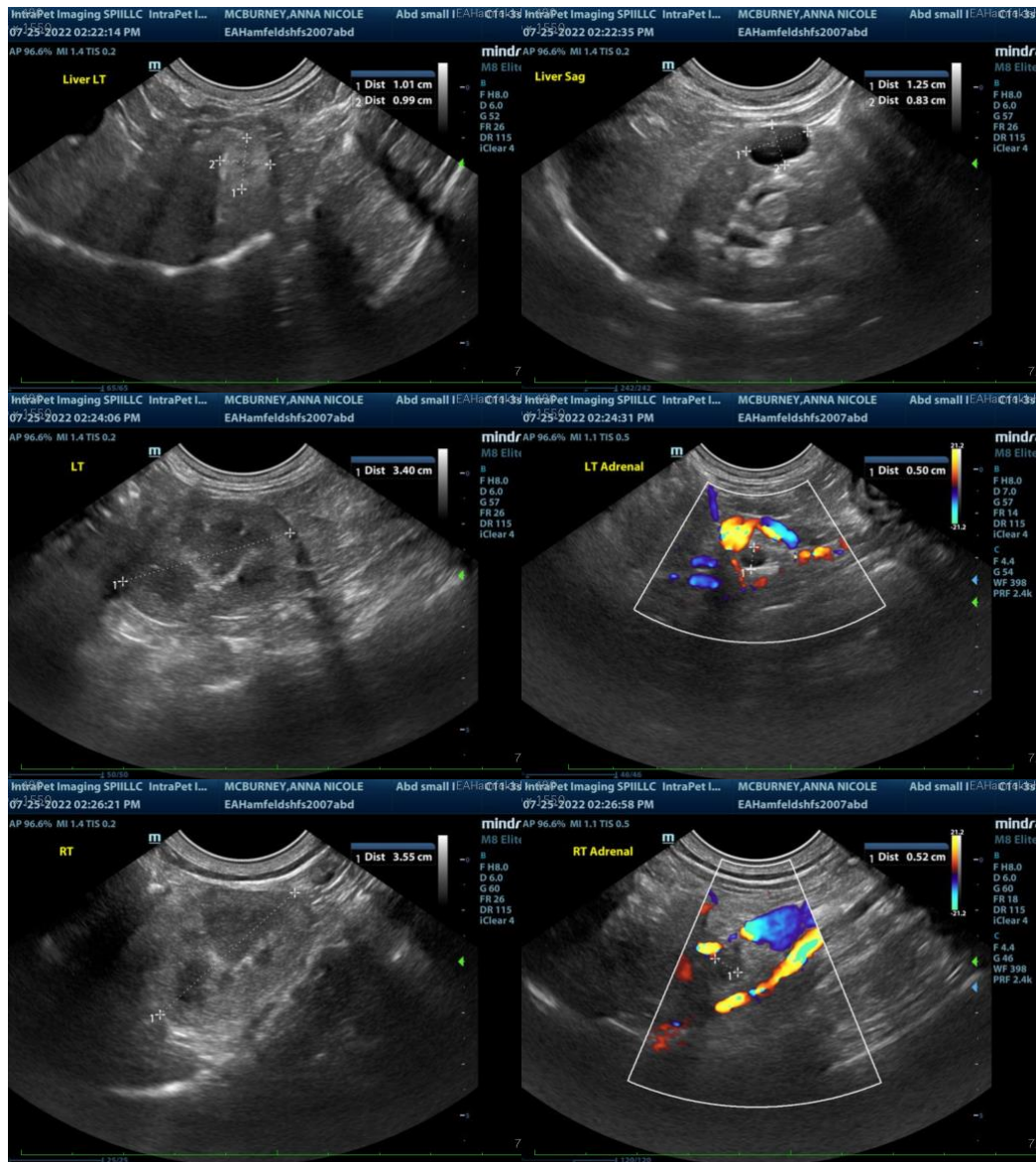
INTERPRETATION OF THE FINDINGS & FURTHER RECOMMENDATIONS

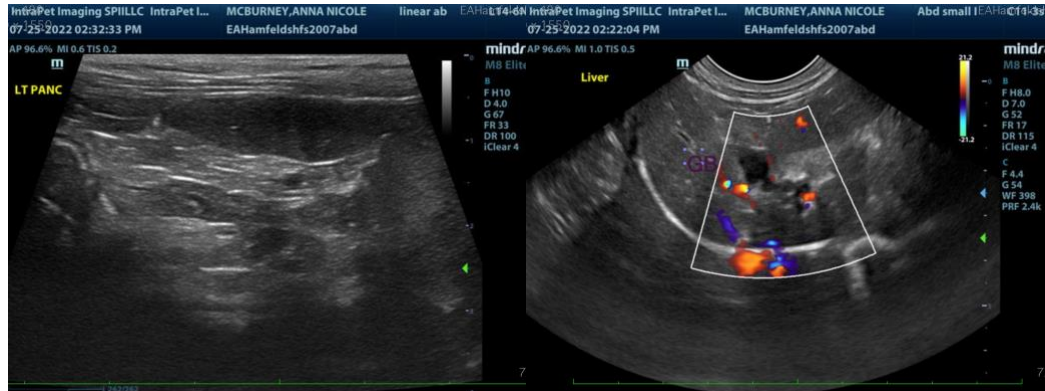
Differentials for this patient, given the reported weight loss, are to rule out diabetes mellitus, based on the reported hyperglycemia with the reportedly pending urinalysis. If the diagnosis is still questionable, a fructosamine could be considered.

Recommendations include:

- Ruling out hyperthyroidism with a T4 and free T4

- A gastrointestinal malabsorption panel (including cobalamin, folate, TLI and PLI) to Texas A&M GI Laboratory is recommended for further evaluation of GI and pancreatic function.
- If a diagnosis is not obtained, a fine needle aspirate of the liver nodule could be considered, if possible and if patients coagulation status is appropriate. Otherwise, monitoring of the liver nodule is recommended with a recheck ultrasound in 6-8 weeks.





The information and recommendations provided are based on the images presented by the referring veterinarian. No evaluation can be communicated regarding pathology that was not visible in the image/video clips provided.

Thank you for this referral. If the clinical or image interpretation does not parallel your findings or if I can be of any further assistance please contact me.

Beth Johnson, DVM DACVIM
Beth.Johnson@SonoPath.com