

IMAGING PERFORMED BY

IntraPet.com



SonoPath

Clinical Sonography & Telecytology

EDUCATIONAL TELECONSULTATION SERVICES™

1-800-838-4268 info@sonopath.com SonoPath.com

DATE PRESENTING CLINICAL SIGNS

7/22/22 Ravenous appetite, vomiting and diarrhea for the past 5 weeks, vomitous is mainly undigested food, diarrhea is liquidy, signs have persisted despite symptomatic treatment for UTI finished Thursday last week

PATIENT

Kit Kat Lisowsky

Current Medications: clavamox- 1 mL twice daily for 7 days- started 7/7 finishing on 7/14, cerenia injectable - given 7/19.

SPECIES

Feline

Lab Results: bloodwork revealed mild elevation in amylase, elevated neutrophils and monocytes, T4 normal, kidney values normal, fecal revealed no parasites present 1 week ago, urinalysis revealed UTI that was treated with antibiotics finishing 1 week ago.

Date of Previous IntraPet Ultrasound: No previous.

Sedation: Not required to complete full diagnostic ultrasound.

Stat Report: Not requested.

BREED

DSH

ULTRASONOGRAPHIC EXAMINATION OF THE ABDOMEN

SEX

Spayed Female

Urinary System

The urinary bladder is moderately distended with anechoic contents. No masses, inflammatory changes, echogenic sediment or cystoliths are observed. The urinary bladder, trigone and visible pelvic urethra are normal in thickness with a smooth mucosal surface.

AGE

7/5/07

Kidneys are bilaterally irregular and diffusely echogenic with decreased corticomedullary distinction and poor visualization of internal architecture. There is no pyelectasia noted. The left is small measured 2.95 cm. The right is compensatory and normal in size at 3.9 cm. No mineral observed on the left. A non-obstructive nephrolith is visualized on the right.

WEIGHT

5.2 Pounds

Adrenal Glands

Adrenal glands are bilaterally uniformly plump egg-shaped adrenals (left measures 0.48 cm, right measures 0.64 cm), hypoechoic in echogenicity with bilateral dystrophic mineralization noted. This is most likely a benign age-related change. This change can be caused by chronic stress/disease, so investigation for/management of other disease (chronic kidney disease, hyperthyroidism, etc.) is recommended.

INTERPRETED BY

Beth Johnson, DVM
DACVIM

Spleen

The spleen is subjectively normal in size with a normal smooth capsular contour. Parenchyma is appropriately finely textured and homogenous with normal echogenicity relative to surrounding tissue (hyperechoic to liver). Two approximately 0.5 cm sized, discrete, hypoechoic nodules are noted that result in capsular bulge. Splenic vasculature appears normal.

IMAGING PERFORMED BY

Stephanie Pearce
RDCS, RVT

Liver

The liver is subjectively normal in size with normal smooth curvilinear peripheral contour. Parenchyma is appropriately hypoechoic to the spleen in echogenicity and appropriately mildly coarse and homogenous in echotexture. No focal lesions are observed. Visible vasculature and biliary tree appear normal without distension or congestion.

HOSPITAL NAME

Homeward Bound VS

REFERRING VET

Dr. Williams

Gallbladder is moderately distended with anechoic bile as well as suspended and gravity dependent echogenic debris. The wall is smooth without visible thickening. There is no evidence of cystic or CBD dilation. There is no evidence of effusion or inflammation.

INVOICE

39784

Gastrointestinal

The stomach wall is normal in thickness (canine < 0.5 cm and feline < 0.4 cm) and layering. The lumen of the stomach is mildly fluid distended with no evidence of obstruction, foreign material or infiltrative disease. Pyloric outflow tract appears patent.

The visible small intestine demonstrates areas of thick muscularis layer relative to mucosa (disruption of the normal 1:3 muscularis:mucosa ratio). Small intestinal submucosa is slightly irregular, thick and hyperechoic, without evident loss of layering appreciated. The lumen is empty with no evidence of obstruction or foreign material.

The colon is diffusely markedly thickened, measuring 0.4-0.5 cm with an early emerging loss of layering noted in some areas. Contents are consistent with normal formed feces and gas.

Pancreas

The observed pancreas appears appropriately isoechoic to surrounding omental fat. The capsule is mildly irregular in shape. Parenchyma is mildly heterogenous and coarse. There is no visible pancreatic duct dilation. There is no evidence of active peripancreatic inflammation.

Free Abdomen

There is a scant amount of anechoic free fluid between liver lobes.

Mesenteric lymph nodes are enlarged with swollen irregular capsular contour and loss of normal length to width ratio (rounded in shape). Nodes are hypoechoic with loss of normal parenchymal detail.

PRIMARY FINDINGS

- **Hypoechoic splenic nodules** – concerning for infiltrative neoplasia such as round cell neoplasia, given the concurrent findings. Benign lesions such as cysts, hematomas, nodular hyperplasia, extramedullary hematopoiesis, etc. cannot be ruled out but are considered less likely.
- **Gastrointestinal lymphoma suspect pattern** – This finding is most prominent in the colon.
- **Aggressive lymph nodes** – most consistent with infiltrative round cell or metastatic neoplasia. A benign aggressive inflammatory response cannot be ruled out without tissue sampling +/- culture.

SECONDARY FINDINGS

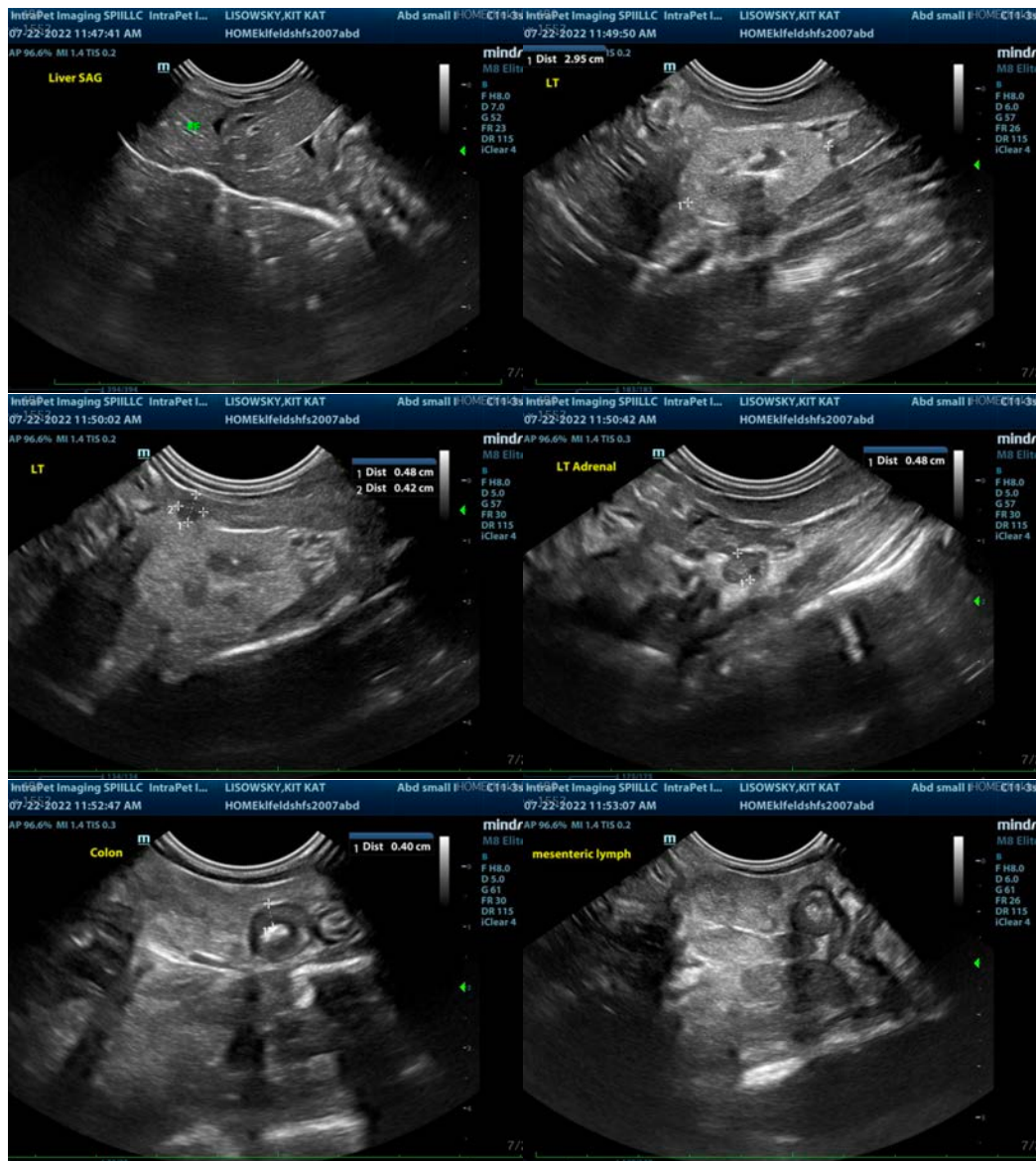
- **Chronic Kidney Disease with non-obstructive nephrolith in the right** – This appearance of the kidneys is consistent with chronic kidney disease such as chronic glomerular or interstitial nephritis, chronic pyelonephritis, etc.
- **Age related adrenal changes**
- **Pancreatic age-related remodeling** – Mild irregularities are consistent with benign age-related change. Low-grade smoldering chronic pancreatitis cannot be ruled out and should be suspected in the face of appropriate clinical signs.
- **Gallbladder debris** - Cholecystic debris is of unknown clinical significance. It can be seen with biliary stasis from fasting or illness, however, it can also be associated with hepatobiliary disease in cats and should be interpreted in combination with clinical signs such as nausea, inappetence, cranial abdominal discomfort and/or laboratory changes such as increased ALP and/or increased Tbili.

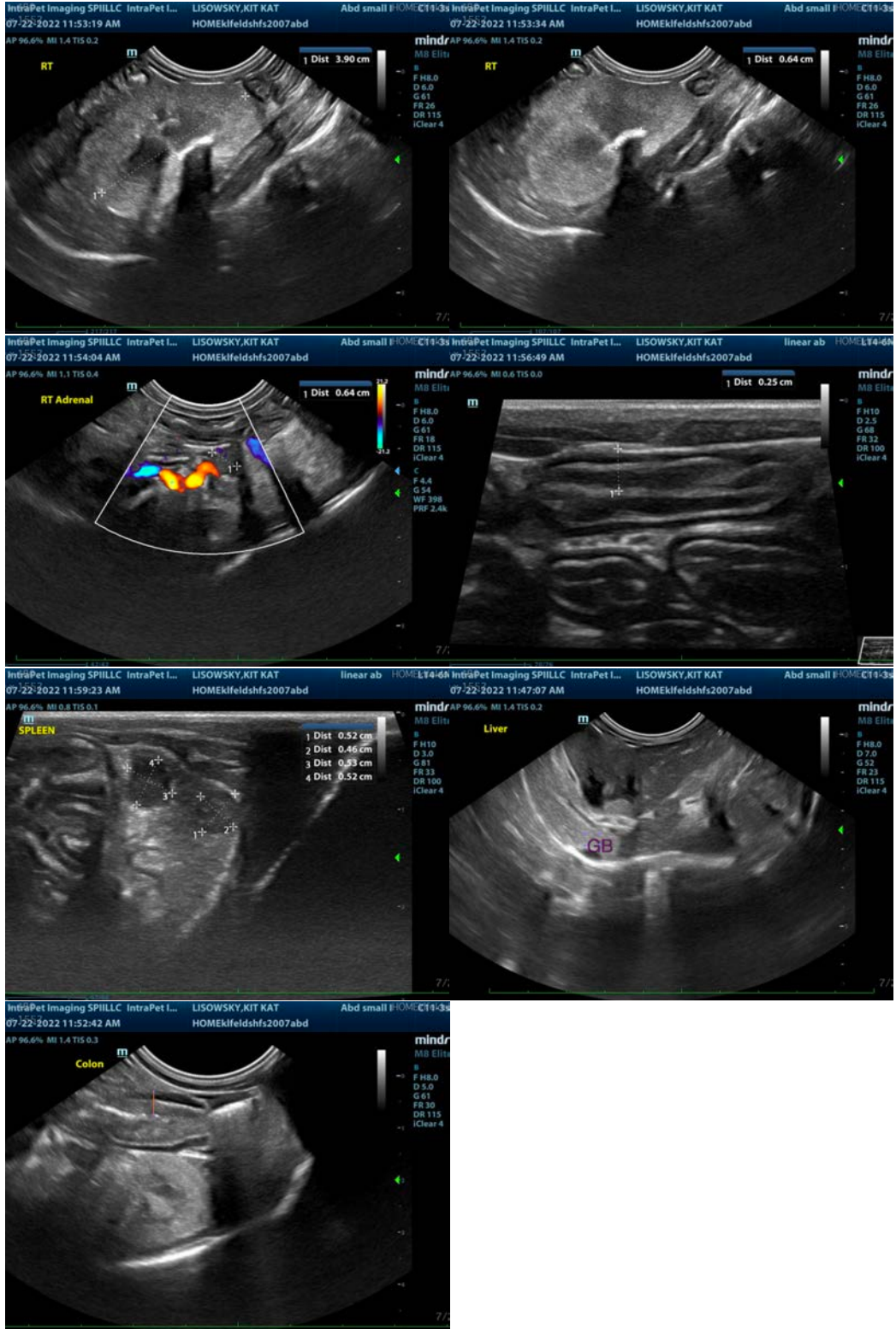
INTERPRETATION OF THE FINDINGS & FURTHER RECOMMENDATIONS

Recommendations include:

- Fine needle aspirate of a mesenteric lymph node, splenic nodules if possible, and potentially even the colonic wall, if possible, and if patient's coagulation status is appropriate.

- A gastrointestinal malabsorption panel (including cobalamin, folate, TLI and PLI) to Texas A&M GI Laboratory is recommended for further evaluation of GI and pancreatic function.
- If a round cell neoplasia diagnosis, which is suspected, is not diagnosed cytologically, biopsies of the gastrointestinal tract, being sure to include a colonoscopy, as well as the ileum, if possible, may be required to definitively diagnose and therefore manage this patient's infiltrative bowel disease.





The information and recommendations provided are based on the images presented by the referring veterinarian/sonographer. No evaluation can be communicated regarding pathology that was not visible in the image/video clips provided.

Thank you for this referral. If the clinical or image interpretation does not parallel your findings or if I can be of any further assistance please contact me.

Beth Johnson, DVM, DACVIM
Beth.Johnson@sonopath.com