

**DATE PRESENTING CLINICAL SIGNS**

7/20/22

Being treated at Falls Road Animal Hospital Since May 2022 with subcutaneous fluids and aluminum hydroxide for kidney disease with worsening azotemia (unclear of suspected differentials from notes sent). Owner presented for second opinion; records were unable to be obtained until after exam. Owner has noted pu/pd at home, but PJ is otherwise BAR, e/d well with no other abnormalities.

PATIENT

PJ Bagan

SPECIES

Canine

BREED

Shih Tzu

SEX

Neutered Male

AGE

6/27/07

WEIGHT

15.2 Pounds

INTERPRETED BYBeth Johnson, DVM
DACVIM**IMAGING PERFORMED BY**

Rachel Brillhart RDMS

HOSPITAL NAME

Stevenson Village VH

REFERRING VET

Dr. Rathbun

INVOICE

39703

Current Medications: -150 mL SQ LRS 3-5 days a week, Aluminum hydroxide - exact dose not noted in referral notes or recalled by Owner; appears to have been prescribed on 6/24/22.

Lab Results: At Falls Road Animal Hospital: Chemistry panel on 5/23/22:

elevated creatinine 2.7 mg/dL (0.5-1.8) and BUN 40 mg/dL (7-27)

Chemistry panel on 6/20/22: elevated creatinine 5.6 mg/dL (0.5-1.8) and BUN 89 mg/dL (7-27),

hypoglycemia 32 mg/dL (70-143) -No evidence of recheck of BG noted. Radiographs: 7/5/22 (done at SVVH):

Abdominal radiographs: left kidney appears mild-moderately enlarged (~6.4 x 4.6 cm) and has few focal regions of very faint increased radiopacity (possible mineralization); small amount of gas throughout the intestines; liver appears WNL, spleen appears WNL, apparent thickening of the wall of the body of the stomach on vd (not apparent on lateral view; r/o -possible overlap of the liver) -Brief US of kidneys: loss of corticomedullary distinction of the right kidney; suspected mass within the left kidney adjacent to and extending into the renal pelvis; irregular borders of the renal pelvis with thinning of the renal cortex and irregular margins of the medulla.

Date of Previous IntraPet Ultrasound: No previous.

Sedation: Not required to complete full diagnostic ultrasound.

Stat Report: Not requested.

ULTRASONOGRAPHIC EXAMINATION OF THE ABDOMEN**Urinary System**

The urinary bladder is moderately distended with anechoic contents. No masses or inflammatory changes. A small, gravity dependent, mineral non-shadowing focus consistent with accumulated sand and/or small cystoliths is present. The urinary bladder, trigone and visible pelvic urethra are normal in thickness with a smooth mucosal surface.

The area of the prostate is examined without evident pathology.

Multiple cortical anechoic cysts of various sizes are present in both kidneys. Overall echogenicity is increased (hyperechoic cortex) as the result of acoustic enhancement from the cysts and kidney shape is distorted. The left kidney measures 5.48 cm with a large cyst on the caudal pole that measures approximately 3.0 cm and contains an echogenic appearing fluid. The right kidney measures 5.8 cm and contains a caudal pole cyst of approximately 4.0 cm with a similar appearing echogenic fluid. Neither large cyst has evidence of vascular invasion. Mild bilateral pyelectasia is present and decreased corticomedullary distinction is noted bilaterally. No mineral is observed.

Adrenal Glands

The right adrenal gland is normal in size (2.47 cm long x 0.95 cm at the cranial pole and 0.82 cm at the caudal pole), shape and contour. Corticomedullary structure is unremarkable. Visible surrounding vasculature appears normal.

The left adrenal gland is normal in size (2.3 cm long x 0.71 cm at the cranial pole and 1.0 cm at the caudal pole), shape and contour. Corticomedullary structure is unremarkable. Visible surrounding vasculature appears normal.

Spleen

The spleen is subjectively normal in size with a normal smooth capsular contour. Parenchyma is appropriately finely textured and homogenous with normal echogenicity relative to surrounding tissue (hyperechoic to liver). No focal nodules or masses are observed. Splenic vasculature appears normal.

Liver

Liver is subjectively enlarged with mildly irregular margins. Parenchyma is heterogenous characterized by multiple poorly defined hypoechoic nodules within otherwise hyperechoic liver parenchyma. Visible vasculature and biliary tree appear normal without distension or congestion.

The gallbladder is non-distended in size. The wall is smooth without visible thickening. Luminal contents are primarily anechoic. There is no evidence of cystic or common bile duct dilation.

Gastrointestinal

The visible stomach wall is normal in thickness and layering. The lumen of the stomach is mildly distended with echogenic non-shadowing luminal contents and gas consistent with normal ingesta. There is no evidence of obstruction, foreign material or infiltrative disease. Pyloric outflow tract appears patent.

The visible small intestines are normal in wall thickness and layering (canine duodenum < 0.5 cm and feline duodenum < 0.4 cm; other < 0.3 cm). Small intestinal motility appears adequate (1-3 contractions per min). The lumen of the small intestine is empty with no evidence of obstruction, foreign material or infiltrative disease.

The visible colon is normal in wall thickness (< 0.2 cm) and layering. Contents are consistent with normal formed feces and gas.

Pancreas

The pancreatic parenchyma is appropriately isoechoic to surrounding tissue. Visible capsule is smooth and normal in contour. There is no visible pancreatic duct dilation. There is no evidence of active peripancreatic inflammation.

Free Abdomen

There is no evidence of free peritoneal effusion noted in these images.

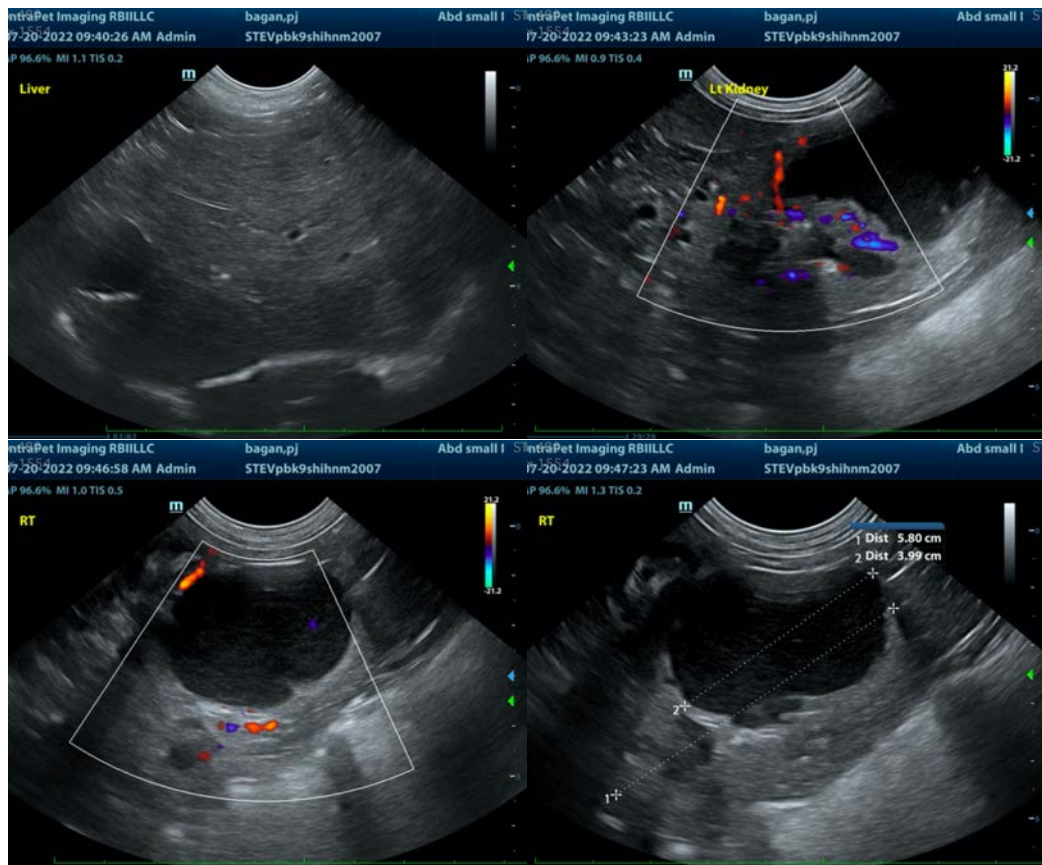
There is no apparent lymphadenopathy noted in these images.

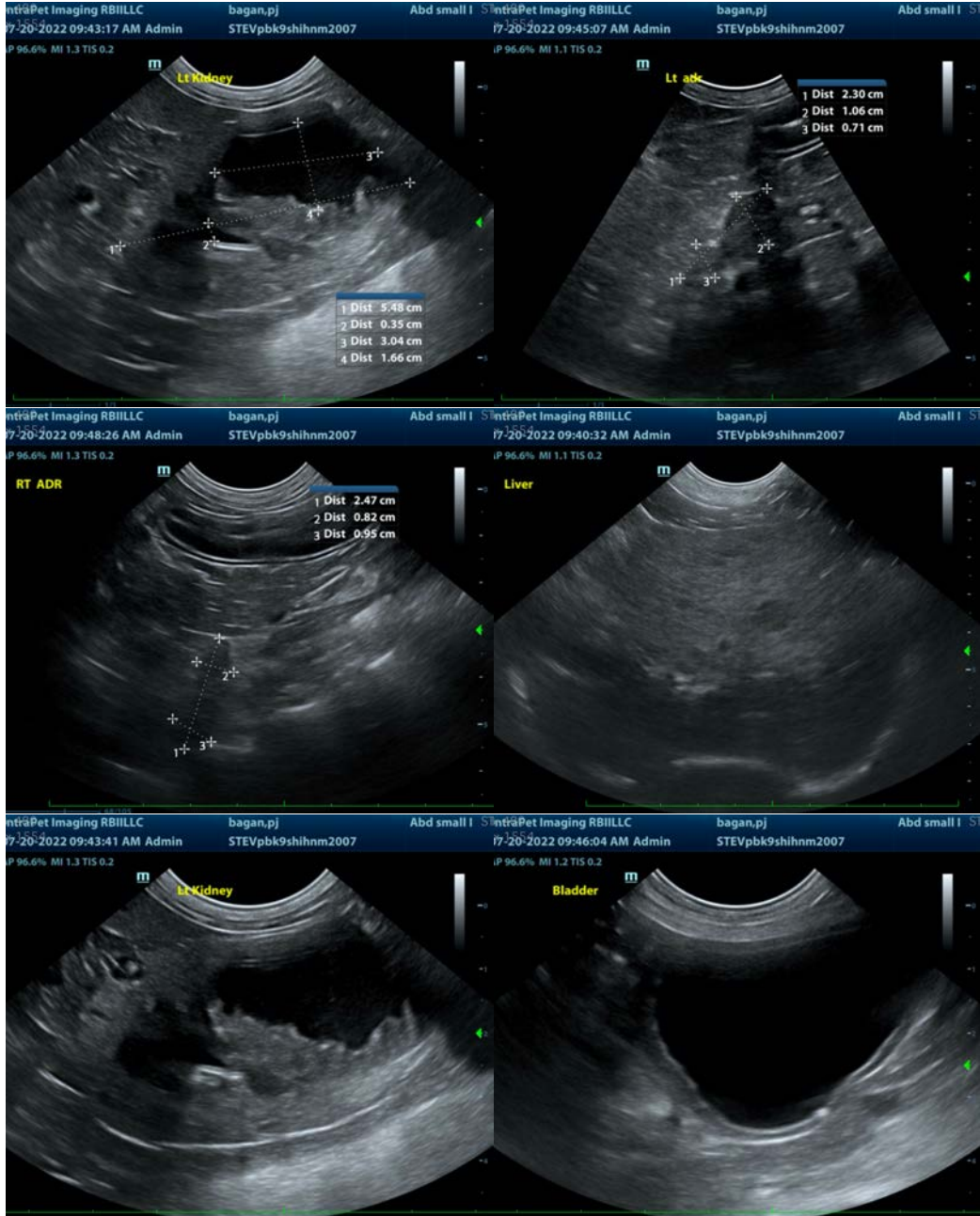
ULTRASONOGRAPHIC FINDINGS

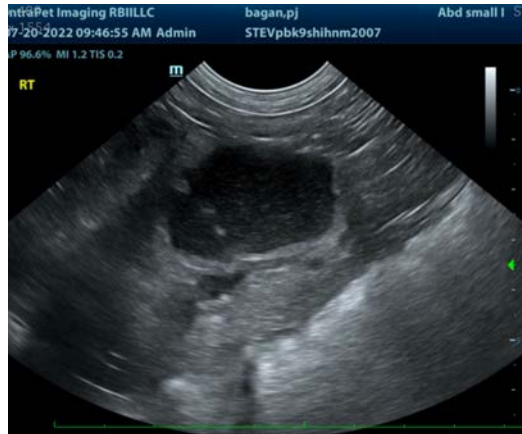- **Polycystic kidneys** - The appearance of the kidneys is consistent with chronic kidney disease, such as chronic glomerular or interstitial nephritis, chronic pyelonephritis, etc., with concurrent polycystic disease. Given the appearance of the echogenic fluid within the largest cysts bilaterally, complicated or infected cysts could be present. Infiltrative neoplasia is possible, but considered much less likely, given the bilateral symmetry, lack of blood flow, etc.
- **Small urinary bladder cystoliths**
- **Heterogenous Liver** - These changes are most consistent with benign processes such as nodular hyperplasia, steroid (vacuolar) hepatopathy, extramedullary hematopoiesis or possibly chronic inflammatory disease and less commonly infiltrative round cell or metastatic neoplasia.

INTERPRETATION OF THE FINDINGS & FURTHER RECOMMENDATIONS

- Given this patient's kidney disease, urinalysis and, if indicated based on urinalysis results, urine culture are recommended. If protein is present in an otherwise quiet sediment, protein quantification with a urine protein to creatinine ration is recommended.
- Blood pressure is recommended if not recently evaluated.
- Given the acute increase in azotemia combined with the reported PU/PD, testing for Leptospirosis could be considered, just to rule out as a contributing factor.
- A fine needle aspirate of the bilateral renal cysts for both cytology and culture could be considered, if patient's coagulation status is appropriate and it is deemed safe to do so.
- In the meantime, continued medical management of chronic kidney disease with diet, blood pressure and/or proteinuria management, if indicated based on results, fluid therapy if necessary, symptomatic care as needed, and a course of broad-spectrum antibiotics could be considered.







The information and recommendations provided are based on the images presented by the referring veterinarian/sonographer. No evaluation can be communicated regarding pathology that was not visible in the image/video clips provided.

Thank you for this referral. If the clinical or image interpretation does not parallel your findings or if I can be of any further assistance please contact me.

Beth Johnson, DVM, DACVIM
Beth.Johnson@sonopath.com