SonoPath
Clinical Sonography & Telecytology

EDUCATIONAL TELECONSULTATION SERVICES™

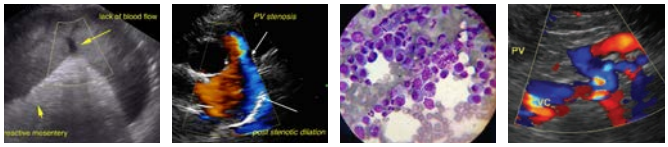

SonoPath.com™
1-800-838-4268 info@sonopath.com

PATIENT
Oakley Maley

SPECIES
Canine

BREED
Golden Retriever

SEX
Neutered Male

AGE
5

WEIGHT
27.8 kg

INTERPRETED BY
Beth Johnson, DVM DACVIM

IMAGING PERFORMED BY
Dr. Laura de Cordon

HOSPITAL NAME
Mason Dixon Animal Emergency Hospital

REFERRING VET
Dr. Laura de Cordon

INVOICE
43690

DATE
7/2/23

PRESENTING CLINICAL SIGNS

Lethargic, decreased appetite (very unusual). Episodes of vomiting started on Thursday (undigested food). Loose stools, owner noticed blood in stool starting yesterday continuing today. Symptoms started Weds, took to RDVM on Friday. Got into ear buds, hand lotion, lip balm in bedroom on Wednesday (known to eat anything and everything). Also has access to large yard/field where he runs free.

Abdomen X-Rays: there some gas and fluid within the stomach, prominent rugae folds. There is some heterogeneous material within SI with some gas present. Gas within colon. Possible bunchiness on caudal abdomen? Liver and spleen are WNL CBC- LYM: 0.61 PLT: 61 CHEM/LYTES- Gluc: 128 K: 3.4 PCV/TS: 40/7.3

ULTRASONOGRAPHIC EXAMINATION OF THE ABDOMEN

Urinary System

The urinary bladder is moderately distended with anechoic contents. No masses, inflammatory changes, echogenic sediment or cystoliths are observed. The urinary bladder, trigone and visible pelvic urethra are normal in thickness with a smooth mucosal surface.

Prostate is normal in size, echotexture and echogenicity for a neutered male.

The right kidney is normal in size (6.34 cm), shape and echogenicity. It has smooth peripheral margination. There is a normal 1:3 cortex to medulla ratio with appropriate corticomedullary distinction. There is no evidence of pyelectasia, mineral or infarcts observed.

The left kidney is normal in size (6.46 cm), shape and echogenicity. It has smooth peripheral margination. There is a normal 1:3 cortex to medulla ratio with appropriate corticomedullary distinction. There is no evidence of pyelectasia, mineral or infarcts observed.

Adrenal Glands

The right adrenal gland is unable to be well visualized in these images.

The left adrenal gland is normal in size (0.38 cm at the cranial pole and 0.46 cm at the caudal pole), shape and contour. Corticomedullary structure is unremarkable. Visible surrounding vasculature appears normal.

Spleen

The spleen is subjectively normal in size with a normal smooth capsular contour. Parenchyma is appropriately finely textured and homogenous with normal echogenicity relative to surrounding tissue (hyperechoic to liver). No focal nodules or masses are observed. Splenic vasculature appears normal.

Liver

The liver is subjectively normal in size with normal smooth curvilinear peripheral contour. Parenchyma is appropriately hypoechoic to the spleen in echogenicity and appropriately mildly coarse and homogenous in echotexture. No focal lesions are observed. Visible vasculature and biliary tree appear normal without distension or congestion.

The gallbladder is non-distended in size. The wall is smooth without visible thickening. Luminal contents are primarily anechoic. There is no evidence of cystic or common bile duct dilation.

SonoPath
Clinical Sonography & Telecytology
EDUCATIONAL TELECONSULTATION SERVICES™

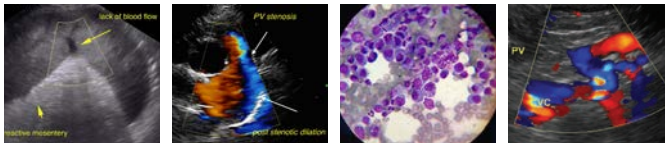

SonoPath.com™
1-800-838-4268 info@sonopath.com

PATIENT
Oakley Maley

SPECIES
Canine

BREED
Golden Retriever

SEX
Neutered Male

AGE
5

WEIGHT
27.8 kg

INTERPRETED BY
Beth Johnson, DVM DACVIM

IMAGING PERFORMED BY
Dr. Laura de Cordon

HOSPITAL NAME
Mason Dixon Animal Emergency Hospital

REFERRING VET
Dr. Laura de Cordon

INVOICE
43690

DATE
7/2/23

Gastrointestinal

The visible stomach wall is normal in thickness and layering. The lumen of the stomach is mildly distended with echogenic non-shadowing luminal contents and gas consistent with normal ingesta. There is no evidence of distention, obstruction, or infiltrative disease. Pyloric outflow tract appears patent. Having said that, in one view there is a subtle echogenic interface with some subtle acoustic shadow that is more consistent in appearance with gas, but non-obstructive foreign material can't be definitively ruled out.

The visible small intestines are normal in wall thickness and layering (canine duodenum < 0.5 cm and feline duodenum < 0.4 cm; other < 0.3 cm). Small intestinal motility appears adequate (1-3 contractions per min). The lumen of the small intestine is empty with no evidence of obstruction, foreign material or infiltrative disease.

The visible colon is normal in wall thickness (< 0.2 cm) and layering. Contents are consistent with normal formed feces and gas.

Pancreas

The pancreatic parenchyma is appropriately isoechoic to surrounding tissue. Visible capsule is smooth and normal in contour. There is no visible pancreatic duct dilation. There is no evidence of active peripancreatic inflammation.

Free Abdomen

There is no evidence of free peritoneal effusion noted in these images.

The mesenteric lymph nodes are prominent in size with swollen capsular contour. Normal elongated shape (length to width ratio) is maintained. There is no loss of parenchymal detail.

ULTRASONOGRAPHIC FINDINGS

- The stomach contains some ingesta and one area of subtle shadowing that is more consistent with gas. There is no evidence of distention or obstruction, but non-obstructive foreign material can't be definitively ruled out. There is no evidence of plication or an obstructive pattern involving the small bowel present in these images.

INTERPRETATION OF THE FINDINGS & FURTHER RECOMMENDATIONS

If these gastrointestinal signs are acute in nature, recommendations include supportive/symptomatic medical management of possible gastroenteritis/dietary indiscretion, given this patient's history. If gastrointestinal signs are chronic or intermittent, further evaluation of digestion and absorption could be considered, beginning with a fecal exam if not recently evaluated.

A baseline cortisol is recommended. If baseline cortisol is less than 2, a full ACTH stimulation test is recommended to rule out hypoadrenocorticism.

A gastrointestinal malabsorption panel (including cobalamin, folate, TLI and PLI) to Texas A&M GI Laboratory is recommended for further evaluation of GI and pancreatic function.

Regardless, empirical deworming with a 5-day course of Panacur should be considered.

If vomiting persists, recheck imaging may be warranted to help monitor resolution versus progression of the gastric contents, etc.

SonoPath

Clinical Sonography & Telecytology

EDUCATIONAL TELECONSULTATION SERVICES™

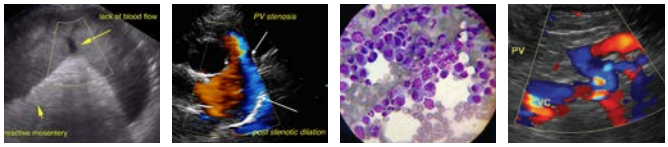

SonoPath.com™

1-800-838-4268 info@sonopath.com

PATIENT

Oakley Maley

SPECIES

Canine

BREED

Golden Retriever

SEX

Neutered Male

AGE

5

WEIGHT

27.8 kg

INTERPRETED BY

Beth Johnson, DVM
DACVIM

IMAGING PERFORMED BY

Dr. Laura de Cordon

HOSPITAL NAME

Mason Dixon Animal Emergency Hospital

REFERRING VET

Dr. Laura de Cordon

INVOICE

43690

DATE

7/2/23

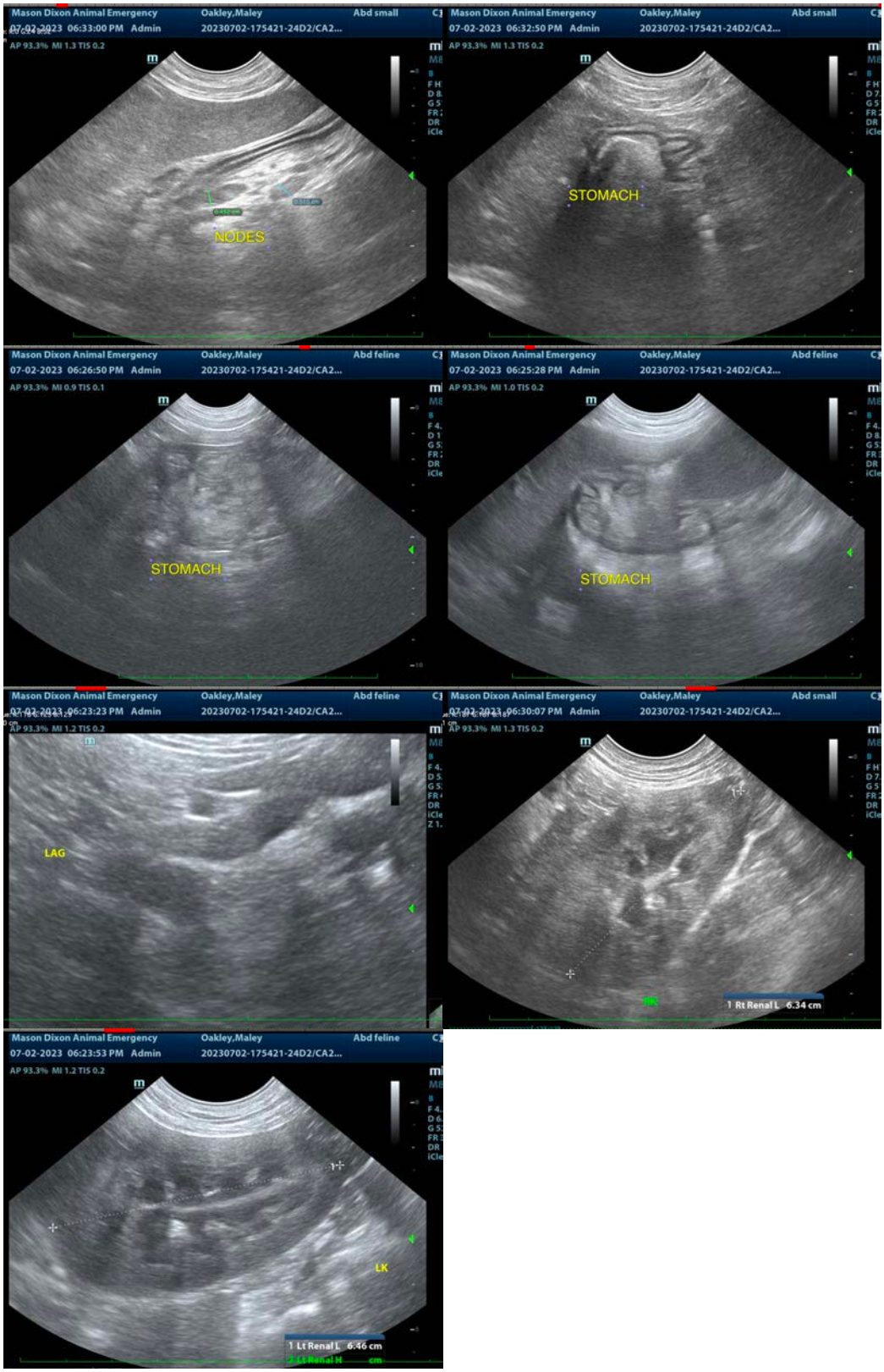

SonoPath
Clinical Sonography & Telecytology

EDUCATIONAL TELECONSULTATION SERVICES™

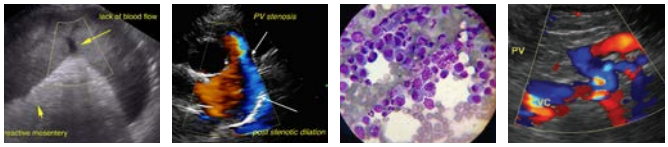

SonoPath.com™
1-800-838-4268 info@sonopath.com

PATIENT

Oakley Maley

SPECIES

Canine

BREED

Golden Retriever

SEX

Neutered Male

AGE

5

WEIGHT

27.8 kg

INTERPRETED BY

Beth Johnson, DVM
DACVIM

IMAGING PERFORMED BY

Dr. Laura de Cordon

HOSPITAL NAME

Mason Dixon Animal Emergency Hospital

REFERRING VET

Dr. Laura de Cordon

INVOICE

43690

DATE

7/2/23

The information and recommendations provided are based on the images presented by the referring veterinarian/sonographer. No evaluation can be communicated regarding pathology that was not visible in the image/video clips provided.

Thank you for this referral. If the clinical or image interpretation does not parallel your findings or if I can be of any further assistance please contact me.

Beth Johnson, DVM, DACVIM
info@sonopath.com