**DATE**

7/20/22

PRESENTING CLINICAL SIGNS

Recurrent episodes of vomiting for the past 6 months. Seen at urgent care facility for last bout and bloodwork/rads performed (will attach). Currently feeding hydrolyzed diet with a slight improvement. Bouts usually last 2-3 weeks and are accompanied by lethargy and abdominal pain.

PATIENT

Montag Davis

Current Medications: buprenorphine 0.12mg bid from 7/13-7/18
cerenia 16mg 1/2 sid since 7/13.

Lab Results: mildly low potassium. otherwise normal.

Date of Previous IntraPet Ultrasound: No previous.

Sedation: Not required to complete full diagnostic ultrasound.

Stat Report: Not requested.

Imaging Performed By: Rachel Brillhart, RDMS.

SPECIES

Feline

BREED

Siamese

ULTRASONOGRAPHIC EXAMINATION OF THE ABDOMEN**Urinary System**

Urinary bladder is adequately distended with anechoic contents. No masses, inflammatory changes, echogenic sediment or cystoliths are observed. The urinary bladder, trigone and visible pelvic urethra are normal in thickness with a smooth mucosal surface.

SEX

Neutered male

Left kidney is normal is size (3.81 cm), shape and echogenicity. It has smooth peripheral margination. There is a normal 1:3 cortex to medulla ratio with appropriate corticomedullary distinction. A hyperechoic band parallel to the corticomedullary border is present. There is no evidence of pyelectasia, mineral or infarcts observed.

AGE

2020

WEIGHT

9.43 lbs

Right kidney is normal is size (3.94 cm), shape and echogenicity. It has smooth peripheral margination. There is a normal 1:3 cortex to medulla ratio with appropriate corticomedullary distinction. A hyperechoic band parallel to the corticomedullary border is present. There is no evidence of pyelectasia, mineral or infarcts observed.

INTERPRETED BYBeth Johnson, DVM
DACVIM**Adrenal Glands**

Left adrenal gland is normal in size (0.29 cm), shape and overall architecture, echogenicity and echotexture. Visible surrounding vasculature appears normal.

HOSPITAL NAME

Stevenson Village VH

Right adrenal gland is normal in size (0.39 cm), shape and overall architecture, echogenicity and echotexture. Visible surrounding vasculature appears normal.

REFERRING VET

Dr. Feinberg

Spleen

Spleen is subjectively normal in size with a normal smooth capsular contour. Parenchyma is appropriately finely textured and homogenous with normal echogenicity relative to surrounding tissue (hyperechoic to liver). No focal nodules or masses are observed. Splenic vasculature appears normal.

INVOICE

31831

Liver

Liver is subjectively normal in size with normal smooth curvilinear peripheral contour. Parenchyma is appropriately hypoechoic to the spleen in echogenicity and appropriately mildly coarse and homogenous in echotexture. No focal lesions are observed. Visible vasculature and biliary tree appear normal without distension or congestion.

Gallbladder is non-distended in size. The wall is smooth without visible thickening. Luminal contents are primarily anechoic. There is no evidence of cystic or common bile duct dilation.

Gastrointestinal

The visible stomach wall is normal in thickness and layering. The lumen of the stomach is empty with no evidence of obstruction, foreign material or infiltrative disease. Pyloric outflow tract appears patent.

The visible small intestine demonstrates occasional areas of thick muscularis layer relative to mucosa (disruption of the normal 1:3 muscularis:mucosa ratio). Small intestinal submucosa is slightly irregular, thick and hyperechoic, without evident loss of layering appreciated. The lumen of the small intestine is empty with no evidence of obstruction or foreign material.

The visible colon is normal in wall thickness (< 0.2 cm) and layering. Contents are consistent with normal formed feces and gas.

Pancreas

Pancreas is prominent (enlarged) in size, hypoechoic to surrounding tissue and has a mildly irregular undulating contour. Parenchyma is coarse with mixed echogenic remodeling noted. Pancreatic duct dilation is noted.

Free Abdomen

There is no evidence of free peritoneal effusion noted in these images.

Lymph nodes are prominent in size with swollen capsular contour. Normal elongated shape (length to width ratio) is maintained. There is no loss of parenchymal detail.

ULTRASONOGRAPHIC FINDINGS

Primary Findings

IBD GI Pattern. Thick muscularis has been reported with infiltrative bowel disease including both benign inflammatory disease as well as infiltrative neoplasia such as lymphoma. No aggressive lymphadenopathy, loss of layering, etc. is noted to make lymphoma more probable, but lymphoma cannot be definitively ruled out without tissue sampling.

Chronic active pancreatitis.

Reactive mesenteric lymphadenopathy.

Bilateral

Medullary rim sign - This finding is of unknown clinical significance and can be a normal variant, often idiopathic. Medullary rim sign can be present with renal disease including FIP, lymphoma, hypercalcemic nephropathy, Leptospirosis, tubular disease, other and should be interpreted in combination with other more specific indications of kidney disease such as isosthenuria, proteinuria, azotemia, etc. This is a common incidental finding in patients with diabetes mellitus.

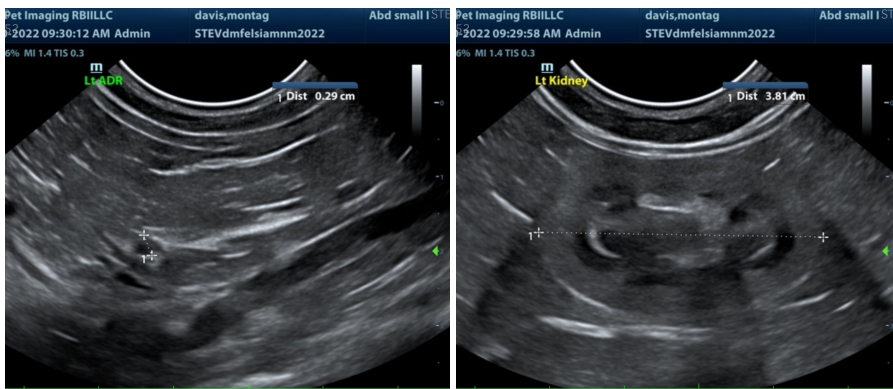
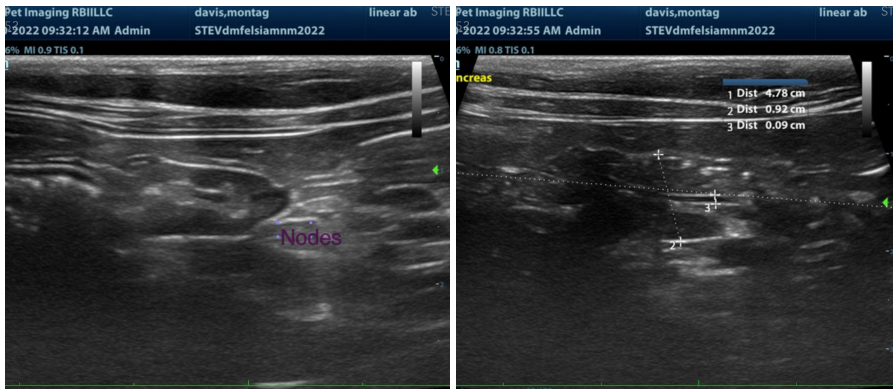
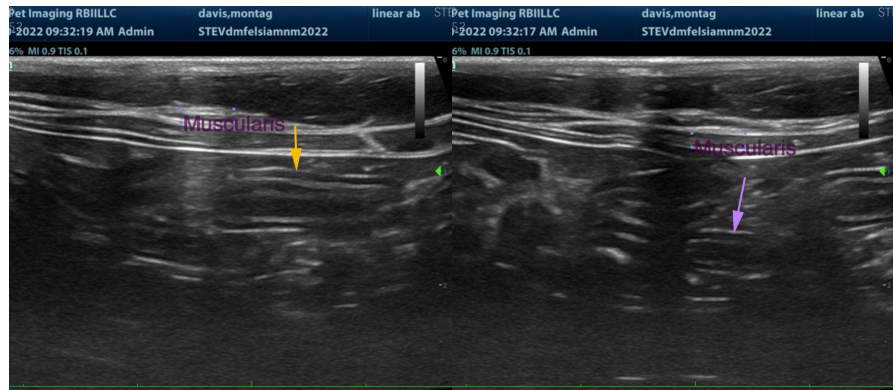
INTERPRETATION OF THE FINDINGS & FURTHER RECOMMENDATIONS

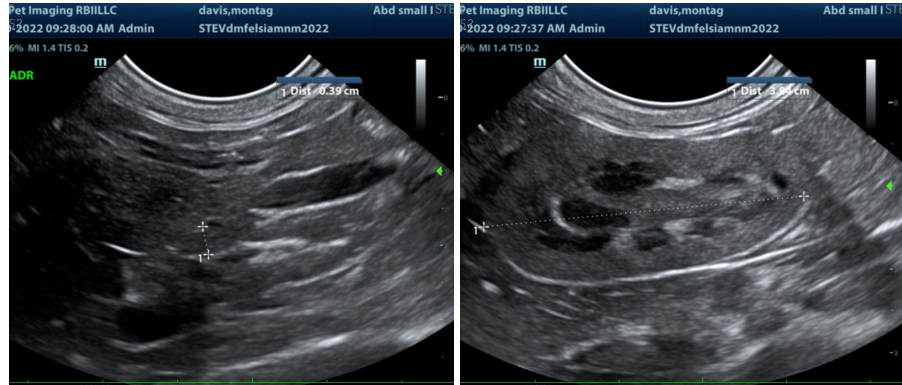
A gastrointestinal malabsorption panel (including cobalamin, folate, TLI and PLI) to Texas A&M GI Laboratory is recommended for further evaluation of GI and pancreatic function.

Ideally, biopsies of the GI tract, being sure to include ileum if possible, are recommended to definitively diagnose and therefore manage the infiltrative bowel disease.

If biopsies cannot be obtained, empirical therapies could include diet change, empirical deworming with a 5 day course of Panacur, cobalamin supplementation (unless cobalamin level is evaluated and supplementation is not warranted) and prednisolone (if not contraindicated based on patient contraindications, co-morbidities, etc.).

Given the patient's young age and partial response to a hydrolyzed protein diet other empirical therapies to potentially consider if a conservative approach is elected prior to biopsies include empirical deworming with a 5 day course of Panacur and transition to a different novel or hydrolyzed protein diet as some patients respond better to one versus the other and/or stop responding to one and need a transition to another.





The information and recommendations provided are based on the images presented by the referring veterinarian. No evaluation can be communicated regarding pathology that was not visible in the image/video clips provided.

Thank you for this referral. If the clinical or image interpretation does not parallel your findings or if I can be of any further assistance please contact me.

Beth Johnson, DVM DACVIM
Beth.Johnson@SonoPath.com