

**DATE PRESENTING CLINICAL SIGNS**

7/19/22 Ate last night did not eat this am. Started urinating blood. No known toxins but was eating something that was in the front yard a few days ago. Seen by RDVM BW, U/A and xrays done.

**PATIENT**

Molly Lekin  
 Current Medications: None listed.  
 Date of Previous IntraPet Ultrasound: No previous.  
 Sedation: Not required to complete full diagnostic ultrasound.  
 Stat Report: Not requested.

**SPECIES**

Canine

**ULTRASONOGRAPHIC EXAMINATION OF THE ABDOMEN****BREED**

Labrador X

**SEX**

Spayed Female

**AGE**

7/19/14

**WEIGHT**

71.1 Pounds

**INTERPRETED BY**

Beth Johnson, DVM  
 DACVIM

**IMAGING PERFORMED BY**

Rachel Brilhart RDMS

**HOSPITAL NAME**

Animal Emergency  
 Hospital

**REFERRING VET**

Dr. Ruby

**INVOICE**

39668

**Urinary System**

Urinary bladder is adequately distended with primarily echogenic fluid and large amounts of amorphous, non-shadowing debris. The entire urinary bladder wall, including at the level of the trigone and extending into the proximal urethra as far as can be followed, is markedly thickened, measuring between 0.60-1.0 cm. Mucosa is hyperechoic and irregular. No masses or cystoliths are observed. The tissue around the trigone and proximal urethra is hyperechoic/enhanced in appearance.

The right kidney is normal in size (6.91 cm), shape and echogenicity. It has smooth peripheral margination. There is a normal 1:3 cortex to medulla ratio with appropriate corticomedullary distinction. There is no evidence of pyelectasia, mineral or infarcts observed.

The left kidney is normal in size (5.79 cm), shape and echogenicity. It has smooth peripheral margination. There is a normal 1:3 cortex to medulla ratio with appropriate corticomedullary distinction. There is no evidence of pyelectasia, mineral or infarcts observed.

**Adrenal Glands**

The right adrenal gland is normal in size (2.75 cm long x 1.1 cm at the cranial pole and 0.88 cm at the caudal pole), shape and contour. Corticomedullary structure is unremarkable. Visible surrounding vasculature appears normal.

The left adrenal gland is normal in size (3.04 cm long x 1.05 cm at the cranial pole and 0.96 cm at the caudal pole), shape and contour. Corticomedullary structure is unremarkable. Visible surrounding vasculature appears normal.

**Spleen**

Spleen is generally normal in size and shape with a smooth capsular contour. Parenchyma is diffusely nodular in appearance characterized by small discrete hypoechoic nodules. Multifocal well demarcated, hyperechoic, homogeneous nodules are also noted in the spleen. Splenic vasculature appears normal.

**Liver**

The liver is subjectively normal in size with normal smooth curvilinear peripheral contour. Parenchyma is appropriately hypoechoic to the spleen in echogenicity and appropriately mildly coarse and homogenous in echotexture. A 1.3 cm x 1.8 cm hyperechoic nodule in the ventrocaudal mid liver. Visible vasculature and biliary tree appear normal without distension or congestion.

The gallbladder is non-distended in size. The wall is smooth without visible thickening. Luminal contents are primarily anechoic. There is no evidence of cystic or common bile duct dilation.

### ***Gastrointestinal***

The visible stomach wall is normal in thickness and layering. The lumen of the stomach is mildly distended with echogenic non-shadowing luminal contents and gas consistent with normal ingesta. There is no evidence of obstruction, foreign material or infiltrative disease. Pyloric outflow tract appears patent.

The visible small intestines are normal in wall thickness and layering (canine duodenum < 0.5 cm and feline duodenum < 0.4 cm; other < 0.3 cm). Small intestinal motility appears adequate (1-3 contractions per min). The lumen of the small intestine is empty with no evidence of obstruction, foreign material or infiltrative disease.

The visible colon is normal in wall thickness (< 0.2 cm) and layering. Contents are consistent with normal formed feces and gas.

### ***Pancreas***

The pancreatic parenchyma is appropriately isoechoic to surrounding tissue. Visible capsule is smooth and normal in contour. There is no visible pancreatic duct dilation. There is no evidence of active peripancreatic inflammation.

### ***Free Abdomen***

There is a scant amount of free fluid between liver lobes and around the spleen.

There is no apparent lymphadenopathy noted in these images.

## **ULTRASONOGRAPHIC FINDINGS**

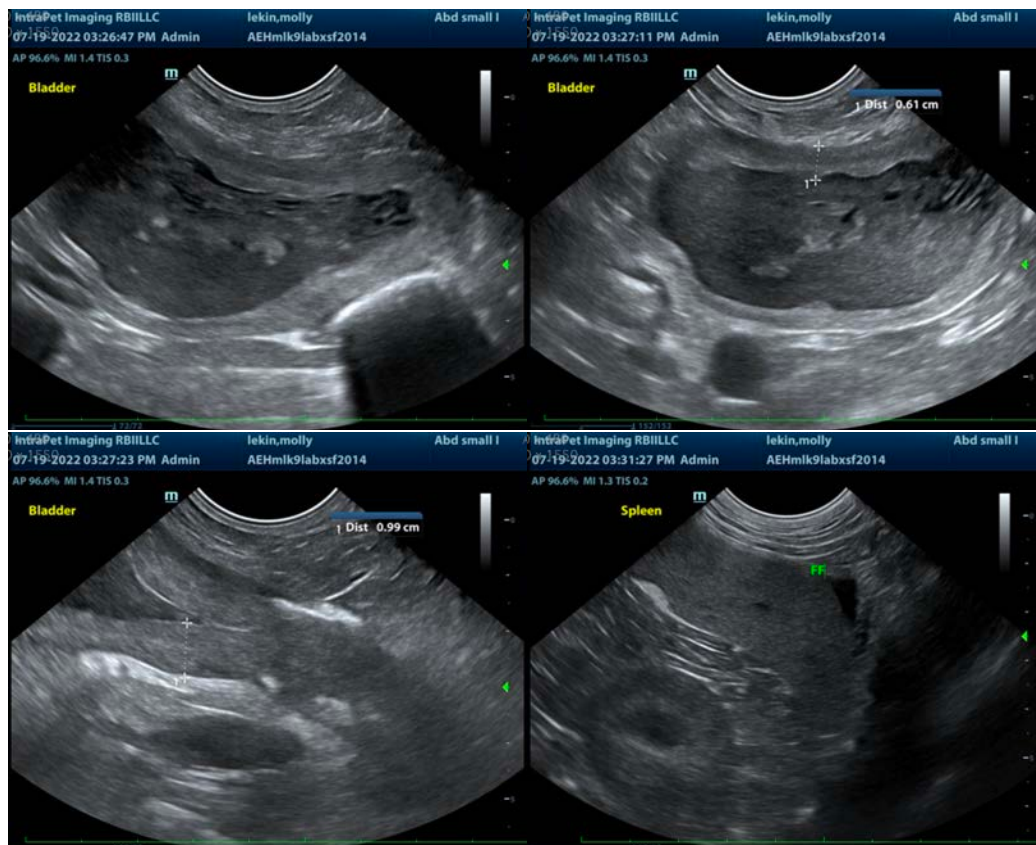
- **Urinary bladder wall changes** – consistent with severe cystitis compounded by hemorrhage, resulting from thrombocytopenia. However, while considered less likely, infiltrative neoplasia cannot be ruled out.
- **Liver nodule** – Differentials for a discrete liver nodule include primarily benign changes such as nodular hyperplasia, fibrosis of an old hematoma, granuloma, etc.; however, while considered less likely, primary hepatic neoplasia, infiltrative round cell neoplasia and metastatic disease can mimic benign lesions and cannot be definitively ruled out.
- **Splenic micronodular hyperplasia pattern**– This nodular change is often associated with benign aging nodular hyperplasia. Infiltrative neoplasia, however, including both early hemangiosarcoma as well as round cell neoplasia cannot be ruled out.
- **Hyperechoic splenic nodules** – most consistent with benign myelolipomas. Other differentials such as fibrosis or calcification caused by old hematomas or infarcts, chronic inflammation, granulomatous disease or metastatic disease cannot be ruled out, but are considered less likely.

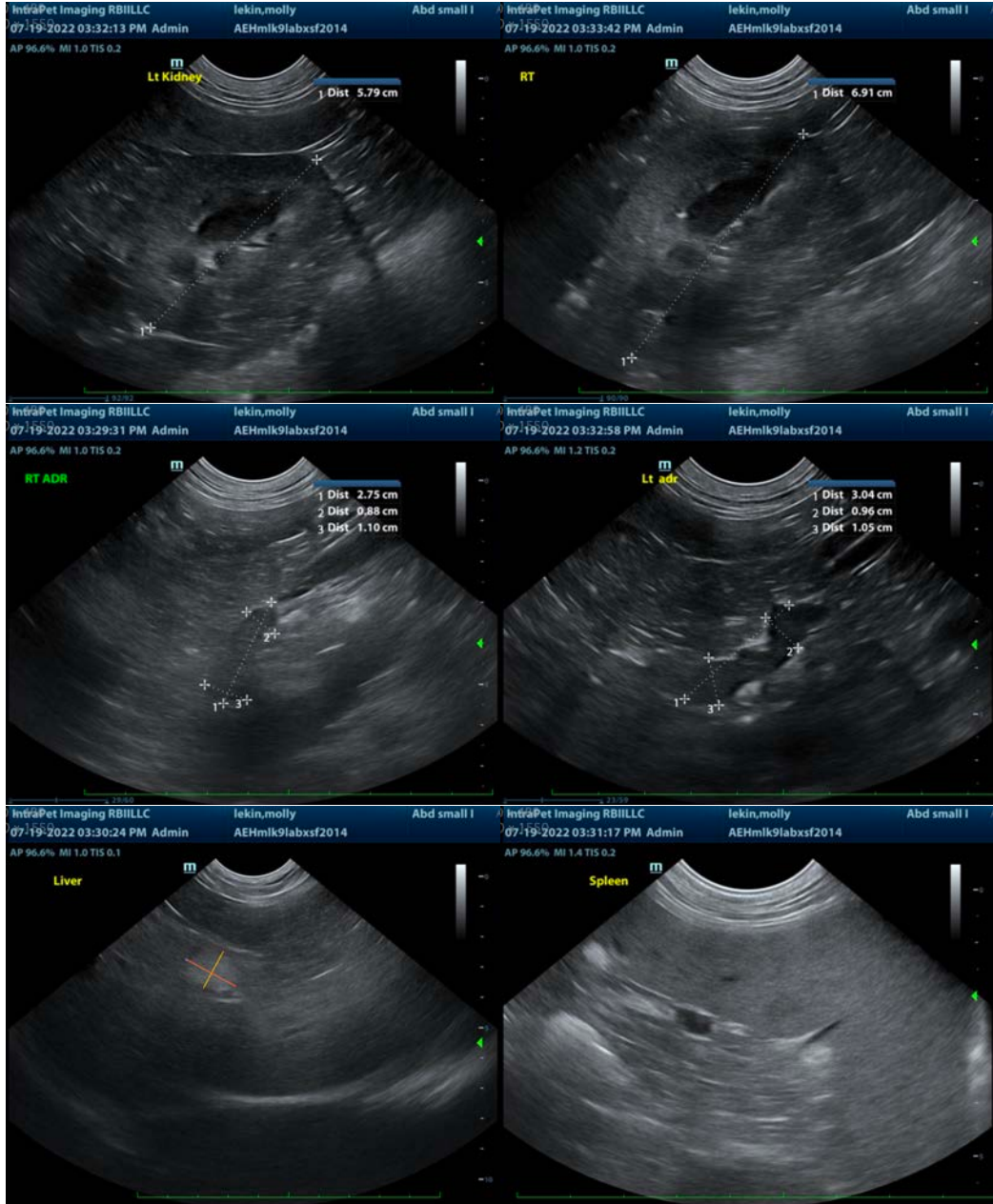
## **INTERPRETATION OF THE FINDINGS & FURTHER RECOMMENDATIONS**

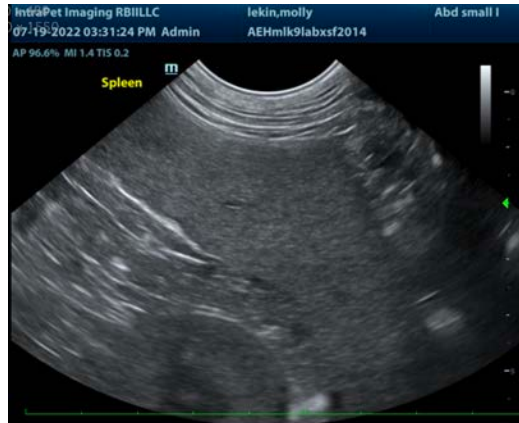This patient's hematuria is most likely the result of severe thrombocytopenia versus a primary infiltrative urinary bladder disease. Therefore, recommendations include:

- Further workup and therapy for presumed immune mediated thrombocytopenia, including comprehensive infectious disease testing, bone marrow cytology, etc., followed by immunosuppressive therapy +/- vincristine as well as blood products.
- Urinalysis is recommended if not recently evaluated.

- Following resolution of the thrombocytopenia, or when the value has increased to a safer level, further evaluation of the urinary bladder via traumatic catheterization or fine needle aspirate could be considered, if still indicated.
- In the meantime, a less invasive evaluation of the urinary bladder to rule out unlikely but possible infiltrative neoplasia, is submission of urine to look for BRAF gene mutation, which is associated with urinary bladder cancer, so that test could be considered in the meantime.
- Three view thoracic radiographs are recommended for further assessment of cardio-pulmonary status as well as to further evaluate for any evidence of metastatic disease, if not recently evaluated.







The information and recommendations provided are based on the images presented by the referring veterinarian/sonographer. No evaluation can be communicated regarding pathology that was not visible in the image/video clips provided.

Thank you for this referral. If the clinical or image interpretation does not parallel your findings or if I can be of any further assistance please contact me.

**Beth Johnson, DVM, DACVIM**  
Beth.Johnson@sonopath.com