**DATE**

7/18/22

PATIENT

Ginger Herring

SPECIES

Canine

BREED

Cockapoo

SEX

Spayed female

AGE

4/1/10

WEIGHT

14.3 lbs

INTERPRETED BYBeth Johnson, DVM
DACVIM**HOSPITAL NAME**Noah's Ark Veterinary
and Boarding Resort**REFERRING VET**

Dr. Martinez

INVOICE

31769

PRESENTING CLINICAL SIGNS

Patient presented for annual PE and annual lab work. During PE- NSF were found identified other than Grade 2/4 dental disease. Lab work had an elevated SDMA and Lipase/CK- follow up CPL – elevated 410. after discussed Clinical signs with mom she did feel that she will show some signs of decreased appetite that fluctuates and some clinical signs also will show up.

Current Medications: patient will be on gabapentin and trazodone for the US procedure to hopefully avoid sedation.

Lab Results: SDMA -16, Lipase 390, CPL- 410

Date of Previous IntraPet Ultrasound: No previous.

Sedation: Not required to complete full diagnostic ultrasound.

Stat Report: Not requested.

Imaging Performed By: Stephanie Pearce RDCS, RVT.

ULTRASONOGRAPHIC EXAMINATION OF THE ABDOMEN**Urinary System**

Urinary bladder is adequately distended with anechoic contents. No masses, inflammatory changes, echogenic sediment or cystoliths are observed. The urinary bladder, trigone and visible pelvic urethra are normal in thickness with a smooth mucosal surface.

Kidneys are overall normal in size and shape with smooth peripheral margination. A normal 1:3 cortex to medulla ratio is maintained. The medulla and cortices are uniform in texture with some mild increased cortical echogenicity and mild loss of corticomedullary distinction, expected in this age patient. There is no evidence of pyelectasia, mineral or infarcts observed. The left kidney measured 4.38 cm and the right kidney measured 4.37 cm.

Adrenal Glands

Left adrenal gland is normal in size (1.48 cm long, 0.37 cm at cranial pole and 0.38 cm at caudal pole), shape and overall architecture, echogenicity and echotexture. Visible surrounding vasculature appears normal.

Right adrenal gland is normal in size (0.54 cm thick), shape and overall architecture, echogenicity and echotexture. Visible surrounding vasculature appears normal.

Spleen

Spleen is subjectively normal in size with a normal smooth capsular contour. Parenchyma is appropriately finely textured and homogenous with normal echogenicity relative to surrounding tissue (hyperechoic to liver). No focal nodules or masses are observed. Splenic vasculature appears normal.

Liver

Liver is subjectively normal in size with normal smooth curvilinear peripheral contour. Parenchyma is appropriately hypoechoic to the spleen in echogenicity and appropriately mildly coarse and homogenous in echotexture. No focal lesions are observed. Visible vasculature and biliary tree appear normal without distension or congestion.

Gallbladder is moderately distended with anechoic bile as well as suspended and gravity dependent echogenic debris including mineral/sand debris. The wall is smooth without visible thickening. There is no evidence of cystic or CBD dilation. There is no evidence of effusion or inflammation.

Gastrointestinal

The visible stomach wall is normal in thickness and layering. The lumen of the stomach is mildly distended with fluid and very echogenic reverberation artifact from intraluminal gas. There is no evidence of obstruction, foreign material or infiltrative disease; however, complete visualization of far wall is partially inhibited by gas. Pyloric outflow tract appears patent.

The visible small intestines are normal in wall thickness and layering. Small intestinal motility appears adequate (1-3 contractions per min). The lumen of the small intestine is empty with no evidence of obstruction, foreign material or infiltrative disease.

The visible colon is normal in wall thickness (< 0.2 cm) and layering. Contents are consistent with normal formed feces and gas.

Pancreas

The observed pancreas appears appropriately isoechoic to surrounding omental fat. Visible capsule is smooth and normal in contour. Visible pancreatic parenchyma is homogenous and unremarkable. There is no visible pancreatic duct dilation. There is no evidence of active peripancreatic inflammation.

Free Abdomen

There is no evidence of peritoneal effusion or apparent lymphadenopathy noted in these images.

ULTRASONOGRAPHIC FINDINGS

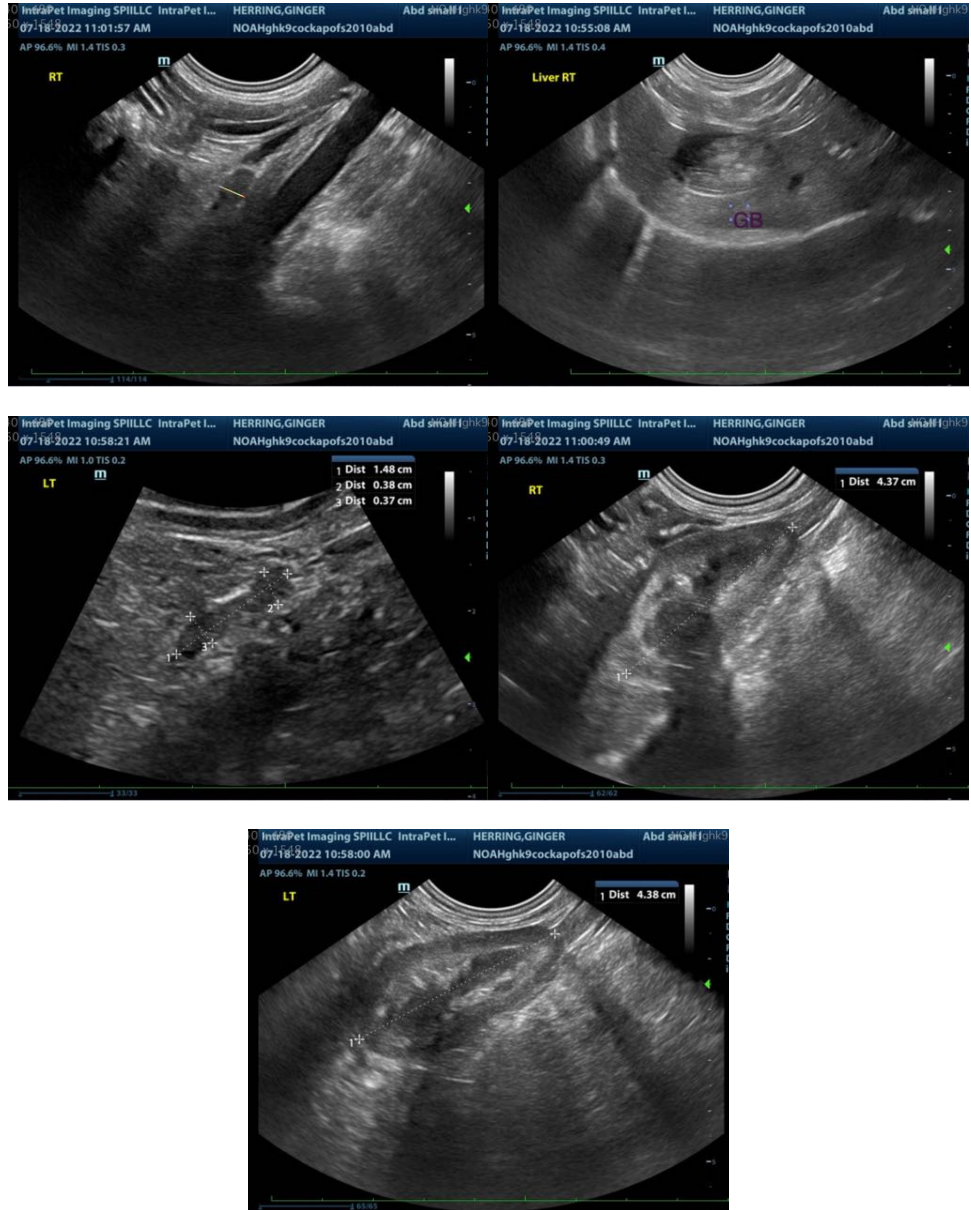
Primary Findings

- **Gallbladder debris.** Cholecystic debris is of unknown clinical significance. It can be seen with biliary stasis from fasting or illness. Cholecystic debris is not necessarily related to hepatobiliary disease. Echogenic bile is most commonly an incidental finding in dogs and should be interpreted in combination with clinical signs such as nausea, inappetence, cranial abdominal discomfort and/or laboratory changes such as increased ALP and/or increased Tbili.
- **Age related renal changes.**

INTERPRETATION OF THE FINDINGS & FURTHER RECOMMENDATIONS

There is no ultrasonographic evidence of pancreatic and/or renal disease. However, early emerging disease may not be visible via ultrasound. Therefore, if not recently evaluated recommendations include:

1. Urinalysis and, if indicated based on urinalysis results, urine culture are recommended. If protein is present in an otherwise quiet sediment, protein quantification with a urine protein to creatinine ration is recommended.
2. Blood pressure measurements.
3. If laboratory values continue to progress and/or clinical signs develop follow-up ultrasound monitoring should be considered as part of the future evaluation plane.



The information and recommendations provided are based on the images presented by the referring veterinarian. No evaluation can be communicated regarding pathology that was not visible in the image/video clips provided.

Thank you for this referral. If the clinical or image interpretation does not parallel your findings or if I can be of any further assistance please contact me.

Beth Johnson, DVM DACVIM
 Beth.Johnson@SonoPath.com