

**DATE**

7/14/22

PRESENTING CLINICAL SIGNS

History: Urinary concerns.

PATIENT

Tasha Olsson

Current Medications: Amoxicillin, Enrofloxacin.

Lab Results: See attached.

Date of Previous IntraPet Ultrasound: No previous.

Sedation: Not required to complete full diagnostic ultrasound.

Stat Report: Not requested.

Imaging Performed By: Rachel Brillhart, RDMS.

SPECIES

Canine

BREED

Beagle

SEX

Spayed Female

ULTRASONOGRAPHIC EXAMINATION OF THE ABDOMEN**Urinary System**

Urinary bladder is adequately distended with anechoic contents. No masses, inflammatory changes, echogenic sediment or cystoliths are observed. The urinary bladder and trigone are normal in thickness with a smooth mucosal surface. The urethra is subjectively mildly prominent/distended, which can be seen with urinary incontinence, but it appears to taper normally.

AGE

9/1/2007

Kidneys are overall normal in size and shape with smooth peripheral margination. A normal 1:3 cortex to medulla ratio is maintained. The medulla and cortices are uniform in texture with some mild increased cortical echogenicity and mild loss of corticomedullary distinction, expected in this age patient. There is no evidence of mineral or infarcts observed. The left kidney measures 6.13 cm. The right kidney measures 6.29 cm. Mild pyelectasia is present in the left kidney.

WEIGHT

27.1 Pounds

Adrenal Glands

Adrenal glands are plump/swollen in size. Normal shape and contour are maintained without evidence of capsular invasion. Corticomedullary structure is unremarkable. Visible surrounding vasculature appears normal. The left adrenal gland measures 2.58 cm long x 0.72 cm cranial pole and 0.81 cm caudal pole. The right adrenal gland measures 2.85 cm long x 0.77 cm cranial pole and 0.81 cm caudal pole.

INTERPRETED BYBeth Johnson, DVM
DACVIM**Spleen**

Spleen is subjectively normal in size with a normal smooth capsular contour. Parenchyma is appropriately finely textured and homogenous with normal echogenicity relative to surrounding tissue (hyperechoic to liver). Multifocal well-demarcated hyperechoic homogenous nodules are noted. Splenic vasculature appears normal.

HOSPITAL NAME

Bayside AMC

Liver

Liver is subjectively enlarged with mildly irregular margins. Parenchyma is heterogenous characterized by multiple poorly defined hypoechoic nodules within otherwise hyperechoic liver parenchyma. Visible vasculature and biliary tree appear normal without distension or congestion.

REFERRING VET

Dr. Buchanan

Gallbladder is mildly overdistended with a moderate amount of non-dependent, mildly aggregated/inspissated sludge. Hypo to anechoic cystic areas are noted between the gallbladder sludge and luminal wall. The wall is otherwise smooth without visible thickening. There is no evidence of cystic or CBD dilation. There is no evidence of effusion.

INVOICE

16622

Gastrointestinal

The visible stomach wall is normal in thickness and layering. The lumen of the stomach is empty with no evidence of obstruction, foreign material or infiltrative disease. Pyloric outflow tract appears patent.

The visible small intestines are normal in wall thickness and layering. Small intestinal motility appears adequate (1-3 contractions per min). The lumen of the small intestine is empty with no evidence of obstruction, foreign material or infiltrative disease.

The visible colon is normal in wall thickness and layering. Contents are consistent with normal formed feces and gas.

Pancreas

The observed pancreas appears appropriately isoechoic to surrounding omental fat. The capsule is mildly irregular in shape. Parenchyma is mildly heterogenous and coarse. There is no visible pancreatic duct dilation. There is no evidence of active peripancreatic inflammation. A non-architecture distorting hyperechoic nodule, measuring approximately 1.0 cm, was present in the right limb.

Free Abdomen

There is no evidence of peritoneal effusion. There is no apparent lymphadenopathy.

ULTRASONOGRAPHIC FINDINGS

Primary Findings

- Bilateral adrenomegaly – consistent with adrenal hyperplasia secondary to pituitary dependent hyperadrenocorticism vs stress or normal variant. Interpret in combination with clinical signs of hyperadrenocorticism.
- Heterogenous Liver – These changes are most consistent with benign processes such as nodular hyperplasia, steroid (vacuolar) hepatopathy, extramedullary hematopoiesis or possibly chronic inflammatory disease and less commonly infiltrative round cell or metastatic neoplasia.
- Emerging mucocele – Cholecystic debris is of unknown clinical significance. It can be seen with biliary stasis from fasting or illness. Cholecystic debris is not necessarily related to hepatobiliary disease. The non-dependent nature of this sludge combined with the cystic areas are suggestive, however, of possible emerging cystic mucosal hyperplasia or early gallbladder mucocele.
- Pancreatic age-related remodeling – Mild irregularities are consistent with benign age-related change. Low-grade smoldering chronic pancreatitis cannot be ruled out and should be suspected in the face of appropriate clinical signs. The nodule present in the right limb is most consistent with a benign nodule, such as seen with nodular hyperplasia, etc. Infiltrative disease can't be ruled out but is considered less likely given this patients history.

Secondary Findings

- Hyperechoic splenic nodules – most consistent with benign myelolipomas. Other differentials such as fibrosis or calcification caused by old hematomas or infarcts, chronic inflammation, granulomatous disease or metastatic disease cannot be ruled out, but are considered less likely.
- Age-related kidney change with mild pyelectasia and a mildly dilated urethra, both consistent with likely PU/PD and potentially some urinary incontinence and should be interpreted in combination with clinical signs.

INTERPRETATION OF THE FINDINGS & FURTHER RECOMMENDATIONS

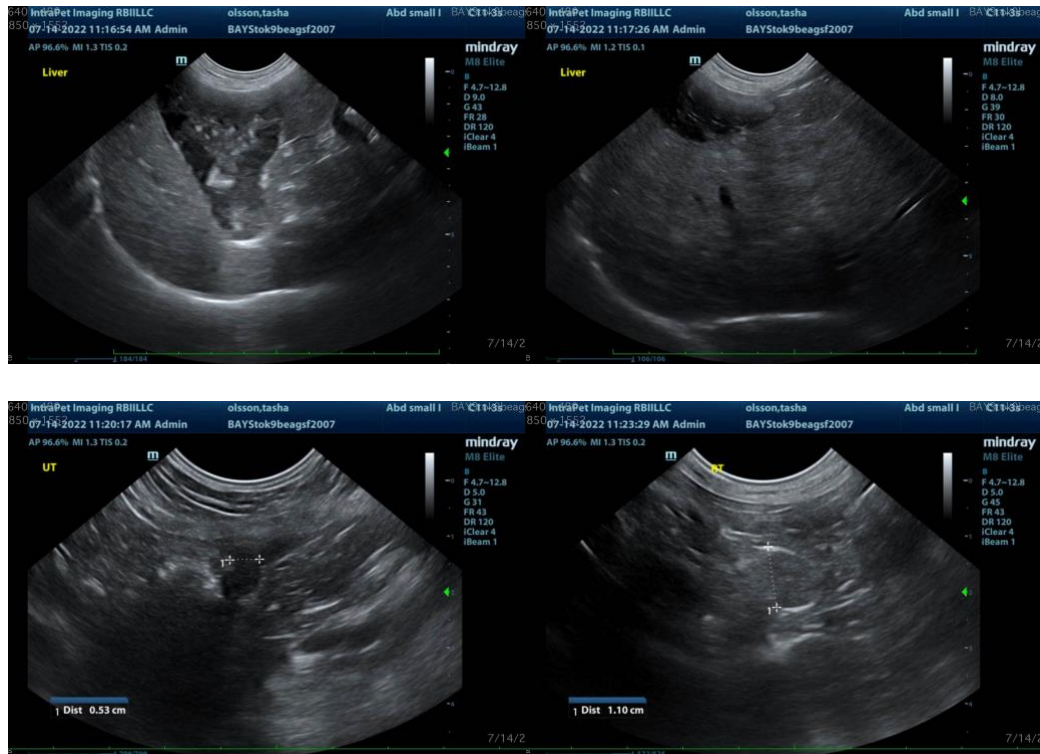
The described adrenal gland, liver and gallbladder changes are all suggestive of hyperadrenocorticism. If clinical signs of hyperadrenocorticism, such as polyuria, polydipsia, polyphagia, panting, hair loss, hypertension, etc. are present, testing for hyperadrenocorticism with a LDDS test is warranted. If a LDDS test has been evaluated with a normal result, investigation of possible atypical hyperadrenocorticism with a full ACTH stimulation adrenal panel to the University of Tennessee could be considered.

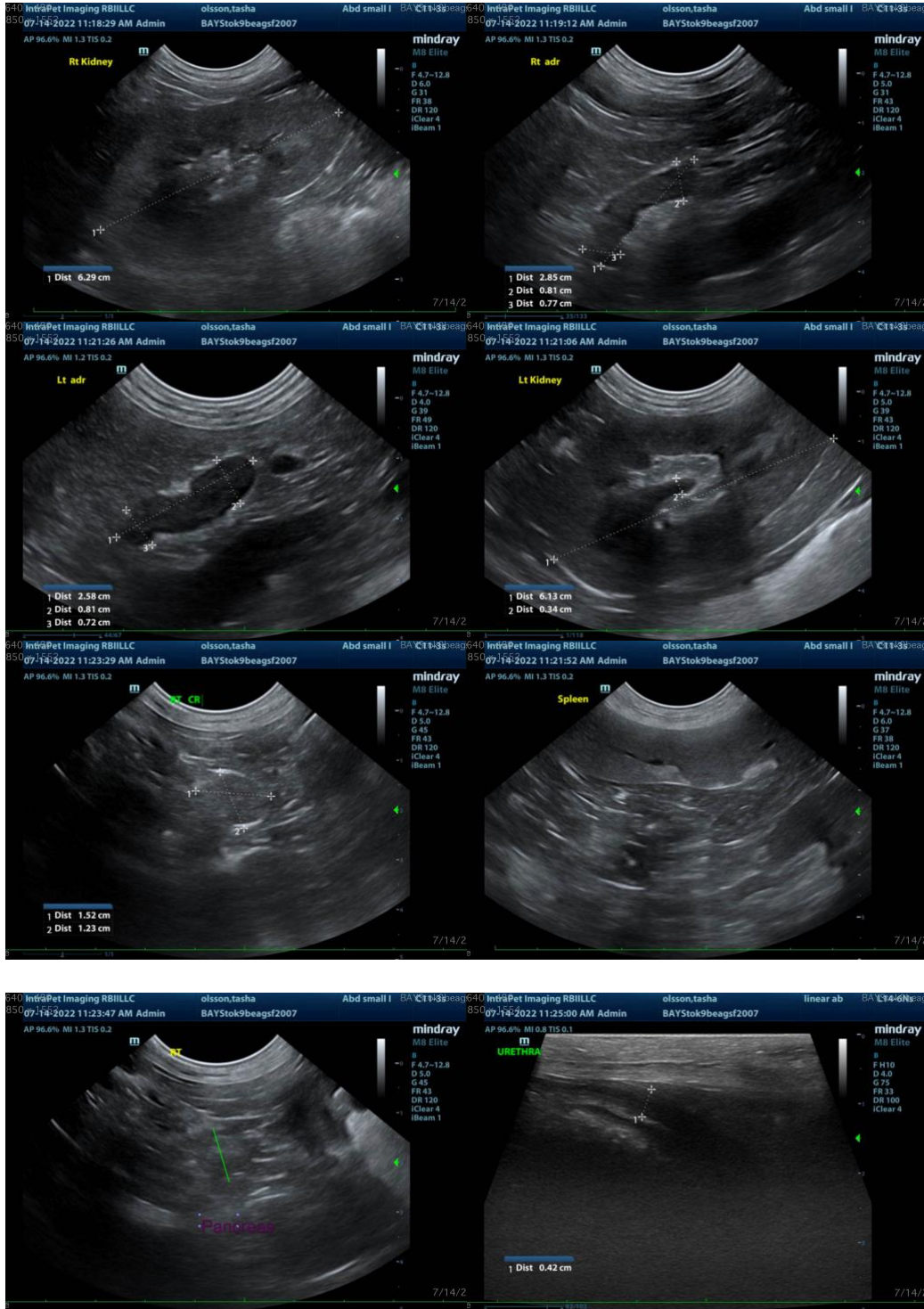
If clinical signs are not present, monitoring is recommended with testing pursued when/if clinical signs develop.

If not recently evaluated, blood pressure is recommended.

If not recently evaluated, a urinalysis and, if indicated based on urinalysis results, urine culture are also recommended. If protein is present in an otherwise quiet sediment, protein quantification with a urine protein to creatinine ratio is recommended.

Without current clinical signs, both the pancreatic changes and gallbladder changes should be monitored closely with a recheck ultrasound in 6-8 weeks.





The information and recommendations provided are based on the images presented by the referring veterinarian. No evaluation can be communicated regarding pathology that was not visible in the image/video clips provided.

Thank you for this referral. If the clinical or image interpretation does not parallel your findings or if I can be of any further assistance please contact me.

Beth Johnson, DVM DACVIM

Beth.Johnson@SonoPath.com