

**DATE PRESENTING CLINICAL SIGNS**

7/13/23

Patient presented with PU/PD. Physical exam revealed severe dental disease, pot-bellied appearance to abdomen with cranial organomegaly.

**PATIENT**

Chloe Bratcher

Current Medications: Amoxicillin 250mg Capsule 6/30/2023, Dasuquin Advanced S/M Chew Tablets 64ct 6/30/2023.

Lab Results: ALP 748, ALT 535, GGT 21, Cholesterol 450, Triglycerides 350, Low Dose Dexamethasone Suppression testing - consistent with hyperadrenocorticism, but unable to differentiate between pituitary vs adrenals.

**SPECIES**

Canine

Date of Previous IntraPet Ultrasound: No previous.

Sedation: Not required to complete full diagnostic ultrasound.

Stat Report: Not requested.

**BREED**

Dachshund

Imaging Performed By: Andi Parkinson, BS, RDMS.

**ULTRASONOGRAPHIC EXAMINATION OF THE ABDOMEN****SEX**

Spayed Female

**Urinary System**

Urinary bladder is adequately distended. It has a normal uniform wall thickness. Contents include primarily anechoic fluid with occasional echogenic non-shadowing debris, most consistent with exfoliated cells, mucous and/or small blood clots. Both sterile inflammation as well as urinary tract infection can also present with echogenic debris. No masses or cystoliths are observed. The trigone and visible pelvic urethra are normal in thickness with a smooth mucosal surface.

**AGE**

11/15/11

**WEIGHT**

29 Pounds

The right kidney is normal in size (6.36 cm), shape and echogenicity. It has smooth peripheral margination. There is a normal 1:3 cortex to medulla ratio with appropriate corticomedullary distinction. There is no evidence of pyelectasia, mineral or infarcts observed.

**INTERPRETED BY**Beth Johnson, DVM  
DACVIM

The left kidney is normal in size (5.76 cm), shape and echogenicity. It has smooth peripheral margination. There is a normal 1:3 cortex to medulla ratio with appropriate corticomedullary distinction. There is no evidence of pyelectasia, mineral or infarcts observed.

**HOSPITAL NAME**

Everhart Vet Hospital

**Adrenal Glands**

Adrenal glands are plump/swollen in size. Normal shape and contour are maintained without evidence of capsular invasion. Corticomedullary structure is unremarkable. Visible surrounding vasculature appears normal. The left adrenal gland measured 1.2 cm at the cranial pole and 1.1 cm at the caudal pole. The right adrenal gland measures 0.91 cm at the cranial pole and 0.97 cm at the caudal pole.

**REFERRING VET**

Dr. Kerr

**Spleen**

The spleen is subjectively normal in size with a normal smooth capsular contour. Parenchyma is appropriately finely textured and homogenous with normal echogenicity relative to surrounding tissue (hyperechoic to liver). No focal nodules or masses are observed. Splenic vasculature appears normal.

**INVOICE**

43821

**Liver**

Liver is subjectively enlarged (swollen contour) without disruption of architecture. It has a normal homogenous echotexture. Parenchyma is diffusely hyperechoic characterized by less prominent than normal portal vein walls and increased echogenicity relative to the spleen and falciform fat. No focal lesions are observed. Visible vasculature and biliary tree appear normal without distension or congestion.

The gallbladder is non-distended in size. The wall is smooth without visible thickening. Luminal contents are primarily anechoic. There is no evidence of cystic or common bile duct dilation.

### ***Gastrointestinal***

The stomach wall is normal in thickness (canine < 0.5 cm and feline < 0.4 cm) and layering. The lumen of the stomach is empty with no evidence of obstruction, foreign material or infiltrative disease. Pyloric outflow tract appears patent.

The visible small intestines are normal in wall thickness and layering (canine duodenum < 0.5 cm and feline duodenum < 0.4 cm; other < 0.3 cm). Small intestinal motility appears adequate (1-3 contractions per min). The lumen of the small intestine is empty with no evidence of obstruction, foreign material or infiltrative disease.

The visible colon is normal in wall thickness (< 0.2 cm) and layering. Contents are consistent with normal formed feces and gas.

### ***Pancreas***

The area of the pancreas contains irregular hyperechoic pancreatic remodeling.

### ***Free Abdomen***

There is no evidence of free peritoneal effusion noted in these images.

There is no apparent lymphadenopathy noted in these images.

## **ULTRASONOGRAPHIC FINDINGS**

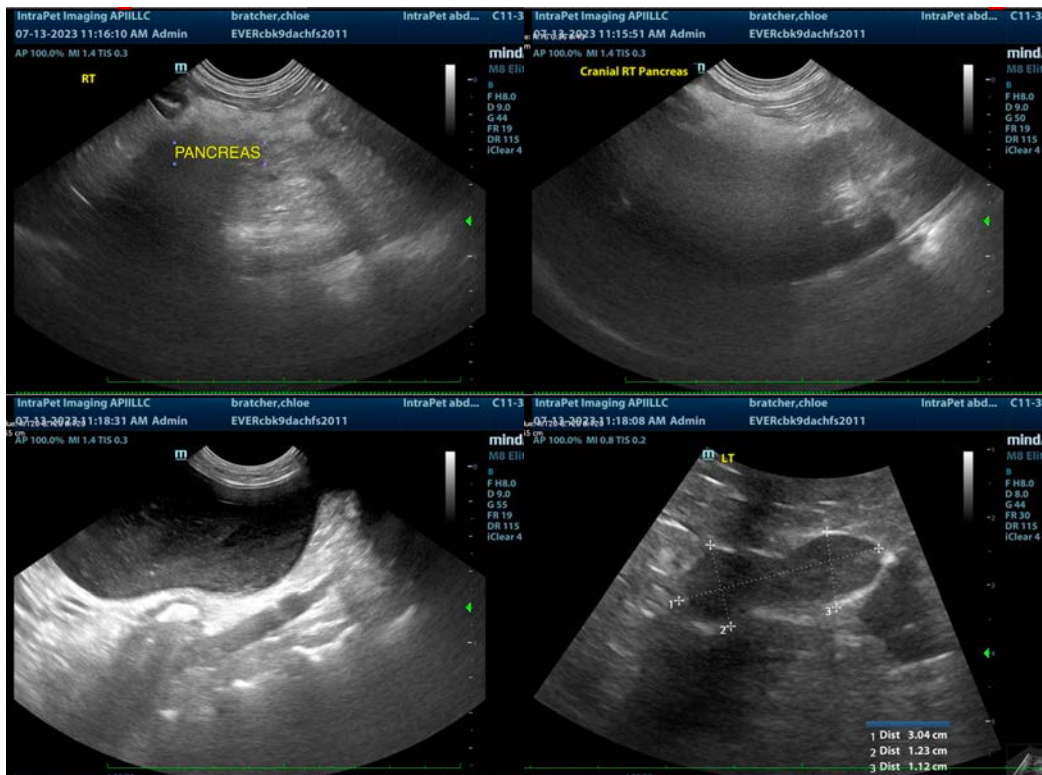
- **Bilateral adrenomegaly** – consistent with adrenal hyperplasia secondary to pituitary dependent hyperadrenocorticism vs stress or normal variant. Interpret in combination with clinical signs of hyperadrenocorticism.
- **Hyperechoic hepatomegaly** - This appearance is non-specific and most consistent with a benign steroid (endocrine) or vacuolar hepatopathy or reactive or idiopathic hepatopathy. Inflammatory and/or infiltrative disease (such as round cell neoplasia) are also possible, but considered less likely.
- **Hyperechoic pancreas** – This finding is suggestive of pancreatic fibrosis, possibly secondary to chronic pancreatitis. A TLI is recommended to rule out exocrine pancreatic insufficiency (EPI), especially if clinical signs (weight loss, diarrhea, etc.) are present. Given the degree of “fuzzy” hyperechoic tissue, an acute or chronic smoldering inflammatory pancreatitis cannot be definitively ruled out.
- Significant amount of urinary bladder debris.

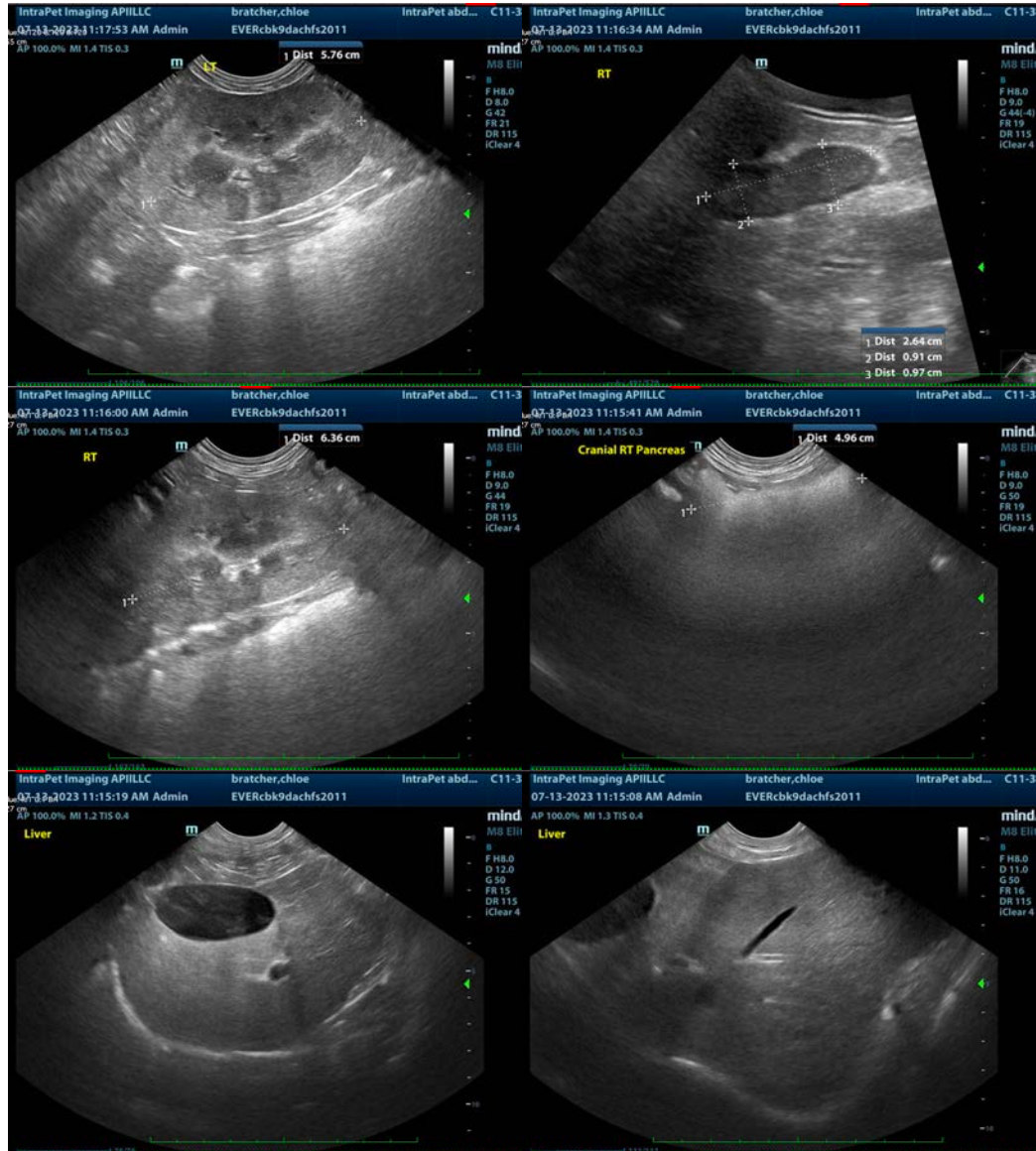
## **INTERPRETATION OF THE FINDINGS & FURTHER RECOMMENDATIONS**

Given that this patient is reportedly clinical for hyperadrenocorticism and has a diagnostic low-dose Dexamethasone suppression test that is also diagnostic for hyperadrenocorticism, these images are most consistent with pituitary dependent disease. Given the diagnosis of hyperadrenocorticism, if not recently evaluated:

- Blood pressure is recommended.

- Urinalysis and, if indicated based on urinalysis results, urine culture are recommended. If protein is present in an otherwise quiet sediment, protein quantification with a urine protein to creatinine ration is recommended.
- A gastrointestinal malabsorption panel (including cobalamin, folate, TLI and PLI) to Texas A&M GI Laboratory is recommended for further evaluation of GI and pancreatic function.
- Finally, while hyperadrenocorticism certainly can result in increased liver enzymes, it is a little atypical to have an ALT at the level of this patient's reported ALT. Options include further workup for hepatopathy, including testing for Leptospirosis, fine needle aspirate of the liver if patient's coagulation status is appropriate, etc., versus beginning medical management for hyperadrenocorticism and monitoring the liver enzymes for improvement.





The information and recommendations provided are based on the images presented by the referring veterinarian/sonographer. No evaluation can be communicated regarding pathology that was not visible in the image/video clips provided.

Thank you for this referral. If the clinical or image interpretation does not parallel your findings or if I can be of any further assistance please contact me.

**Beth Johnson, DVM, DACVIM**  
[info@sonopath.com](mailto:info@sonopath.com)