

PATIENT PRESENTING CLINICAL SIGNS

Maybe Mandoli

Newer "pot belly appearance", suspicious of organomegaly; nonpainful found on most recent exam. Bloodwork was run to rule out any changes- ALP is elevated when it was not prior and there was no record of HCT previously, but now mild anemia. O also reports PU/PD that is new and weight gain recently with no change in food.

SPECIES

Canine

Abnormal PE/Chem/CBC/UA Results: Full senior screen: CBC: RBC-5.04 (low), Hematocrit 34.7 (low), Hemoglobin 12.6 (low) Chem: ALP 277 (high) UA- 1.034, 8.5 pH, lipid droplets present T4 normal Current Medications Bravecto, unsure if alprazolam or ace was given this morning

BREED

Cairn Terrier

ULTRASONOGRAPHIC EXAMINATION OF THE ABDOMEN

SEX

Urinary System

Spayed Female

The urinary bladder is moderately distended with anechoic contents. No masses, inflammatory changes, echogenic sediment or cystoliths are observed. The urinary bladder, trigone and visible pelvic urethra are normal in thickness with a smooth mucosal surface.

AGE

7 Years

The right kidney is normal in size and shape with smooth peripheral margination. A normal 1:3 cortex to medulla ratio is maintained. The medulla and cortices are uniform in texture with some mild increased echogenicity and mild loss of corticomedullary distinction. There is no evidence of pyelectasia or infarcts observed. Non-obstructive linear multifocal hyperechoic diverticular foci with acoustic shadowing are noted. The right kidney measured 4.36 cm.

WEIGHT

17.2 Pounds

The left kidney is normal in size and shape with smooth peripheral margination. A normal 1:3 cortex to medulla ratio is maintained. The medulla and cortices are uniform in texture with some mild increased echogenicity and mild loss of corticomedullary distinction. There is no evidence of pyelectasia or infarcts observed. Non-obstructive linear multifocal hyperechoic diverticular foci with acoustic shadowing are noted. The left kidney measured 4.23 cm.

INTERPRETED BY

Beth Johnson, DVM
DACVIM

Adrenal Glands

IMAGING PERFORMED BY

Sara Hansen

The right adrenal gland is normal in size (2.64 cm long x 1.39 cm at the cranial pole and 0.59 cm at the caudal pole), shape and contour. Corticomedullary structure is unremarkable. Visible surrounding vasculature appears normal.

HOSPITAL NAME

Santa Clara AH

The left adrenal gland is normal in size (2.55 cm long x 0.40 cm at the cranial pole and 0.61 cm at the caudal pole), shape and contour. Corticomedullary structure is unremarkable. Visible surrounding vasculature appears normal.

REFERRING VET

Dr. Elsbree

Spleen

The spleen is subjectively normal in size with a normal smooth capsular contour. Parenchyma is appropriately finely textured and homogenous with normal echogenicity relative to surrounding tissue (hyperechoic to liver). No focal nodules or masses are observed. Splenic vasculature appears normal.

INVOICE

39485

Liver

Liver is subjectively enlarged. Margins are smooth but round. It has a normal homogenous echotexture. Parenchyma is diffusely hyperechoic characterized by less prominent than normal portal vein walls and increased echogenicity relative to the spleen. No focal lesions are observed. Visible vasculature and biliary tree appear normal without distension or congestion.

DATE

7/13/22



PATIENT	The gallbladder is moderately distended with anechoic bile as well as suspended and gravity dependent echogenic debris. The wall is smooth without visible thickening. There is no evidence of cystic or CBD dilation. There is no evidence of effusion or inflammation.
Maybe Mandoli	
SPECIES	<i>Gastrointestinal</i>
Canine	The stomach wall is normal in thickness (canine < 0.5 cm and feline < 0.4 cm) and layering. The lumen of the stomach is empty with no evidence of obstruction, foreign material or infiltrative disease. Pyloric outflow tract appears patent.
BREED	
Cairn Terrier	The visible small intestines are normal in wall thickness and layering (canine duodenum < 0.5 cm and feline duodenum < 0.4 cm; other < 0.3 cm). Small intestinal motility appears adequate (1-3 contractions per min). The lumen of the small intestine is empty with no evidence of obstruction, foreign material or infiltrative disease.
SEX	
Spayed Female	The visible colon is normal in wall thickness (< 0.2 cm) and layering. Contents are consistent with normal formed feces and gas.
AGE	
7 Years	<i>Pancreas</i> The pancreatic parenchyma is appropriately isoechoic to surrounding tissue. Visible capsule is smooth and normal in contour. There is no visible pancreatic duct dilation. There is no evidence of active peripancreatic inflammation.
WEIGHT	
17.2 Pounds	<i>Free Abdomen</i> There is no evidence of free peritoneal effusion noted in these images. There is no apparent lymphadenopathy noted in these images.
INTERPRETED BY	
Beth Johnson, DVM DACVIM	
IMAGING PERFORMED BY	
Sara Hansen	<ul style="list-style-type: none"> • Hyperechoic hepatomegaly – This appearance is non-specific and most consistent with a benign steroid (endocrine) or vacuolar hepatopathy or reactive or idiopathic hepatopathy. Inflammatory and/or infiltrative disease (such as round cell neoplasia) are also possible, but considered less likely. • Gallbladder debris – Cholecystic debris is of unknown clinical significance. It can be seen with biliary stasis from fasting or illness. Cholecystic debris is not necessarily related to hepatobiliary disease. Echogenic bile is most commonly an incidental finding in dogs and should be interpreted in combination with clinical signs such as nausea, inappetence, cranial abdominal discomfort and/or laboratory changes such as increased ALP and/or increased Tbili.
HOSPITAL NAME	
Santa Clara AH	
REFERRING VET	
Dr. Elsbree	SECONDARY FINDINGS <ul style="list-style-type: none"> • Age related kidney changes with non-obstructive dystrophic mineralization
INVOICE	
39485	<u>INTERPRETATION OF THE FINDINGS & FURTHER RECOMMENDATIONS</u> Given the pot bellied appearance and the reported PU/PD as well as the new mildly increased ALP, hyperadrenocorticism is a differential. However, a specific gravity of 1.034 is not characteristic of hyperadrenocorticism, nor is the newly reported anemia. Therefore, recommendations include:
DATE	
7/13/22	<ul style="list-style-type: none"> • Working up other possible causes of PU/PD, beginning possibly with a urine culture to rule out



PATIENT

an occult urinary tract infection, potentially testing for Leptospirosis, etc.

Maybe Mandoli

- Working up the anemia, beginning with determining whether it is regenerative or not, ruling out slow chronic hemorrhage such as a GI bleed, looking for infectious disease, etc. that might lead to early hemolysis, all before further pursuing possible hyperadrenocorticism.

SPECIES

Canine

- In the meantime, given the new mild anemia, empirical deworming with a 5-day course of Panacur is recommended.

BREED

Cairn Terrier

- If the anemia is addressed and resolves, and clinical signs continue, a low-dose Dexamethasone suppression to rule out hyperadrenocorticism would be an appropriate step in the future.

SEX

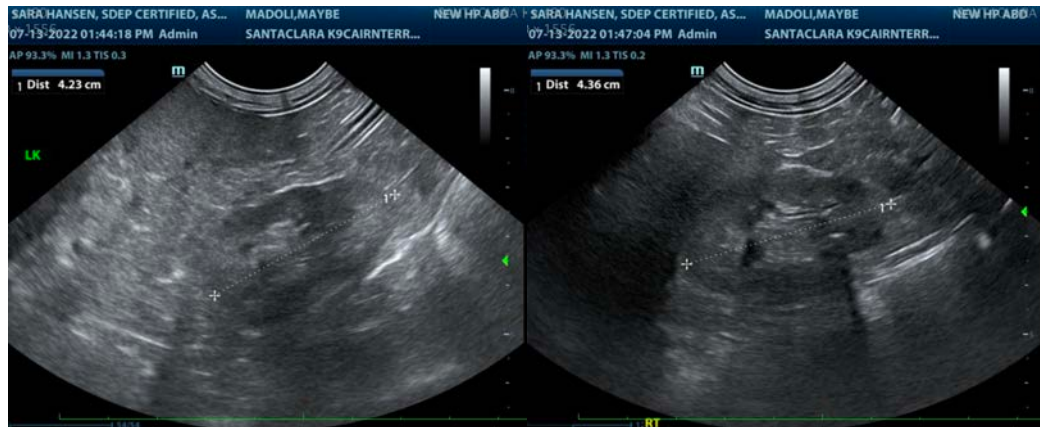
Spayed Female

AGE

7 Years

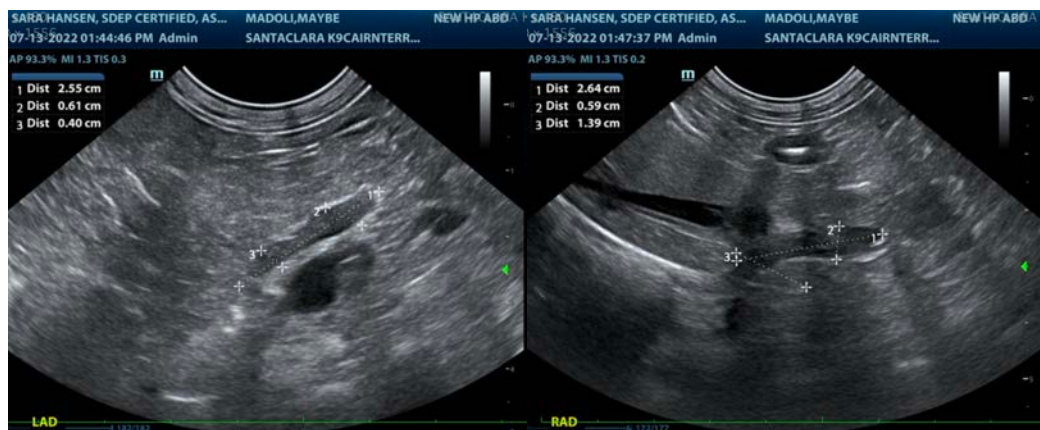
WEIGHT

17.2 Pounds



INTERPRETED BY

Beth Johnson, DVM
DACVIM



IMAGING PERFORMED BY

Sara Hansen

HOSPITAL NAME

Santa Clara AH

REFERRING VET

Dr. Elsabee

INVOICE

39485

DATE

7/13/22



PATIENT

Maybe Mandoli

SPECIES

Canine

BREED

Cairn Terrier

SEX

Spayed Female

AGE

7 Years

WEIGHT

17.2 Pounds

INTERPRETED BY

Beth Johnson, DVM
DACVIM

IMAGING PERFORMED BY

Sara Hansen

HOSPITAL NAME

Santa Clara AH

REFERRING VET

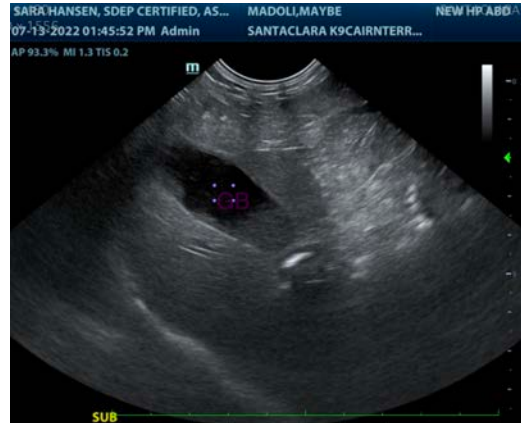Dr. Elsbree

INVOICE

39485

DATE

7/13/22



The information and recommendations provided are based on the images presented by the referring veterinarian/sonographer. No evaluation can be communicated regarding pathology that was not visible in the image/video clips provided.

Thank you for this referral. If the clinical or image interpretation does not parallel your findings or if I can be of any further assistance please contact me.

Beth Johnson, DVM, DACVIM
Beth.Johnson@sonopath.com