

PATIENT PRESENTING CLINICAL SIGNS

Rocky Sovagovic BAR, CRT<2S, MM pink Couple of weeks of urine issues (stranguria, polyuria). Did urinate today. No hematuria seen. E/D normally No V/D/C/S/I meds: Clavaseptin 250mg BID
SPECIES Abnormal PE/Chem/CBC/UA Results: Urine analysis: Diluted urine (RBC>50/hpf, WBC>50/hpf, SG 1.015, pH 6, suspect cocci) please see attached rads and report

Canine

ULTRASONOGRAPHIC EXAMINATION OF THE ABDOMEN

BREED

Urinary System

Beagle X

The urinary bladder is subjectively moderately overdistended with primarily anechoic contents as well as a small amount of echogenic debris. There is a solitary sessile, heterogeneous, primarily hyperechoic mass lesion along the ventral wall. The mass extends approximately 6.5-7.0 cm long x approximately 2.0 cm into the lumen of the bladder. No cystoliths are observed. The trigone does not appear to be involved.

SEX

Neutered Male

The prostate is normal in size and shape for this neutered male dog. The parenchyma is homogenous and the external margins are smooth. The prostatic urethra appears normal with no evidence of irregularity, invasion, mass effect or calculi.

AGE

11 Years

The right kidney is normal in size (6.4 cm) and shape with smooth peripheral margination. A normal 1:3 cortex to medulla ratio is maintained. The medulla and cortices are uniform in texture with some mild increased echogenicity and mild loss of corticomedullary distinction. There is no evidence of pyelectasia, mineral or infarcts observed. Multiple small cortical cysts noted.

WEIGHT

27.9 kg

The left kidney is normal in size (7.79 cm) and shape with smooth peripheral margination. A normal 1:3 cortex to medulla ratio is maintained. The medulla and cortices are uniform in texture with some mild increased echogenicity and mild loss of corticomedullary distinction. There is no evidence of pyelectasia, mineral or infarcts observed. Multiple small cortical cysts noted.

INTERPRETED BY

Beth Johnson, DVM
DACVIM

Adrenal Glands

The right adrenal gland is normal in size (1.93 cm long x 1.67 cm at the cranial pole and 0.82 cm at the caudal pole), shape and contour. Corticomedullary structure is unremarkable. Visible surrounding vasculature appears normal.

IMAGING PERFORMED BY

Kelly Reschny

The left adrenal gland is normal in size (2.9 cm long x 1.1 cm at the cranial pole and 0.96 cm at the caudal pole), shape and contour. Corticomedullary structure is unremarkable. Visible surrounding vasculature appears normal.

HOSPITAL NAME

BPH Burlington

Spleen

The spleen is subjectively normal in size with a normal smooth capsular contour. Parenchyma is appropriately finely textured and homogenous with normal echogenicity relative to surrounding tissue (hyperechoic to liver). A 3.5 cm x 4.0 cm homogeneous, isoechoic mass is noted, which results in capsular expansion mid body. An adjacent lymph node versus a splenic mass cannot be ruled out, but is considered less likely. Splenic vasculature appears normal.

REFERRING VET

Dr. Ruggieri

INVOICE

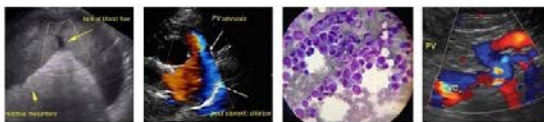
39405

Liver

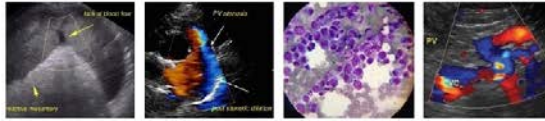
The liver is subjectively normal in size with normal smooth curvilinear peripheral contour. Parenchyma is appropriately hypoechoic to the spleen in echogenicity and appropriately mildly coarse and homogenous in echotexture. No focal lesions are observed. Visible vasculature and biliary tree appear normal without distension or congestion.

DATE

7/12/22



PATIENT	GB contains a moderate amount of non-dependent, mildly aggregated/inspissated sludge. Hypo to anechoic cystic areas are noted between the gallbladder sludge and luminal wall. The wall is otherwise smooth without visible thickening. There is no evidence of cystic or CBD dilation. There is no evidence of effusion.
Rocky Sovagovic	
SPECIES	Gastrointestinal
Canine	The stomach wall is normal in thickness (canine < 0.5 cm and feline < 0.4 cm) and layering. The lumen of the stomach is mildly distended with echogenic non-shadowing luminal contents and gas consistent with normal ingesta. There is no evidence of obstruction, foreign material or infiltrative disease. Pyloric outflow tract appears patent.
BREED	
Beagle X	The visible small intestines are normal in wall thickness and layering (canine duodenum < 0.5 cm and feline duodenum < 0.4 cm; other < 0.3 cm). Small intestinal motility appears adequate (1-3 contractions per min). The lumen of the small intestine is empty with no evidence of obstruction, foreign material or infiltrative disease. **See other.
SEX	
Neutered Male	The visible colon is normal in wall thickness (< 0.2 cm) and layering. Contents are consistent with normal formed feces and gas.
AGE	Pancreas
11 Years	The pancreatic parenchyma is appropriately isoechoic to surrounding tissue. Visible capsule is smooth and normal in contour. There is no visible pancreatic duct dilation. There is no evidence of active peripancreatic inflammation.
WEIGHT	Free Abdomen
27.9 kg	Medial to the left kidney, there is a focal cystic structure believed to be a cystic lymph node.
INTERPRETED BY	In the left cranial abdomen, caudal to the stomach, there is a poorly differentiated, heterogeneous structure/mass that measures approximately 7.0-7.5 cm in diameter and appears to contain fluid pockets.
Beth Johnson, DVM DACVIM	No pericardial effusion noted in these images.
IMAGING PERFORMED BY	PRIMARY FINDINGS
Kelly Reschny	<ul style="list-style-type: none"> Urinary bladder mass – Urinary bladder wall changes are most concerning for infiltrative neoplasia such as transitional cell carcinoma vs other. Benign inflammatory disease (cystitis) cannot be ruled out but is considered less likely given the location and appearance of the tissue. **This mass does not appear to involve the ureters and/or trigone, and therefore may be resectable. Poorly differentiated, cranial abdominal partially fluid filled structure – Differentials include an abscess, granuloma, hematoma of possible omental or less likely bowel origin. Infiltrative neoplasia is possible. However, there is not adequate blood flow to support a well vascularized tissue mass. Isoechoic, homogeneous splenic mass – Differentials include both benign changes such as extramedullary hematopoiesis or lymphoid hyperplasia as well as infiltrative neoplastic diseases such as round cell neoplasia, which can mimic benign lesions, especially given the capsular expansion. A lymph node adjacent to the spleen can't be ruled out versus a splenic mass, but is considered less likely. Early mucocele – Cholecystic debris is of unknown clinical significance. It can be seen with biliary stasis from fasting or illness. Cholecystic debris is not necessarily related to
HOSPITAL NAME	
BPH Burlington	
REFERRING VET	
Dr. Ruggieri	
INVOICE	
39405	
DATE	
7/12/22	



PATIENT

Rocky Sovagovic

hepatobiliary disease. The non-dependent nature of this sludge combined with the cystic areas are suggestive, however, of possible emerging cystic mucosal hyperplasia or early gallbladder mucocele.

SPECIES

Canine

- Reactive lymph node medial to the left kidney – This finding can be seen with chronic urinary tract infections, pyelonephritis, etc.

SECONDARY FINDINGS

- Age related kidney changes with cortical cysts

BREED

Beagle X

INTERPRETATION OF THE FINDINGS & FURTHER RECOMMENDATIONS

SEX

Neutered Male

- Urinalysis and urine culture, if indicated based on urinalysis results, are recommended. Submission of urine to look for BRAF gene mutation, which is associated with urinary bladder cancer, could be considered. Other diagnostic options include traumatic catheterization, fine needle aspirate (with small risk of tumor seeding/trailing) or cystoscopy for further sampling.

AGE

11 Years

- fine needle aspirates of both the splenic lesion and the cranial abdominal structure for cytology as well as culture could be considered, if patient's coagulation status is appropriate.

WEIGHT

27.9 kg

- Three view thoracic radiographs are recommended for further assessment of cardio-pulmonary status as well as to further evaluate for any evidence of metastatic disease, if not recently evaluated.

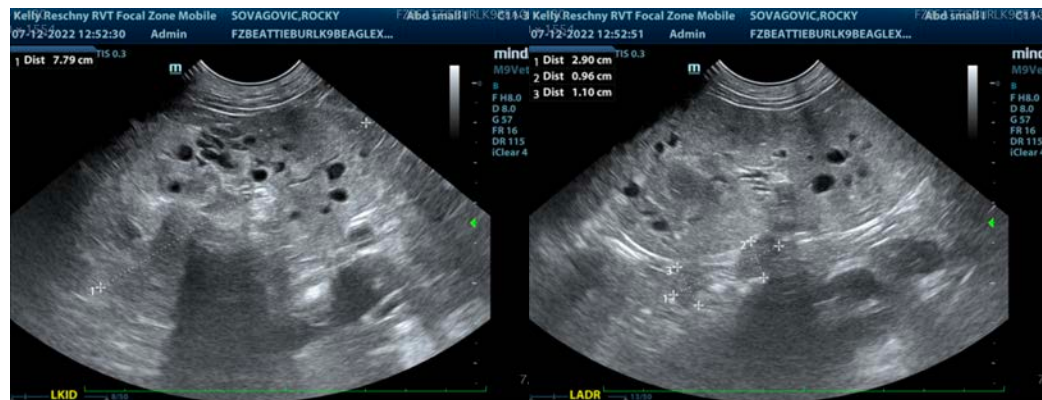INTERPRETED BY

Beth Johnson, DVM
DACVIM

- The above recommendations are made for each lesion individually, and it is slightly atypical to this combination of lesions. Therefore, a more definitive approach may be an exploratory laparotomy with plans to excise the urinary bladder mass, if possible, explore and remove the cranial abdominal structure, biopsy and/or remove the splenic lesion, as well as further assess the gallbladder. A pre-surgical planning abdominal CT scan could be considered.

IMAGING PERFORMED BY

Kelly Reschny



HOSPITAL NAME

BPH Burlington

REFERRING VET

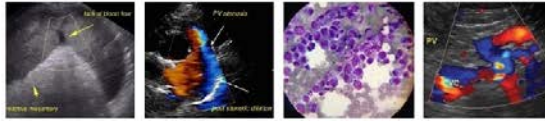
Dr. Ruggieri

INVOICE

39405

DATE

7/12/22



PATIENT

Rocky Sovagovic

SPECIES

Canine

BREED

Beagle X

SEX

Neutered Male

AGE

11 Years

WEIGHT

27.9 kg

INTERPRETED BY

Beth Johnson, DVM
DACVIM

IMAGING PERFORMED BY

Kelly Reschny

HOSPITAL NAME

BPH Burlington

REFERRING VET

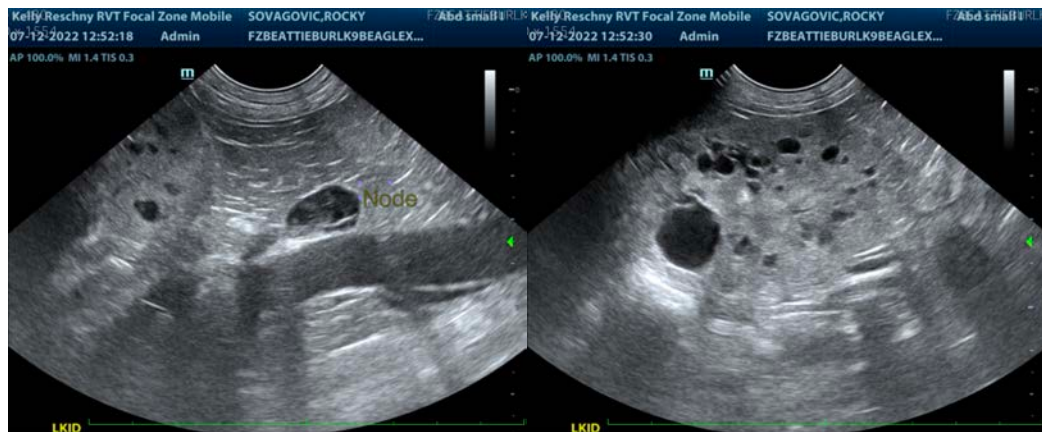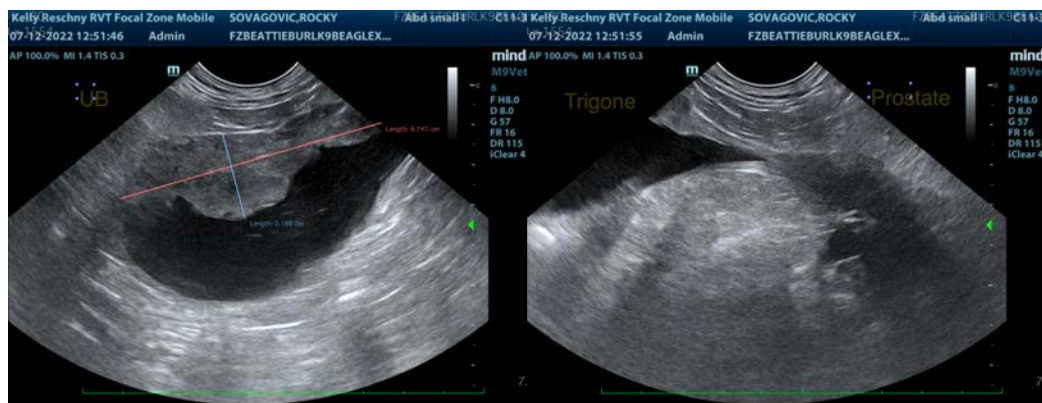
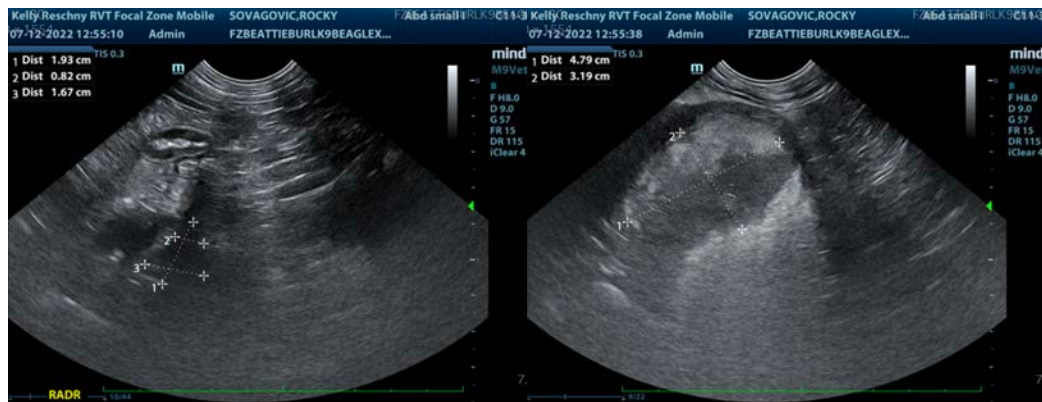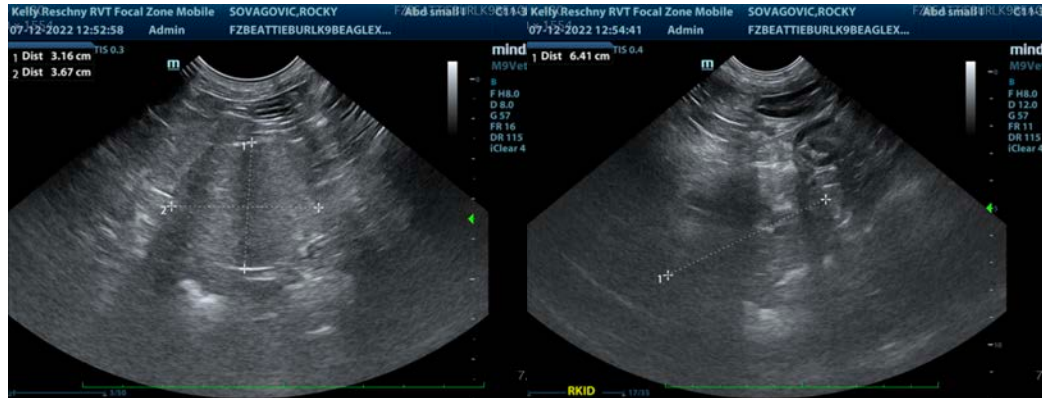
Dr. Ruggieri

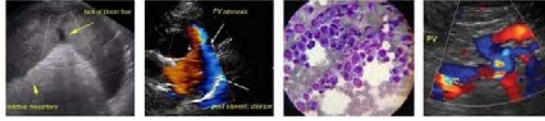
INVOICE

39405

DATE

7/12/22





PATIENT

Rocky Sovagovic

SPECIES

Canine

BREED

Beagle X

SEX

Neutered Male

AGE

11 Years

WEIGHT

27.9 kg

INTERPRETED BY

Beth Johnson, DVM
DACVIM

IMAGING PERFORMED BY

Kelly Reschny

HOSPITAL NAME

BPH Burlington

REFERRING VET

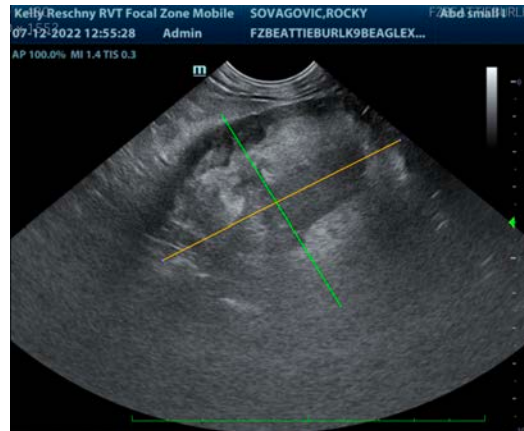
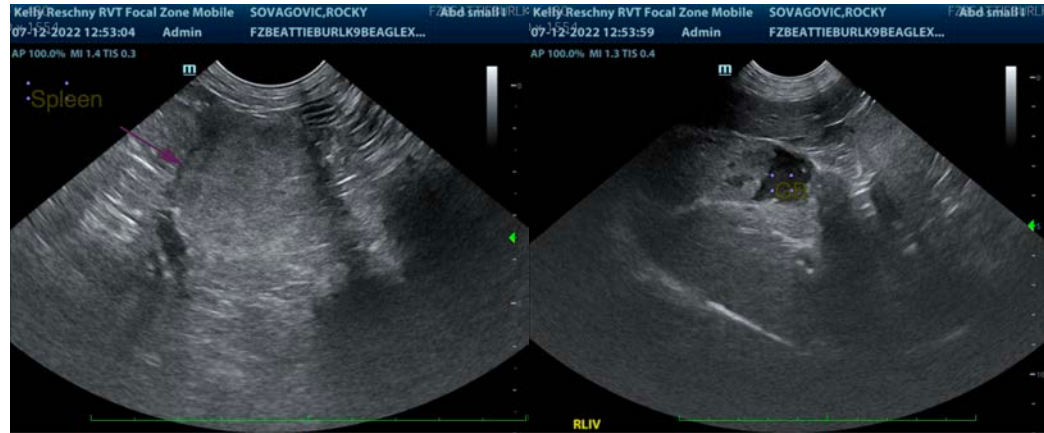
Dr. Ruggieri

INVOICE

39405

DATE

7/12/22



The information and recommendations provided are based on the images presented by the referring veterinarian/sonographer. No evaluation can be communicated regarding pathology that was not visible in the image/video clips provided.

Thank you for this referral. If the clinical or image interpretation does not parallel your findings or if I can be of any further assistance please contact me.

Beth Johnson, DVM, DACVIM
Beth.Johnson@sonopath.com