



PATIENT PRESENTING CLINICAL SIGNS

Coco Guzman

Presented for 3-month recheck abdominal ultrasound. The previous study was performed on 2/6/23 and 11/3/22 and pt has a right adrenal mass. We are monitoring the right adrenal gland mass with recommended ultrasound rechecks. Pt has been doing well at home. Last BW done was November 2022 and it was unremarkable.

SPECIES

Canine

BREED

West Highland White Terrier

SEX

Spayed female

AGE

10 Years

WEIGHT

15.4 Pounds

INTERPRETED BY

Beth Johnson, DVM
DACVIM

IMAGING PERFORMED BY

Dr. G. Ferrer

HOSPITAL NAME

Paseos Vet Center

REFERRING VET

Dr. Ortiz

INVOICE

43884

DATE

7/11/23

ULTRASONOGRAPHIC EXAMINATION OF THE ABDOMEN

Urinary System

The urinary bladder is moderately distended with anechoic contents. No masses, inflammatory changes, echogenic sediment or cystoliths are observed. The urinary bladder, trigone and visible pelvic urethra are normal in thickness with a smooth mucosal surface.

Kidneys are overall normal in size and shape with smooth peripheral margination. A normal 1:3 cortex to medulla ratio is maintained. The medulla and cortices are uniform in texture with some mild increased cortical echogenicity and mild loss of corticomedullary distinction, expected in this age patient. There is no evidence of pyelectasia, mineral or infarcts observed. The left kidney measures 4.14 cm. The right kidney measures 4.67 cm.

Adrenal Glands

The right adrenal gland is normal in size (1.0 cm at the cranial pole and 0.42 cm at the caudal pole), shape and contour. The hyperechoic nodule is still present in the cranial pole, and today measures 1.1 cm x 1.4 cm in size without obvious capsular distention, escape, or vascular invasion. Visible surrounding vasculature appears normal.

The left adrenal gland is normal in size (0.39 cm at the cranial pole and 0.57 cm at the caudal pole), shape and contour. Corticomedullary structure is unremarkable. Visible surrounding vasculature appears normal.

Spleen

The spleen is subjectively normal in size with a normal smooth capsular contour. Parenchyma is appropriately finely textured and homogenous with normal echogenicity relative to surrounding tissue (hyperechoic to liver). No focal nodules or masses are observed. Splenic vasculature appears normal.

Liver

The liver is subjectively normal in size with normal smooth curvilinear peripheral contour. Parenchyma is appropriately hypoechoic to the spleen in echogenicity and appropriately mildly coarse and homogenous in echotexture. No focal lesions are observed. Visible vasculature and biliary tree appear normal without distension or congestion.

Gallbladder is moderately distended with anechoic bile as well as suspended and gravity dependent echogenic debris. The wall is smooth without visible thickening. There is no evidence of cystic or CBD dilation. There is no evidence of effusion or inflammation.

Gastrointestinal

The visible stomach wall is normal in thickness and layering. The lumen of the stomach is mildly distended with very echogenic reverberation artifact from intraluminal gas. There is no evidence of obstruction, foreign material or infiltrative disease; however, complete visualization of far wall is partially inhibited by gas. Pyloric outflow tract appears patent.



PATIENT

Coco Guzman

The visible small intestines are normal in wall thickness and layering (canine duodenum < 0.5 cm and feline duodenum < 0.4 cm; other < 0.3 cm). Small intestinal motility appears adequate (1-3 contractions per min). The lumen of the small intestine is empty with no evidence of obstruction, foreign material or infiltrative disease.

SPECIES

Canine

The visible colon is normal in wall thickness (< 0.2 cm) and layering. Contents are consistent with normal formed feces and gas.

BREED

Pancreas

West Highland White
Terrier

The observed pancreas appears appropriately isoechoic to surrounding omental fat. The capsule is mildly irregular in shape. Parenchyma is mildly heterogenous and coarse. There is no visible pancreatic duct dilation. There is no evidence of active peripancreatic inflammation.

SEX

Spayed female

Free Abdomen

AGE

10 Years

There is no evidence of free peritoneal effusion noted in these images.

There is no apparent lymphadenopathy noted in these images.

WEIGHT

15.4 Pounds

The previously described cystic structure in the cranial abdomen is still present and measures 0.50 cm x 0.80 cm in size.

PRIMARY FINDINGS

- Hyperechoic adrenal nodule (cranial pole right adrenal gland) – Differentials include primary adrenal cortical adenoma or adenocarcinoma, pheochromocytoma, myelolipoma, adrenal hyperplasia secondary to pituitary disease or metastatic disease. Ultrasound alone cannot differentiate between functional and non-functional nodules and/or between benign and malignant disease. Small nodules without other evidence of abdominal disease (to suggest metastatic disease) and/or clinical signs (to suggest adrenal disease) are most often incidental and should be monitored. This nodule has progressed slightly in size.

INTERPRETED BY

Beth Johnson, DVM
DACVIM

SECONDARY FINDINGS

- Mild gallbladder debris - Cholecystic debris is of unknown clinical significance. It can be seen with biliary stasis from fasting or illness. Cholecystic debris is not necessarily related to hepatobiliary disease. Echogenic bile is most commonly an incidental finding in dogs and should be interpreted in combination with clinical signs such as nausea, inappetence, cranial abdominal discomfort and/or laboratory changes such as increased ALP and/or increased Tbili.
- Age related kidney changes
- Pancreatic age-related remodeling – Mild irregularities are consistent with benign age-related change. Low-grade smoldering chronic pancreatitis cannot be ruled out and should be suspected in the face of appropriate clinical signs.
- Cystic structure in the cranial abdomen – Trends in appearance towards benign with a much lower possibility of emerging neoplasia/malignancy, and has not significantly changed since the previous exam.

IMAGING PERFORMED BY

Dr. G. Ferrer

HOSPITAL NAME

Paseos Vet Center

REFERRING VET

Dr. Ortiz

INVOICE

43884

DATE

7/11/23



PATIENT

Coco Guzman

SPECIES

Canine

BREED

West Highland White Terrier

SEX

Spayed female

AGE

10 Years

WEIGHT

15.4 Pounds

INTERPRETED BY

Beth Johnson, DVM
DACVIM

IMAGING PERFORMED BY

Dr. G. Ferrer

HOSPITAL NAME

Paseos Vet Center

REFERRING VET

Dr. Ortiz

INVOICE

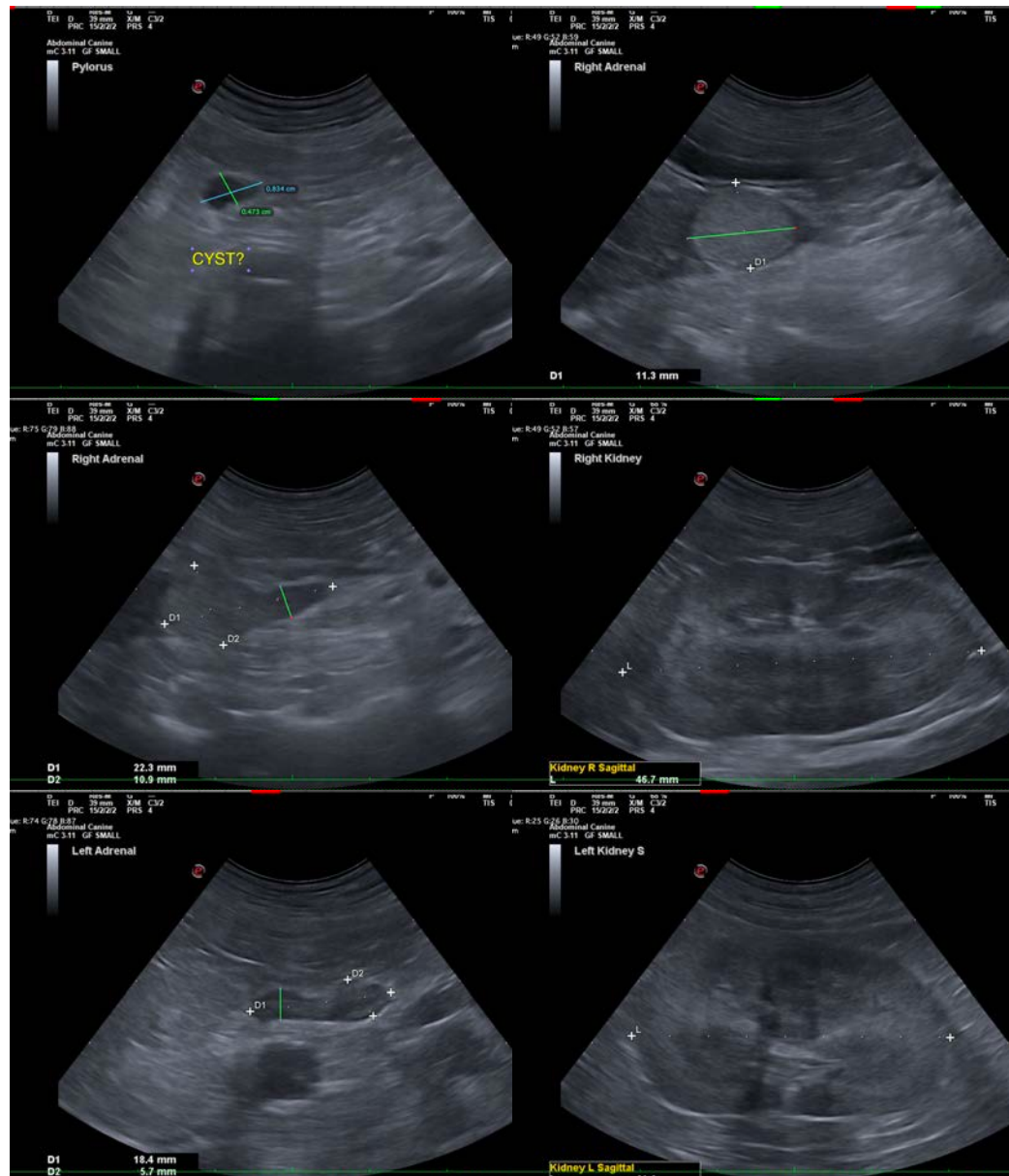
43884

DATE

7/11/23

INTERPRETATION OF THE FINDINGS & FURTHER RECOMMENDATIONS

Given the mild progression in the adrenal nodule, if patient has clinical signs of hyperadrenocorticism, testing could be considered, beginning with a low-dose Dexamethasone suppression test. Without supporting clinical signs, continued monitoring is an appropriate plan until if/when clinical signs do develop. Regardless of clinical signs, however, if not recently evaluated, a urinalysis and, if indicated based on urinalysis results, urine culture are recommended. If protein is present in an otherwise quiet sediment, protein quantification with a urine protein to creatinine ration is recommended. A blood pressure is also recommended.





PATIENT

Coco Guzman

SPECIES

Canine

BREED

West Highland White
Terrier

SEX

Spayed female

AGE

10 Years

WEIGHT

15.4 Pounds

INTERPRETED BY

Beth Johnson, DVM
DACVIM

**IMAGING
PERFORMED BY**

Dr. G. Ferrer

HOSPITAL NAME

Paseos Vet Center

REFERRING VET

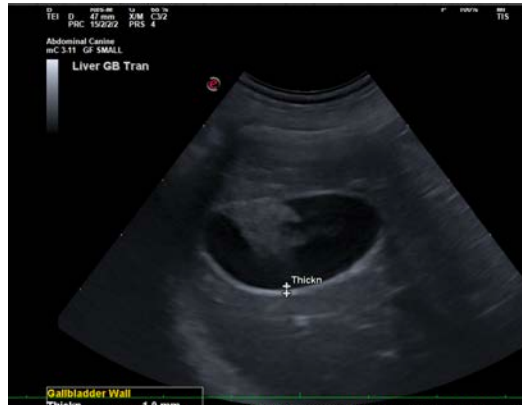Dr. Ortiz

INVOICE

43884

DATE

7/11/23



The information and recommendations provided are based on the images presented by the referring veterinarian/sonographer. No evaluation can be communicated regarding pathology that was not visible in the image/video clips provided.

Thank you for this referral. If the clinical or image interpretation does not parallel your findings or if I can be of any further assistance please contact me.

Beth Johnson, DVM, DACVIM
info@sonopath.com