

**DATE PRESENTING CLINICAL SIGNS**

7/11/23

Recent history of insulinoma with surgical resection in April. Surgeon was able to get primary tumor but not abdominal LN and nodules in liver confirmed mets via biopsies. Pet has been on steroids since surgery and was on a 1 month course of palladia. Been off it for about a month. Glucose has been monitored continuously and pet has gone from 4 daily feedings back to 2-3 with good regulation of BG since surgery and even off palladia. Suspect partial remission. Also recent diagnosis of melanoma on lip. Removed last week. Long term history with food allergy and mild episodes of pancreatitis. Arthritis in spine. Grade 3/6 heart murmur with stable disease.

PATIENT

Apollo Skevakis

SPECIES

Canine

BREED

Pit Bull

SEX

Neutered Male

AGE

6/1/09

WEIGHT

45 Pounds

INTERPRETED BYBeth Johnson, DVM
DACVIM**HOSPITAL NAME**

Homeward Bound

REFERRING VET

Dr. Skevakis

INVOICE

43901

ULTRASONOGRAPHIC EXAMINATION OF THE ABDOMEN**Urinary System**

The urinary bladder was adequately distended with primarily anechoic contents as well as some echogenic suspended debris. No distinct cystoliths are observed. Within the distal trigone, extending approximately 4.0 cm into the urethra, there is a heterogeneous, irregular, echogenic, vascular, partially mineralized tissue density/mass.

The prostate is difficult to fully differentiate from the tissue/mass within the proximal urethra.

The right kidney is normal in size (6.62 cm), shape and echogenicity. It has smooth peripheral margination. There is a normal 1:3 cortex to medulla ratio with appropriate corticomedullary distinction. There is no evidence of pyelectasia, mineral or infarcts observed. Small, <1.0 cm cortical cysts noted.

The left kidney is normal in size (6.82 cm), shape and echogenicity. It has smooth peripheral margination. There is a normal 1:3 cortex to medulla ratio with appropriate corticomedullary distinction. There is no evidence of pyelectasia, mineral or infarcts observed. Small, <1.0 cm cortical cysts noted.

Adrenal Glands

Adrenal glands are small (flattened contour). Corticomedullary structure is unremarkable. Visible surrounding vasculature appears normal. The left adrenal gland measures 0.74 cm at the cranial pole and 0.75 cm at the caudal pole. The right adrenal gland measures 0.48 cm at the cranial pole and 0.53 cm at the caudal pole.

Spleen

Spleen is subjectively normal in size with a normal smooth capsular contour. Parenchyma is appropriately finely textured and homogenous with normal echogenicity relative to surrounding tissue (hyperechoic to liver). Multifocal well-demarcated hyperechoic homogenous nodules are noted. Splenic vasculature appears normal.

Liver

Liver is subjectively enlarged with mildly irregular margins. Parenchyma is mottled by multifocal discrete hypoechoic nodules of varying sizes "moth-eaten". Most of the nodules are approximately 1.5 cm in diameter, the largest of which measures 2.5 cm x 3.0 cm. Visible vasculature and biliary tree appear normal without distension or congestion.

The gallbladder is non-distended in size. The wall is smooth without visible thickening. Luminal contents are primarily anechoic. There is no evidence of cystic or common bile duct dilation.

Gastrointestinal

The visible stomach wall is normal in thickness and layering. The lumen of the stomach is mildly distended with echogenic non-shadowing luminal contents and gas consistent with normal ingesta. There is no evidence of obstruction, foreign material or infiltrative disease. Pyloric outflow tract appears patent.

The visible small intestines are normal in wall thickness and layering. Small intestinal motility appears adequate (1-3 contractions per min). The lumen of the small intestine is mildly distended with echogenic non-shadowing luminal contents and gas consistent with normal ingesta. There is no evidence of obstruction, foreign material or infiltrative disease.

The visible colon is normal in wall thickness (< 0.2 cm) and layering. Contents are consistent with normal formed feces and gas.

Pancreas

The pancreatic parenchyma is appropriately isoechoic to surrounding tissue. Visible capsule is smooth and normal in contour. There is no visible pancreatic duct dilation. There is no evidence of active peripancreatic inflammation.

Free Abdomen

There is a trace amount of free fluid adjacent to the spleen.

In the mid abdomen, near the root of the mesentery, there is a 3.7 cm x 6.3 cm, heterogeneous, vascular mass, presumably a lymph node.

PRIMARY FINDINGS

- The nodular liver is most concerning for metastatic disease, given this patient's history.
- The enlarged mesenteric lymph node is suggestive of a metastatic node.
- The urethral mass is additionally concerning for infiltrative neoplasia. Having said that, benign inflammatory disease cannot be ruled out without additional information.

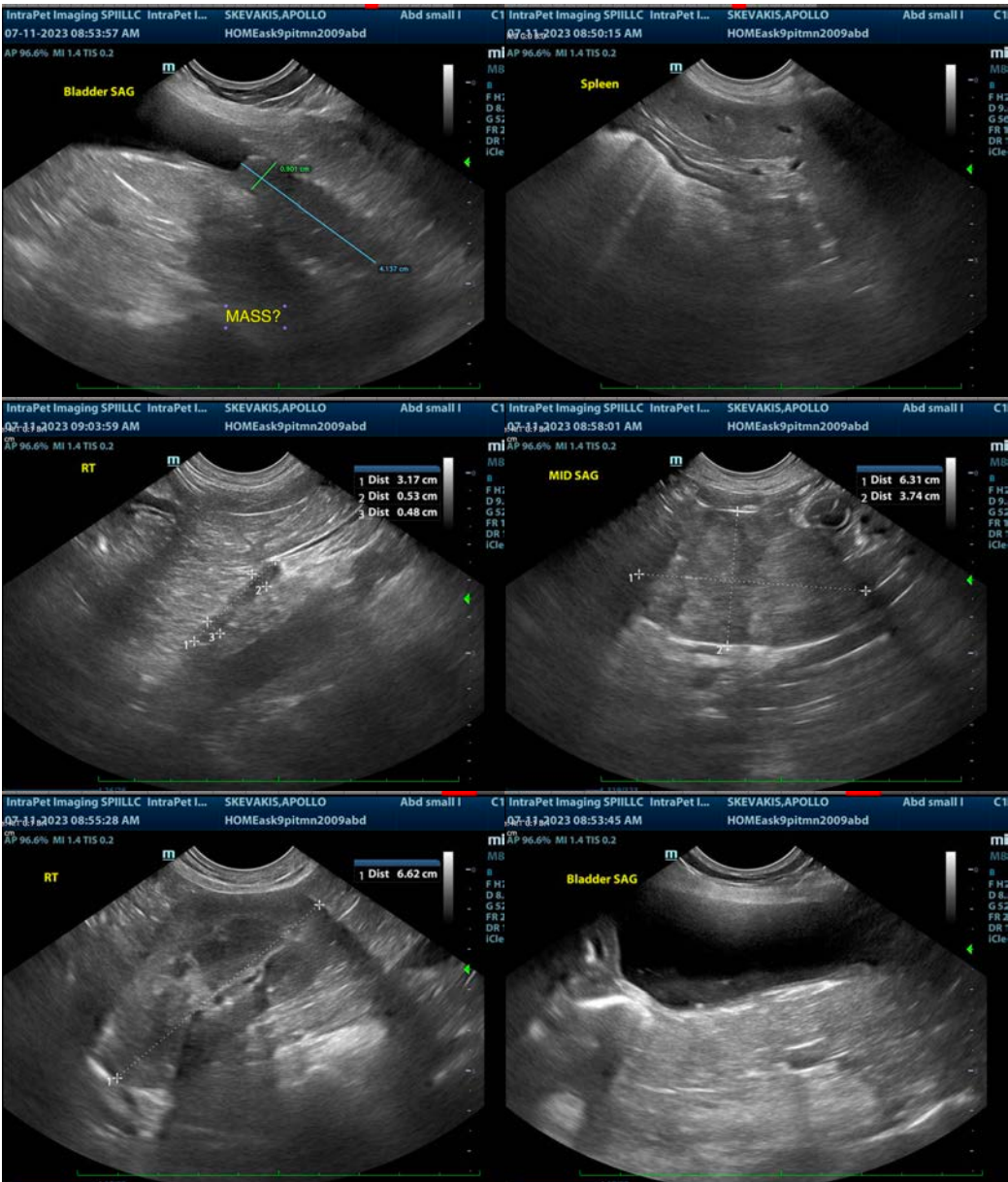
SECONDARY FINDINGS

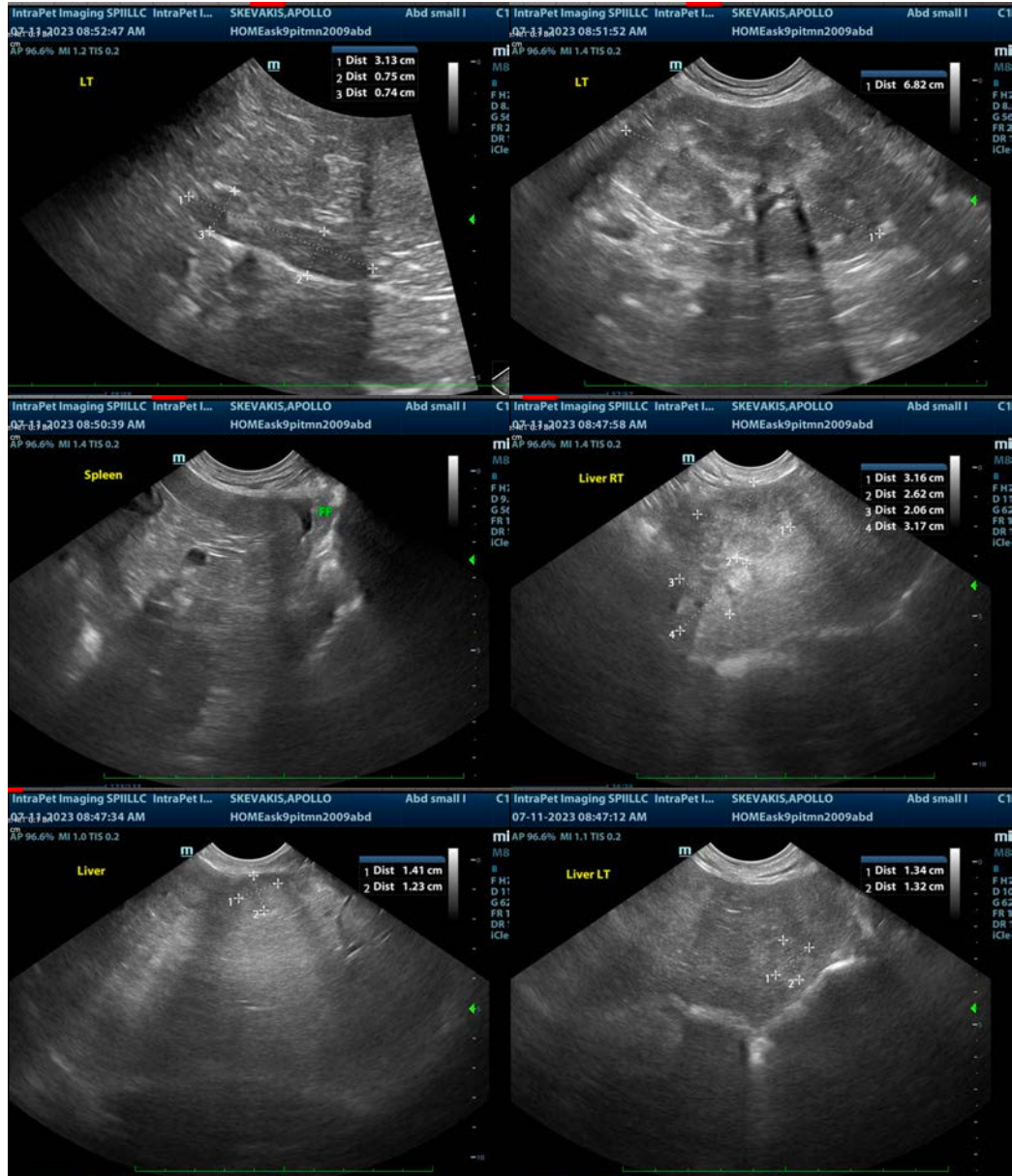
- Bilateral renal cortical cysts
- Flat adrenal glands – likely secondary to this patient's steroid administration.
- Hyperechoic splenic nodules – most consistent with benign myelolipomas. Other differentials such as fibrosis or calcification caused by old hematomas or infarcts, chronic inflammation, granulomatous disease or metastatic disease cannot be ruled out, but are considered less likely.

INTERPRETATION OF THE FINDINGS & FURTHER RECOMMENDATIONS

Given this patient's history, this imaging may simply be for staging and monitoring. However, if confirmation of the etiology of the liver nodules and enlarged lymph node is desired, fine needle aspirates could be considered if patient's coagulation status is appropriate.

Urinalysis and urine culture, if indicated based on urinalysis results, are recommended. Submission of urine to look for BRAF gene mutation, which is associated with urinary bladder cancer, could be considered. Other diagnostic options include traumatic catheterization, fine needle aspirate (with small risk of tumor seeding/trailing) or cystoscopy for further sampling.





The information and recommendations provided are based on the images presented by the referring veterinarian/sonographer. No evaluation can be communicated regarding pathology that was not visible in the image/video clips provided.

Thank you for this referral. If the clinical or image interpretation does not parallel your findings or if I can be of any further assistance please contact me.

Beth Johnson, DVM, DACVIM
 info@sonopath.com