



PATIENT

Abby Cline

SPECIES

Canine

BREED

Aussie Shepherd

SEX

Spayed Female

AGE

10 Years

WEIGHT

19.3 kg

INTERPRETED BY

Beth Johnson, DVM
DACVIM

IMAGING PERFORMED BY

Dave Stasiuk, RDMS,
RDCS

HOSPITAL NAME

Alpine 24/7

REFERRING VET

Alpine 24/7

INVOICE

43916

DATE

7/11/23

PRESENTING CLINICAL SIGNS

Anal gland mass. Assess for abdominal metastases.

ULTRASONOGRAPHIC EXAMINATION OF THE ABDOMEN

Urinary System

Urinary bladder is adequately distended. It has a normal uniform wall thickness. Contents include primarily anechoic fluid with occasional echogenic non-shadowing debris, most consistent with exfoliated cells, mucous and/or small blood clots. Both sterile inflammation as well as urinary tract infection can also present with echogenic debris. No masses or cystoliths are observed. The trigone and visible pelvic urethra are normal in thickness with a smooth mucosal surface.

The right kidney is normal in size (6.34 cm), shape and echogenicity. It has smooth peripheral margination. There is a normal 1:3 cortex to medulla ratio with appropriate corticomedullary distinction. There is no evidence of pyelectasia, mineral or infarcts observed.

The left kidney is normal in size (5.87 cm), shape and echogenicity. It has smooth peripheral margination. There is a normal 1:3 cortex to medulla ratio with appropriate corticomedullary distinction. There is no evidence of pyelectasia, mineral or infarcts observed.

Adrenal Glands

The area of the right adrenal gland is examined without evident adrenal gland pathology.

The left adrenal gland is normal in size (0.43 cm at the cranial pole and 0.44 cm at the caudal pole), shape and contour. Corticomedullary structure is unremarkable. Visible surrounding vasculature appears normal.

Spleen

The spleen is subjectively normal in size with a normal smooth capsular contour. Parenchyma is appropriately finely textured and homogenous with normal echogenicity relative to surrounding tissue (hyperechoic to liver). No focal nodules or masses are observed. Splenic vasculature appears normal.

Liver

The liver is subjectively normal in size with normal smooth curvilinear peripheral contour. Parenchyma is appropriately hypoechoic to the spleen in echogenicity and appropriately mildly coarse and homogenous in echotexture. No focal lesions are observed. Visible vasculature and biliary tree appear normal without distension or congestion.

Gallbladder is moderately distended with anechoic bile as well as suspended and gravity dependent echogenic debris. The wall is smooth without visible thickening. There is no evidence of cystic or CBD dilation. There is no evidence of effusion or inflammation.

Gastrointestinal

The stomach wall is normal in thickness (canine < 0.5 cm and feline < 0.4 cm) and layering. The lumen of the stomach is empty with no evidence of obstruction, foreign material or infiltrative disease. Pyloric outflow tract appears patent.



PATIENT

Abby Cline

SPECIES

Canine

BREED

Aussie Shepherd

SEX

Spayed Female

AGE

10 Years

WEIGHT

19.3 kg

INTERPRETED BY

Beth Johnson, DVM
DACVIM

IMAGING PERFORMED BY

Dave Stasiuk, RDMS,
RDCS

HOSPITAL NAME

Alpine 24/7

REFERRING VET

Alpine 24/7

INVOICE

43916

DATE

7/11/23

The visible small intestines are normal in wall thickness and layering (canine duodenum < 0.5 cm and feline duodenum < 0.4 cm; other < 0.3 cm). Small intestinal motility appears adequate (1-3 contractions per min). The lumen of the small intestine is empty with no evidence of obstruction, foreign material or infiltrative disease.

The visible colon is normal in wall thickness (< 0.2 cm) and layering. Contents are consistent with normal formed feces and gas.

Pancreas

The pancreatic parenchyma is appropriately isoechoic to surrounding tissue. Visible capsule is smooth and normal in contour. There is no visible pancreatic duct dilation. There is no evidence of active peripancreatic inflammation.

Free Abdomen

There is no evidence of free peritoneal effusion noted in these images.

There is no apparent lymphadenopathy noted in these images.

ULTRASONOGRAPHIC FINDINGS

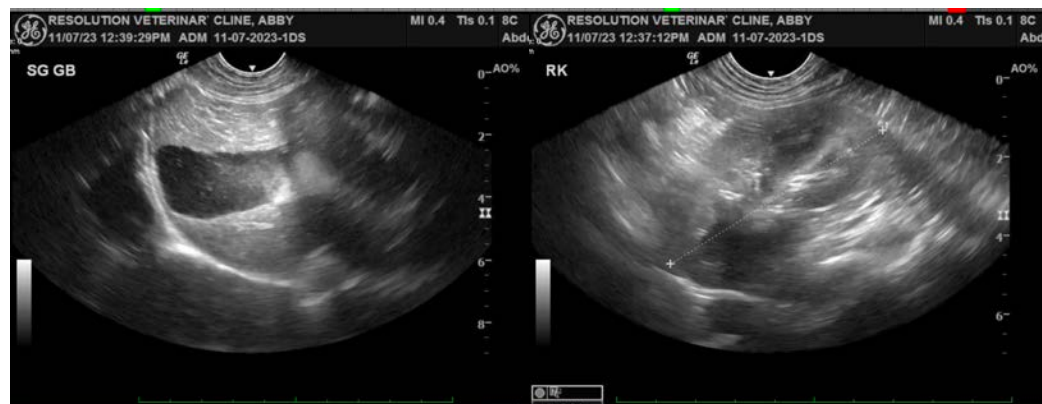
- Subtle urinary bladder debris
- Mild gallbladder debris - Cholecystic debris is of unknown clinical significance. It can be seen with biliary stasis from fasting or illness. Cholecystic debris is not necessarily related to hepatobiliary disease. Echogenic bile is most commonly an incidental finding in dogs and should be interpreted in combination with clinical signs such as nausea, inappetence, cranial abdominal discomfort and/or laboratory changes such as increased ALP and/or increased Tbili.
- Otherwise, this is a relatively unremarkable/normal abdomen without any ultrasonographically visible intraabdominal evidence of metastatic disease in these images at this time.

INTERPRETATION OF THE FINDINGS & FURTHER RECOMMENDATIONS

If not recently evaluated, a general metabolic health screen is recommended in the form of CBC/Chem panel, electrolytes, and urinalysis.

Three view thoracic radiographs are recommended for further assessment of cardio-pulmonary status as well as to further evaluate for any evidence of metastatic disease, if not recently evaluated.

Pending results, surgical excision of the reportedly palpable anal sac mass could be considered.





PATIENT

Abby Cline

SPECIES

Canine

BREED

Aussie Shepherd

SEX

Spayed Female

AGE

10 Years

WEIGHT

19.3 kg

INTERPRETED BY

Beth Johnson, DVM
DACVIM

IMAGING PERFORMED BY

Dave Stasiuk, RDMS,
RDCS

HOSPITAL NAME

Alpine 24/7

REFERRING VET

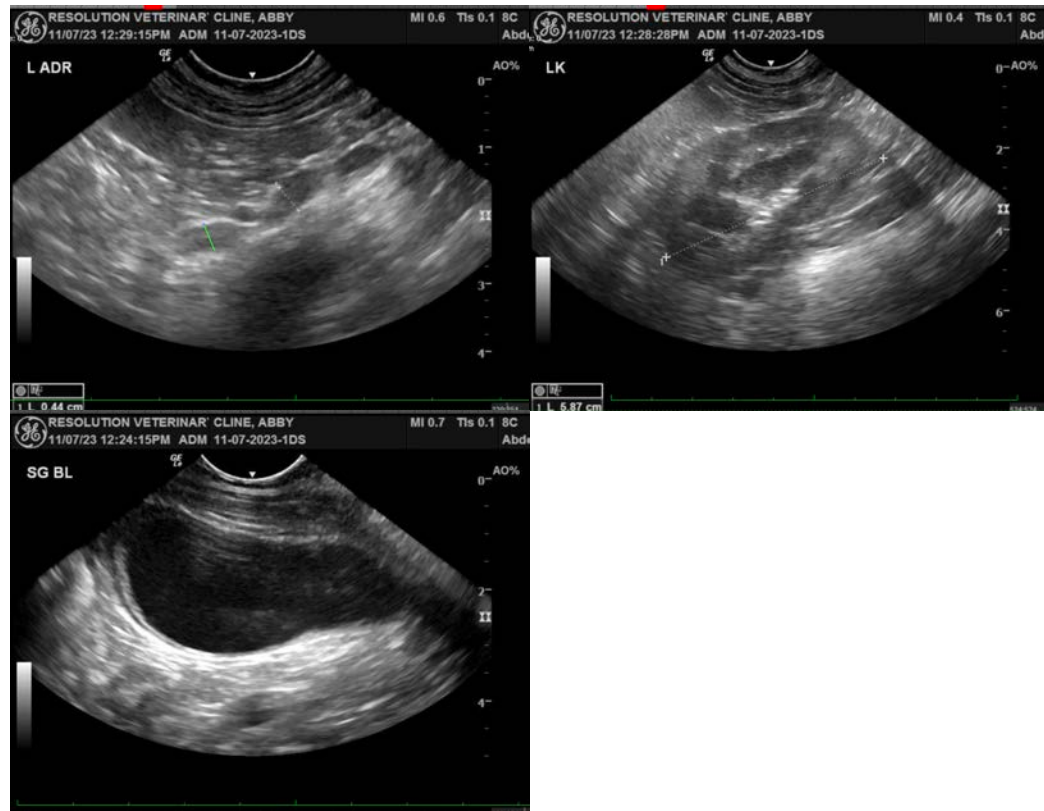
Alpine 24/7

INVOICE

43916

DATE

7/11/23



The information and recommendations provided are based on the images presented by the referring veterinarian/sonographer. No evaluation can be communicated regarding pathology that was not visible in the image/video clips provided.

Thank you for this referral. If the clinical or image interpretation does not parallel your findings or if I can be of any further assistance please contact me.

Beth Johnson, DVM, DACVIM
info@sonopath.com