

**DATE PRESENTING CLINICAL SIGNS**

7/11/22 Was diagnosed as stage 3 kidney disease with two days on fluids was able to bring number down to a more normal level, Saturday presented with a fever and pale mucus membrane, SDMA still high, did abdominal x ray and Dr was concerned for possible fluid in abdomen and enlarge spleen. also is Hypertensive.

PATIENT

Stella LaRuffa Current Medications: Enapril 10mg 1 tablet BID, Clavamox 375mg 1 tablet BID.

Lab Results: See attached.

Radiographs: See attached.

SPECIES

Date of Previous IntraPet Ultrasound: No previous.

Canine

Sedation: Not required to complete full diagnostic ultrasound.

Stat Report: Stat requested.

BREED**ULTRASONOGRAPHIC EXAMINATION OF THE ABDOMEN**

German Shepherd

Urinary System

The urinary bladder is moderately distended with anechoic contents. No masses, inflammatory changes, echogenic sediment or cystoliths are observed. The urinary bladder, trigone and visible pelvic urethra are normal in thickness with a smooth mucosal surface.

SEX

Spayed Female

AGE

12/17/12

The right kidney is normal in size (7.29 cm), shape and echogenicity. It has smooth peripheral margination. There is a normal 1:3 cortex to medulla ratio with appropriate corticomedullary distinction. There is no evidence of pyelectasia or infarcts observed. Non-obstructive linear multifocal hyperechoic diverticular foci with acoustic shadowing are noted.

WEIGHT

73.4 Pounds

The left kidney is normal in size (7.36 cm), shape and echogenicity. It has smooth peripheral margination. There is a normal 1:3 cortex to medulla ratio with appropriate corticomedullary distinction. There is no evidence of pyelectasia or infarcts observed. Non-obstructive linear multifocal hyperechoic diverticular foci with acoustic shadowing are noted.

INTERPRETED BY

Beth Johnson, DVM
DACVIM

Adrenal Glands

The right adrenal gland is normal in size (2.2 cm long x 1.1 cm at the cranial pole and 0.99 cm at the caudal pole), shape and contour. Corticomedullary structure is unremarkable. Visible surrounding vasculature appears normal.

IMAGING PERFORMED BY

Rachel Brilhart RDMS

The left adrenal gland is normal in size (3.0 cm long x 0.70 cm at the cranial pole and 0.80 cm at the caudal pole), shape and contour. Corticomedullary structure is unremarkable. Visible surrounding vasculature appears normal.

HOSPITAL NAME

Aberdeen Vet Clinic

Spleen

The spleen is composed of multiple heterogeneous cavitated masses that completely disrupt normal architecture.

REFERRING VET

Dr. Fritz

Liver

The liver is subjectively enlarged with mildly irregular margins. Parenchyma is heterogenous characterized by multiple poorly defined hypoechoic nodules within otherwise hyperechoic liver parenchyma. Visible vasculature and biliary tree appear normal without distension or congestion.

INVOICE

39381

The gallbladder is moderately distended with anechoic bile as well as suspended and gravity dependent echogenic debris. The wall is smooth without visible thickening. There is no evidence of cystic or CBD dilation. There is no evidence of effusion or inflammation.

Gastrointestinal

The stomach wall is normal in thickness (canine < 0.5 cm and feline < 0.4 cm) and layering. The lumen of the stomach is mildly distended with very echogenic reverberation artifact from intraluminal gas. There is no evidence of obstruction, foreign material or infiltrative disease; however, complete visualization of far wall is partially inhibited by gas. Pyloric outflow tract appears patent.

The visible small intestines are normal in wall thickness and layering (canine duodenum < 0.5 cm and feline duodenum < 0.4 cm; other < 0.3 cm). Small intestinal motility appears adequate (1-3 contractions per min). The lumen of the small intestine is empty with no evidence of obstruction, foreign material or infiltrative disease.

The visible colon is normal in wall thickness (< 0.2 cm) and layering. Contents are consistent with normal formed feces and gas.

Pancreas

The pancreatic parenchyma is appropriately isoechoic to surrounding tissue. Visible capsule is smooth and normal in contour. There is no visible pancreatic duct dilation. There is no evidence of active peripancreatic inflammation.

Free Abdomen

There is a large amount of anechoic free fluid in the abdomen. No evidence of metastatic cardiac involvement based on these images.

There is no apparent lymphadenopathy noted in these images.

PRIMARY FINDINGS

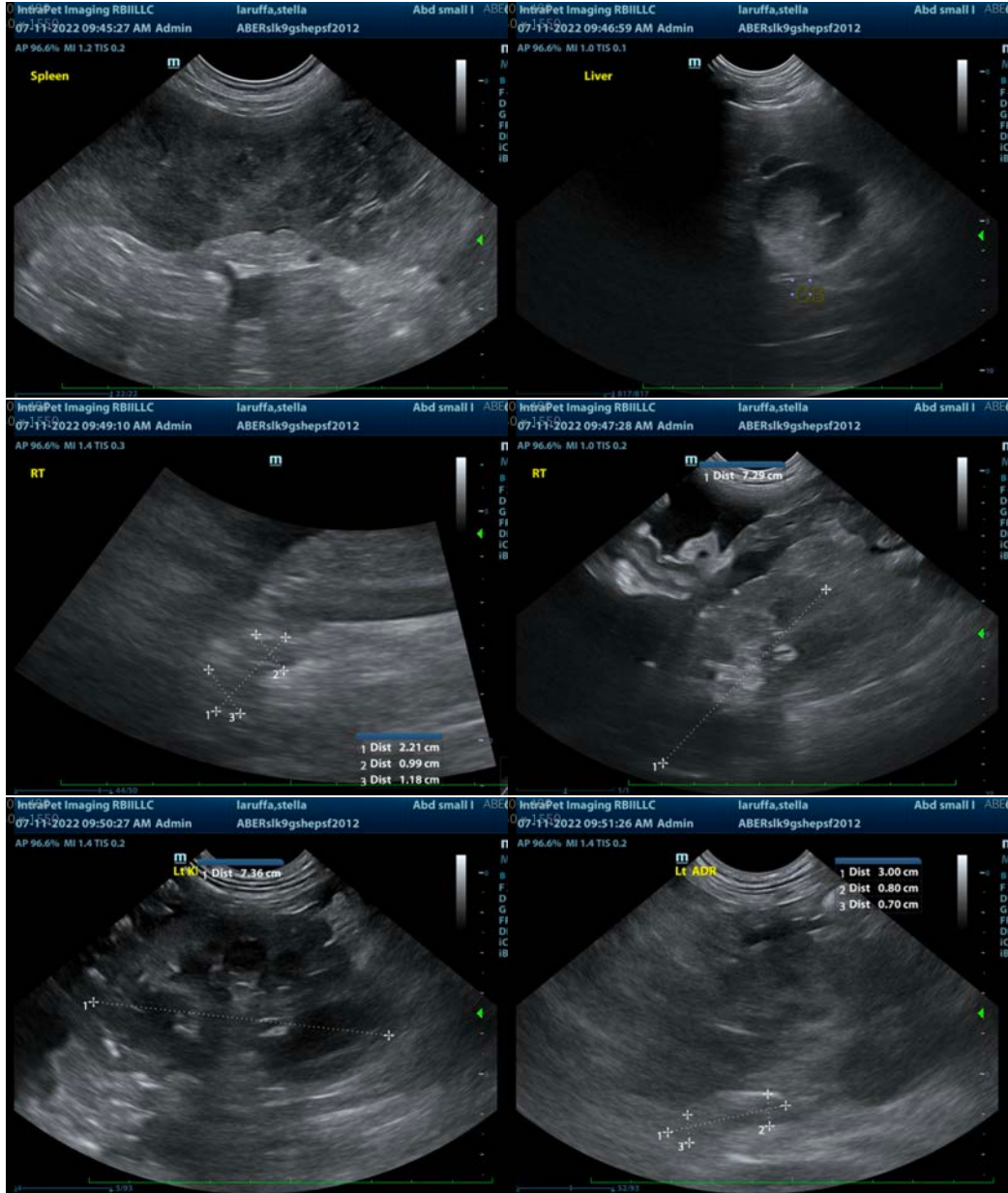
- Multiple cavitated capsule disrupting splenic masses – most concerning for infiltrative neoplasia such as hemangiosarcoma with associated free fluid suspected to be hemoabdomen.
- Heterogenous Liver – These changes are often most consistent with a benign process such as nodular hyperplasia, steroid or vacuolar hepatopathy, extramedullary hematopoiesis, etc. There are no obvious cavitated masses, etc. to suggest definitive metastatic disease. However, with this appearance, metastatic disease cannot be definitively ruled out.

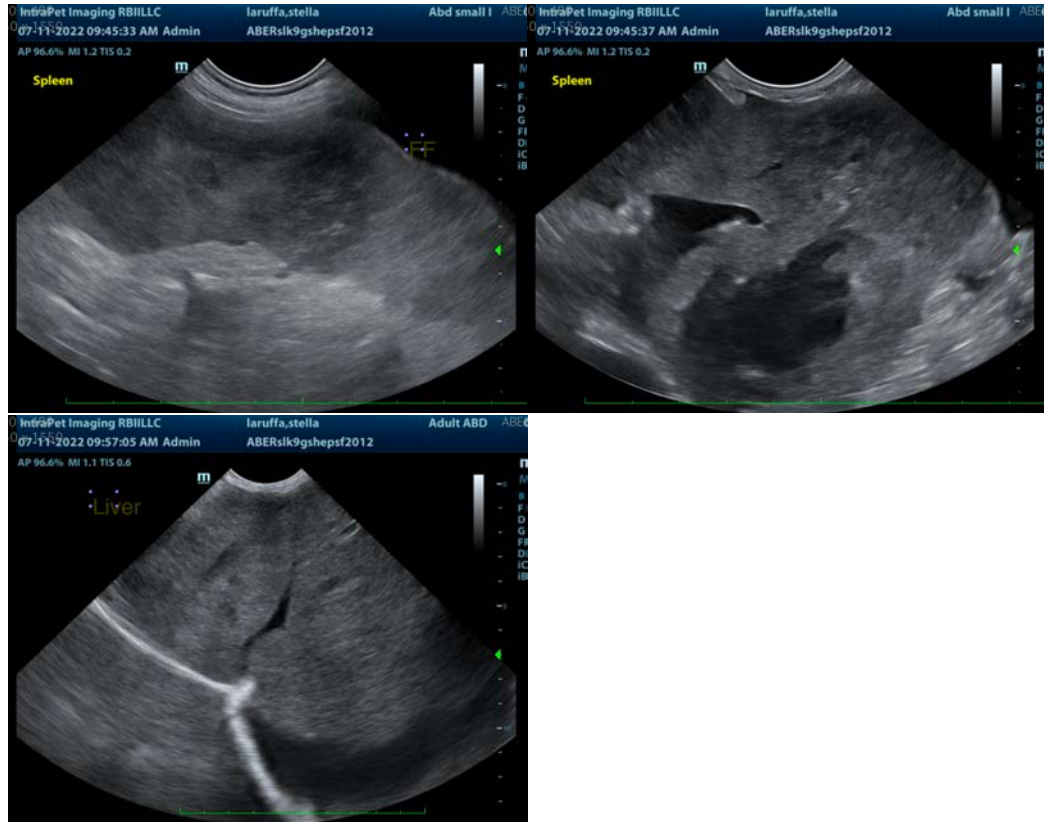
SECONDARY FINDINGS

- Gallbladder debris – Cholecystic debris is of unknown clinical significance. It can be seen with biliary stasis from fasting or illness. Cholecystic debris is not necessarily related to hepatobiliary disease. Echogenic bile is most commonly an incidental finding in dogs and should be interpreted in combination with clinical signs such as nausea, inappetence, cranial abdominal discomfort and/or laboratory changes such as increased ALP and/or increased Tbili.

INTERPRETATION OF THE FINDINGS & FURTHER RECOMMENDATIONS

- Three view thoracic radiographs are recommended for further assessment of cardio-pulmonary status as well as to further evaluate for any evidence of metastatic disease, if not recently evaluated.
- Exploratory laparotomy for a splenectomy and, if indicated based on surgical evaluation, liver biopsy, is recommended.





The information and recommendations provided are based on the images presented by the referring veterinarian/sonographer. No evaluation can be communicated regarding pathology that was not visible in the image/video clips provided.

Thank you for this referral. If the clinical or image interpretation does not parallel your findings or if I can be of any further assistance please contact me.

Beth Johnson, DVM, DACVIM
Beth.Johnson@sonopath.com