SonoPath
Clinical Sonography & Telecytology

EDUCATIONAL TELECONSULTATION SERVICES™

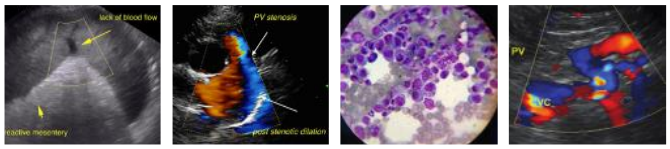

SonoPath.com
1-800-838-4268 info@sonopath.com

PATIENT
Skylar Kellar

SPECIES
Canine

BREED
Lab Mix

SEX
Soayed Female

AGE
11 Years 4 Months

WEIGHT
60 Pounds

INTERPRETED BY
Beth Johnson, DVM DACVIM

IMAGING PERFORMED BY
Amy Mayhew, LVT

HOSPITAL NAME
SVS Imaging MI

REFERRING VET
Union Lake VH

INVOICE
16578

DATE
7/11/22

PRESENTING CLINICAL SIGNS

History: Concern for progressive ckd. Recommend continue k/d diet and amlodipine given poor concentration (usg 1.011) and elevations progressing. Recently vaccinated for lepto. Acting "off" per O the past month. Denamarin started 7/7/22.

Abnormal PE/Chem/CBC/UA Results: sdma h 17 (persistently elevated) creat H 1.6 alt H 144, alp H 338 (new findings) rest of cbc/chem wnl

ULTRASONOGRAPHIC EXAMINATION OF THE ABDOMEN

Urinary System

Urinary bladder is adequately distended with anechoic contents. No masses, inflammatory changes, echogenic sediment or cystoliths are observed. The urinary bladder, trigone and visible pelvic urethra are normal in thickness with a smooth mucosal surface.

Left kidney is normal in size (5.94 cm) and contour. A relatively uniform hyperechogenicity is observed with mildly decreased corticomedullary distinction. There is no pyelectasia noted and no mineral is observed. No overt masses/nodules are observed. Perinephric/subcapsular anechoic area noted, consistent with fluid is noted around the left kidney.

Right kidney is normal in size (6.19 cm) and contour. A relatively uniform hyperechogenicity is observed with mildly decreased corticomedullary distinction. There is no pyelectasia noted and no mineral is observed. No overt masses/nodules are observed. There is a hypoechoic perinephric rim.

Adrenal Glands

Left adrenal gland is unable to be visualized.

Right adrenal gland is normal in size (0.74 cm at cranial pole and 0.66 cm at caudal pole), shape and overall architecture, echogenicity and echotexture. Visible surrounding vasculature appears normal.

Spleen

Spleen is subjectively normal in size with a normal smooth capsular contour. Parenchyma is appropriately finely textured and homogenous with normal echogenicity relative to surrounding tissue (hyperechoic to liver). No focal nodules or masses are observed. Splenic vasculature appears normal.

Liver

Liver is subjectively enlarged with mildly irregular margins. Parenchyma is mottled by multifocal discrete hypoechoic nodules of varying sizes “moth-eaten”. Visible vasculature and biliary tree appear normal without distension or congestion.

Gallbladder is mildly overdistended with a moderate amount of non-dependent, mildly aggregated/inspissated sludge. Hypo to anechoic cystic areas are noted between the gallbladder sludge and luminal wall. The wall is otherwise smooth without visible thickening. There is no evidence of cystic or CBD dilation. There is no evidence of effusion.

Gastrointestinal

The visible stomach wall is normal in thickness and layering. The lumen of the stomach is empty with no evidence of obstruction, foreign material or infiltrative disease. Pyloric outflow tract appears patent.

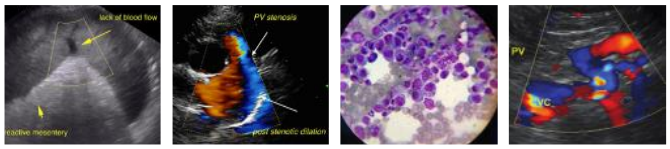

SonoPath.com
1-800-838-4268 info@sonopath.com

PATIENT
Skylar Kellar

SPECIES
Canine

BREED
Lab Mix

SEX
Soayed Female

AGE
11 Years 4 Months

WEIGHT
60 Pounds

INTERPRETED BY
Beth Johnson, DVM DACVIM

IMAGING PERFORMED BY
Amy Mayhew, LVT

HOSPITAL NAME
SVS Imaging MI

REFERRING VET
Union Lake VH

INVOICE
16578

DATE
7/11/22

The visible small intestines are normal in wall thickness and layering. Small intestinal motility appears adequate (1-3 contractions per min). The lumen of the small intestine is empty with no evidence of obstruction, foreign material or infiltrative disease.

The visible colon is normal in wall thickness and layering. Contents are consistent with normal formed feces and gas.

Pancreas

The observed pancreas appears appropriately isoechoic to surrounding omental fat. Visible capsule is smooth and normal in contour. Visible pancreatic parenchyma is homogenous and unremarkable. There is no visible pancreatic duct dilation. There is no evidence of active peripancreatic inflammation.

Free Abdomen

There is no evidence of peritoneal effusion. There is no apparent lymphadenopathy.

ULTRASONOGRAPHIC FINDINGS

- Nodular Liver - This finding is concerning for infiltrative disease such as round cell neoplasia or metastatic neoplasia. Benign disease (nodular hyperplasia) cannot be ruled out but is considered less likely.
- Emerging mucocele – Cholecystic debris is of unknown clinical significance. It can be seen with biliary stasis from fasting or illness. Cholecystic debris is not necessarily related to hepatobiliary disease. The non-dependent nature of this sludge combined with the cystic areas are suggestive, however, of possible emerging cystic mucosal hyperplasia or early gallbladder mucocele.
- Nephritis with bilateral perinephric +/- possible subcapsular fluid – This appearance can be consistent with chronic interstitial nephritis or glomerulonephritis. Toxic insult and/or infectious disease (pyelonephritis, Leptospirosis, etc.) cannot be ruled out. This finding should be interpreted in combination with suspicion for renal disease and/or supporting laboratory or urinalysis changes. The perinephric finding is most consistent with an acute kidney injury as is seen with acute leptospirosis or potentially toxic insult. Rarely in dogs, this finding can be associated with lymphoma. In this patient, given the concurrent liver changes, lymphoma is a concern.

INTERPRETATION OF THE FINDINGS & FURTHER RECOMMENDATIONS

- A fine needle aspirate of the liver is recommended if patients coagulation status is appropriate.
- Testing for Leptospirosis is indicated, despite the patient being current on vaccines. PCR testing could be considered over serology given the recent vaccination, if the patient has not recently seen antibiotics.
- Urinalysis and, if indicated based on urinalysis results, urine culture are recommended. If protein is present in an otherwise quiet sediment, protein quantification with a urine protein to creatinine ration is recommended.
- A blood pressure if recommended if not recently evaluated.

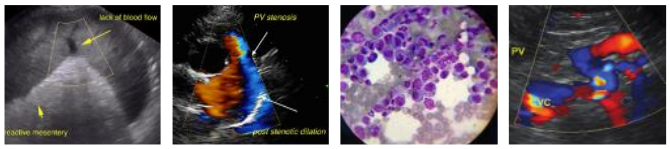

SonoPath.com
1-800-838-4268 info@sonopath.com

PATIENT

Skylar Kellar

SPECIES

Canine

BREED

Lab Mix

SEX

Soayed Female

AGE

11 Years 4 Months

WEIGHT

60 Pounds

INTERPRETED BY

Beth Johnson, DVM
DACVIM

IMAGING PERFORMED BY

Amy Mayhew, LVT

HOSPITAL NAME

SVS Imaging MI

REFERRING VET

Union Lake VH

INVOICE

16578

DATE

7/11/22

In the meantime, pending results, management of a suspect acute kidney insult with broad spectrum antibiotics to address possible Leptospirosis/pyelonephritis, etc., as well as diuresis (if indicated) and supportive management of concurrent clinical signs, such as nausea, etc. is recommended.

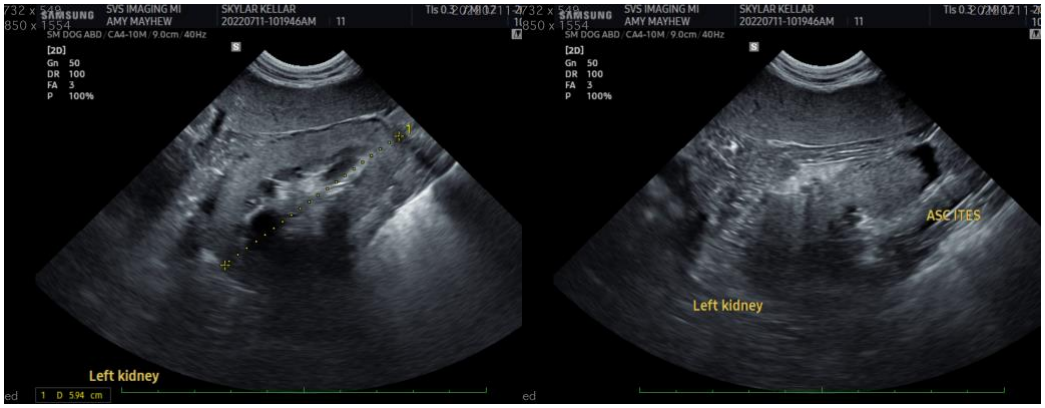

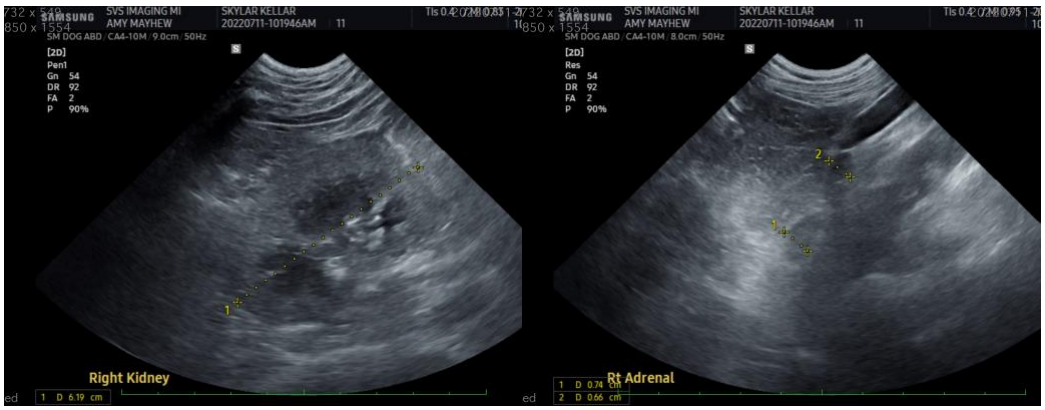

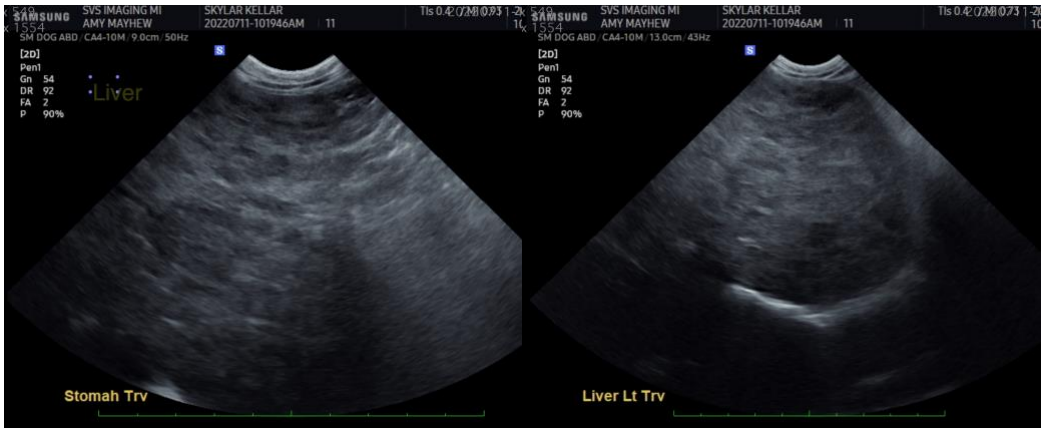

SonoPath

Clinical Sonography & Telecytology

EDUCATIONAL TELECONSULTATION SERVICES™

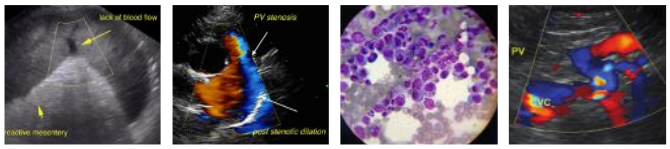

SonoPath.com

1-800-838-4268 info@sonopath.com

PATIENT

Skylar Kellar

SPECIES

Canine

BREED

Lab Mix

SEX

Soayed Female

AGE

11 Years 4 Months

WEIGHT

60 Pounds

INTERPRETED BY

Beth Johnson, DVM DACVIM

IMAGING PERFORMED BY

Amy Mayhew, LVT

HOSPITAL NAME

SVS Imaging MI

REFERRING VET

Union Lake VH

INVOICE

16578

DATE

7/11/22

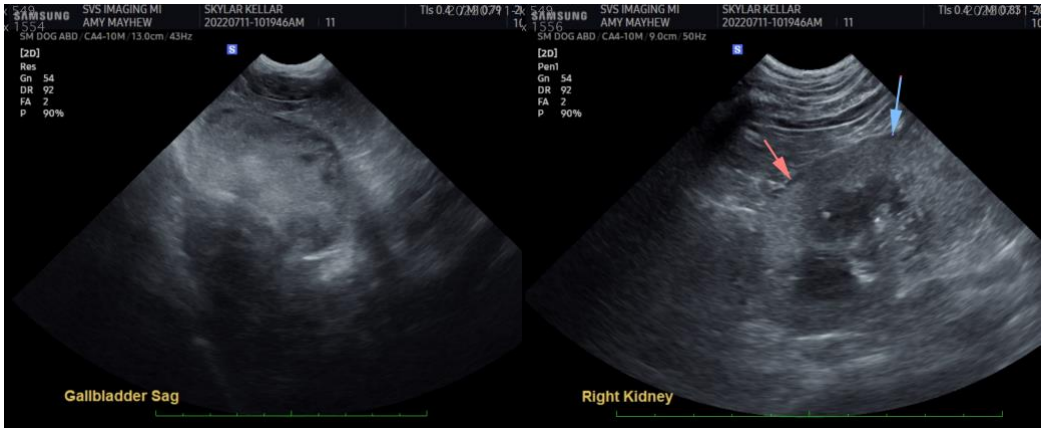

The information and recommendations provided are based on the images presented by the referring veterinarian. No evaluation can be communicated regarding pathology that was not visible in the image/video clips provided.

Thank you for this referral. If the clinical or image interpretation does not parallel your findings or if I can be of any further assistance please contact me.

Beth Johnson, DVM DACVIM

Beth.Johnson@SonoPath.com