**DATE**

7-11-22

PRESENTING CLINICAL SIGNS

Pt presented on 7/7 for anorexia, vomiting, lethargy. PE - pt icteric all over. Scant free fluid in abdomen. Liver values elevated. Pt UTD on leptovaccine (last given 4/2022)

Current Medications: amoxicillin 250 mg BID, metronidazole 375 mg BID

cerenia 24 mg SID

Lab Results: ALP >200, ALT 750, albumin 1.9.

Date of Previous IntraPet Ultrasound: No previous.

Sedation: Not required to complete full diagnostic ultrasound.

Stat Report: Requested/Approved.

Imaging Performed By: Stephanie Pearce RDCS, RVT.

PATIENT

Rosie Kelly

SPECIES

Canine

BREED

Coonhound

SEX

Spayed female

AGE

12/16/17

WEIGHT

53.6 lbs

INTERPRETED BYBeth Johnson, DVM
DACVIM**HOSPITAL NAME**

Everhart VH

REFERRING VET

Dr. Menefee

INVOICE

31535

ULTRASONOGRAPHIC EXAMINATION OF THE ABDOMEN**Urinary System**

Urinary bladder is adequately distended with anechoic contents. No masses, inflammatory changes, echogenic sediment or cystoliths are observed. The urinary bladder, trigone and visible pelvic urethra are normal in thickness with a smooth mucosal surface.

Left kidney is normal in size (7.03 cm), shape and echogenicity. It has smooth peripheral margination. There is a normal 1:3 cortex to medulla ratio with appropriate corticomedullary distinction. There is no evidence of pyelectasia, mineral or infarcts observed.

Right kidney is normal in size (7.39 cm), shape and echogenicity. It has smooth peripheral margination. There is a normal 1:3 cortex to medulla ratio with appropriate corticomedullary distinction. There is no evidence of pyelectasia, mineral or infarcts observed.

Adrenal Glands

Left adrenal gland is normal in size (2.6 cm long, 0.92 cm at cranial pole and 0.53 cm at caudal pole), shape and overall architecture, echogenicity and echotexture. Visible surrounding vasculature appears normal.

Right adrenal gland is normal in size (2.65 cm long, 0.64 cm at cranial pole and 0.77 cm at caudal pole), shape and overall architecture, echogenicity and echotexture. Visible surrounding vasculature appears normal.

Spleen

Spleen is subjectively normal in size with a normal smooth capsular contour. Parenchyma is appropriately finely textured and homogenous with normal echogenicity relative to surrounding tissue (hyperechoic to liver). No focal nodules or masses are observed. Splenic vasculature appears normal.

Liver

Liver is normal to subjectively small in size with slightly undulating or scalloped capsular contour or margins. Parenchyma is diffusely heterogenous with increased portal markings and coarse architecture. No focal nodules or masses are observed. Visible vasculature and biliary tree appear normal without distension or congestion.

Gallbladder is very small with minimal luminal contents that are appreciated, but echogenic/mineral debris is present in the area of the gallbladder.

Gastrointestinal

The visible stomach wall is normal in thickness and layering. The lumen of the stomach is mildly distended with very echogenic reverberation artifact from intraluminal gas. There is no evidence of obstruction, foreign material or infiltrative disease; however, complete visualization of far wall is partially inhibited by gas. Pyloric outflow tract appears patent.

The visible small intestines are normal in wall thickness and layering. Hyperechoic, mucosal fogging or speckling is noted. Bowel is diffusely mildly fluid distended without evidence of an obstructive pattern, plication and/or visible foreign material. Small intestinal hyperperistalsis is noted.

The visible colon is normal in wall thickness (< 0.2 cm) and layering. Contents are consistent with normal formed feces and gas.

Pancreas

The observed pancreas is prominent (enlarged) in size, hypoechoic to surrounding tissue and irregular in shape with a swollen undulating contour. Enhanced hyperechoic ill-defined surrounding fat is noted.

Free Abdomen

Lymph nodes are prominent in size with swollen capsular contour. Normal elongated shape (length to width ratio) is maintained. There is no loss of parenchymal detail. A large amount of anechoic free fluid is noted.

ULTRASONOGRAPHIC FINDINGS

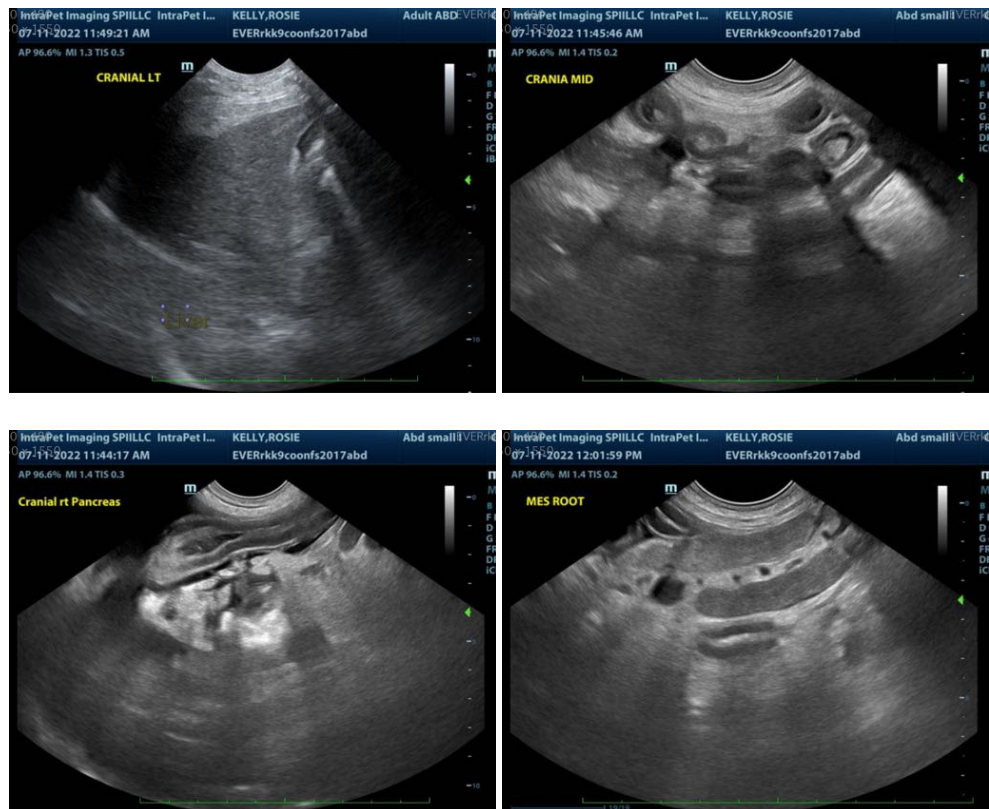
Primary Findings

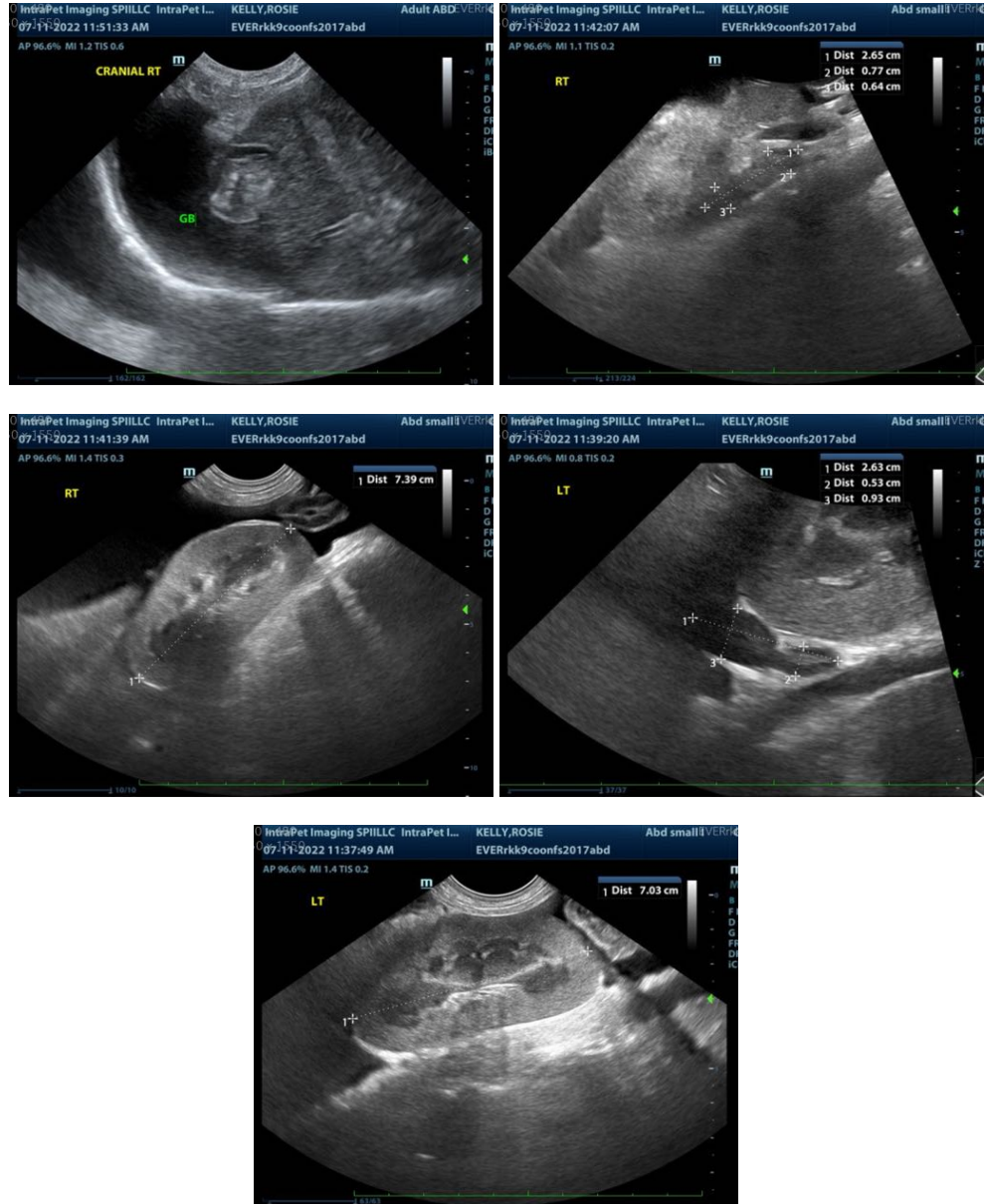
1. Acute pancreatitis.
2. Non-distended, small, gallbladder with mineral debris and contents suspected.
3. Hepatic changes are consistent with chronic inflammatory hepatopathy.
4. Gastroenteritis – Consistent with irritation secondary to dietary indiscretion or intolerance, infection (bacterial, viral, other), parasitic or protozoal disease, toxin, other metabolic disease such as pancreatitis, other.
5. Mucosal speckling is often present with inflammatory bowel disease (IBD). It is not specific for type or severity of disease. Mild speckling change can occur as a normal patient variant in the post-prandial state.
6. Reactive lymph nodes – infiltrative neoplastic disease cannot be ruled out but is considered less likely
7. Large amount of the free fluid in this patient is likely secondary to a combination of factors including acute pancreatitis combined with hypoalbuminemia with portal hypertension can be ruled out as a contributing factor. Neoplastic effusion cannot be ruled out.

INTERPRETATION OF THE FINDINGS & FURTHER RECOMMENDATIONS

1. A gastrointestinal malabsorption panel (including cobalamin, folate, TLI and PLI) to Texas A&M GI Laboratory is recommended for further evaluation of GI and pancreatic function.

2. Cytology of the fluid is recommended +/- culture if indicated based on cytology. Given the very small, almost unable to be visualized gallbladder combined with the free fluid and cranial abdominal inflammation bile (which is considered highly unlikely given the amount of fluid) contributing to the free fluid should be ruled out
3. Given the large amount of free fluid and enhanced, hyperechoic fat and mesentery throughout the abdomen the appearances of some organ/pathology could be altered. Therefore, immediate recommendation includes:
 - a. Medical management of pancreatitis with anti-emetics, gastroprotectants, appetite stimulants or nutritional support as needed, pain management, broad spectrum antibiotics, and fluid therapy is recommended. If possible, a fresh frozen plasma transfusion and hyperbaric oxygen therapy (HBOT) could be beneficial. Monitoring of the pancreas with power doppler is recommended to identify possible necrosis as well as other potential sequelae such as abscesses, etc.
4. If after management of the pancreatitis and improvement in clinical signs and the albumin level is still low and/or bowel and liver still appear abnormal then bile acids are recommended to rule out liver dysfunction (if and when total bilirubin is normal) followed ultimately by liver and bowel biopsies for further diagnosis of definitive underlying pathology.
5. Urinalysis and, if indicated based on urinalysis results, urine culture are recommended. If protein is present in an otherwise quiet sediment, protein quantification with a urine protein to creatinine ration is recommended.





The information and recommendations provided are based on the images presented by the referring veterinarian. No evaluation can be communicated regarding pathology that was not visible in the image/video clips provided.

Thank you for this referral. If the clinical or image interpretation does not parallel your findings or if I can be of any further assistance please contact me.

Beth Johnson, DVM DACVIM
 Beth.Johnson@SonoPath.com