

**DATE PRESENTING CLINICAL SIGNS**

6/9/22 Long hx of kidney insufficiency. Currently having issues with abdominal bloating and decreased appetite. No hx of weight loss though.

PATIENT

Perry Schroeder Current Medications: Mylicon prn when seems bloated, SQ fluids 3x/wk
Rehmannia eight and aminvast feline for kidney support.

Lab Results: 5/21- BUN 55, Crea 3.5, Phox 3.3. 9/21- BUN 58, Crea 2.7, Phos 4.5. 3/22 BUN 52, Creat 4.2, Phos 3.7. 5/22- Crea 3.3, Phos 4.8.

SPECIES

Feline Date of Previous IntraPet Ultrasound: No previous.
Sedation: Not required to complete full diagnostic ultrasound.
Stat Report: Not requested.

BREED

Burmese

ULTRASONOGRAPHIC EXAMINATION OF THE ABDOMEN**Urinary System**

The urinary bladder is moderately distended with anechoic contents. No masses, inflammatory changes, echogenic sediment or cystoliths are observed. The urinary bladder, trigone and visible pelvic urethra are normal in thickness with a smooth mucosal surface.

SEX

Neutered Male

AGE

8/4/07

The kidneys are normal in size, but irregular and diffusely echogenic with decreased corticomedullary distinction and poor visualization of internal architecture. Moderate bilateral pyelectasia is present. No mineral is observed. The left kidney measured 3.7 cm. The right kidney measured 3.86 cm.

WEIGHT

8.38 Pounds

Adrenal Glands

The right adrenal gland is normal in size (0.26 cm), shape and contour. Corticomedullary structure is unremarkable. Visible surrounding vasculature appears normal.

INTERPRETED BY

Beth Johnson, DVM
DACVIM

The left adrenal gland is normal in size (0.32 cm), shape and contour. Corticomedullary structure is unremarkable. Visible surrounding vasculature appears normal.

IMAGING PERFORMED BY

Rachel Brilhart RDMS

Spleen

The spleen is subjectively normal in size with a normal smooth capsular contour. Parenchyma is appropriately finely textured and homogenous with normal echogenicity relative to surrounding tissue (hyperechoic to liver). No focal nodules or masses are observed. Splenic vasculature appears normal.

HOSPITAL NAME

Healing Paws VWC

Liver

The liver is subjectively normal in size with normal smooth curvilinear peripheral contour. Parenchyma is appropriately hypoechoic to the spleen in echogenicity and appropriately mildly coarse and homogenous in echotexture. No focal lesions are observed. Visible vasculature and biliary tree appear normal without distension or congestion.

REFERRING VET

Dr. Levitsky

The gallbladder is non-distended in size. Luminal contents are primarily anechoic. A mildly hyperechoic, mildly thick wall is noted. A tortuous cystic and common bile duct noted with no evidence of obstruction, overdistention, or debris.

INVOICE

38593

Gastrointestinal

The stomach wall is normal in thickness (canine < 0.5 cm and feline < 0.4 cm) and layering. The lumen of the stomach is empty with no evidence of obstruction, foreign material or infiltrative disease. Pyloric outflow tract appears patent.

The visible small intestines are normal in wall thickness. Normal layering is maintained except for a diffusely disproportionately thick muscularis layer relative to mucosa. Small intestinal motility appears adequate (1-3

contractions per min). The lumen of the small intestine is empty with no evidence of obstruction, foreign material or infiltrative disease.

The visible colon is normal in wall thickness (< 0.2 cm) and layering. Contents are consistent with normal formed feces and gas.

Pancreas

The pancreatic parenchyma is appropriately isoechoic to surrounding tissue. Visible capsule is smooth and normal in contour. There is no visible pancreatic duct dilation. There is no evidence of active peripancreatic inflammation.

Free Abdomen

There is a very scant amount of non-specific free fluid. There is no apparent lymphadenopathy.

PRIMARY FINDINGS

- Thick muscularis – This finding has been reported in cats with infiltrative bowel disease including both benign inflammatory disease as well as infiltrative neoplasia such as lymphoma.
- Chronic Kidney Disease - This appearance of the kidneys is consistent with chronic kidney disease such as chronic glomerular or interstitial nephritis, chronic pyelonephritis, etc.
- Pyelectasia - Differentials for pyelectasia include pyelonephritis, diuresis, congenital malformation or ureteral or lower urinary tract obstruction.
- Scant anechoic free fluid.

SECONDARY FINDINGS

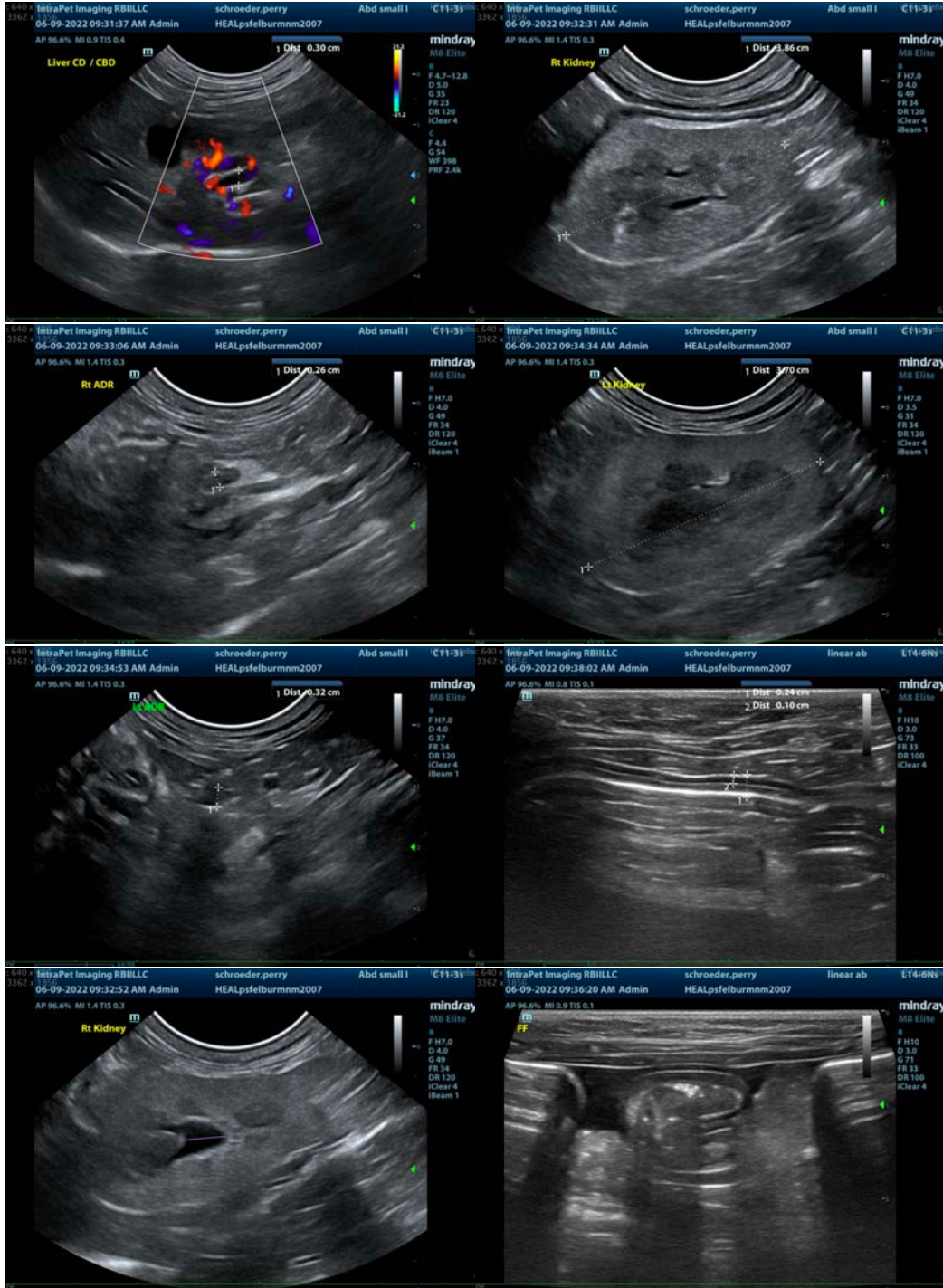
- Mildly thick hyperechoic gallbladder wall and tortuous cystic and common bile duct – This can be an incidental normal variant in a senior cat, or evidence of chronic and/or resolved cholangitis/cholangiohepatitis, and should be interpreted in combination with clinical signs and/or laboratory changes.

INTERPRETATION OF THE FINDINGS & FURTHER RECOMMENDATIONS

Given the GI signs combined with thick muscularis, recommendations include further evaluation of the gastrointestinal tract with a gastrointestinal malabsorption panel to Texas A&M GI laboratory to include PLI, TLI, folate and cobalamin. Ultimately, biopsies of the bowel may be required to definitively diagnosis and therefore manage clinical signs. In the meantime, transition to a novel or hydrolyzed protein diet or bland, easy to digest diet based on trial and error basis +/- addition of probiotic may help.

Continue management of chronic kidney disease. If a urinalysis has not been recently evaluated, this would be recommended with follow up urine culture if indicated based on urinalysis results.

Without evidence of cranial abdominal pain or clinical pathologic abnormalities such as increased ALP, total bilirubin, or ALT, the tortuous biliary system is believed to be an incidental aging change. However, if clinical signs and/or laboratory changes develop, further evaluation and/or management is recommended.



The information and recommendations provided are based on the images presented by the referring veterinarian/sonographer. No evaluation can be communicated regarding pathology that was not visible in the image/video clips provided.

Thank you for this referral. If the clinical or image interpretation does not parallel your findings or if I can be of any further assistance please contact me.

Beth Johnson, DVM, DACVIM
Beth.Johnson@sonopath.com