SonoPath
Clinical Sonography & Telecytology

EDUCATIONAL TELECONSULTATION SERVICES™

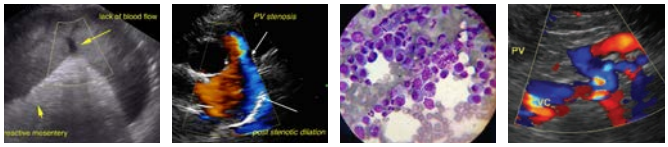

SonoPath.com™
1-800-838-4268 info@sonopath.com

PATIENT
Cherub Moon Tinkle

SPECIES
Feline

BREED
DLH

SEX
Neutered Male

AGE
11 Years

WEIGHT
15.5 Pounds

INTERPRETED BY
Beth Johnson, DVM DACVIM

IMAGING PERFORMED BY
Harold Mike Beard

HOSPITAL NAME
Animal Care Vet Center

REFERRING VET
Dr. Mayflower

INVOICE
38554

DATE
6/9/22

PRESENTING CLINICAL SIGNS

Weight loss, anorexia 4 days.
Abnormal PE/Chem/CBC/UA Results: Icterus, palpable cranial abdominal mass. Cranial abdomen did seem to be painful. Temp normal. Plain radiographs reveal a liver mass. ALT elevated, Alk Phos normal.

ULTRASONOGRAPHIC EXAMINATION OF THE ABDOMEN

Urinary System

The urinary bladder is moderately distended with anechoic contents. No masses, inflammatory changes, echogenic sediment or cystoliths are observed. The urinary bladder, trigone and visible pelvic urethra are normal in thickness with a smooth mucosal surface.

The right kidney is normal in size (4.0 cm), shape and echogenicity. It has smooth peripheral margination. There is a normal 1:3 cortex to medulla ratio with appropriate corticomedullary distinction. There is no evidence of pyelectasia, mineral or infarcts observed.

The left kidney is normal in size (4.0 cm), shape and echogenicity. It has smooth peripheral margination. There is a normal 1:3 cortex to medulla ratio with appropriate corticomedullary distinction. There is no evidence of pyelectasia, mineral or infarcts observed.

Adrenal Glands

The adrenal glands are unable to be visualized in these images.

Spleen

The spleen is subjectively normal in size with a normal smooth capsular contour. Parenchyma is appropriately finely textured and homogenous with normal echogenicity relative to surrounding tissue (hyperechoic to liver). No focal nodules or masses are observed. Splenic vasculature appears normal.

Liver

The liver is diffusely subjectively enlarged/swollen with scalloped, irregular margins. It is overall diffusely hypoechoic in appearance. However, it contains multifocal coalescing, heterogeneous nodules, the largest of which measures approximately 6.0 cm mid liver and is hyperechoic in echogenicity.

The gallbladder is non-distended in size. The wall is smooth without visible thickening. Luminal contents are primarily anechoic. There is no evidence of cystic or common bile duct dilation.

Gastrointestinal

The stomach wall is normal in thickness (canine < 0.5 cm and feline < 0.4 cm) and layering. The lumen of the stomach is empty with no evidence of obstruction, foreign material or infiltrative disease. Pyloric outflow tract appears patent.

The visible small intestines are normal in wall thickness. Normal layering is maintained except for a diffusely disproportionately thick muscularis layer relative to mucosa. Small intestinal motility appears adequate (1-3 contractions per min). The lumen of the small intestine is empty with no evidence of obstruction, foreign material or infiltrative disease.

The visible colon is normal in wall thickness (< 0.2 cm) and layering. Contents are consistent with normal formed feces and gas.

SonoPath
Clinical Sonography & Telecytology
EDUCATIONAL TELECONSULTATION SERVICES™

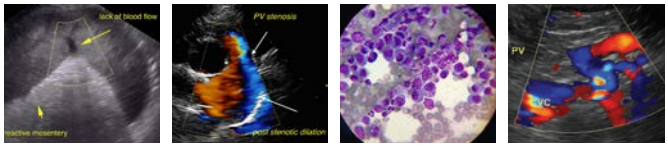

SonoPath.com™
1-800-838-4268 info@sonopath.com

PATIENT
Cherub Moon Tinkle

SPECIES
Feline

BREED
DLH

SEX
Neutered Male

AGE
11 Years

WEIGHT
15.5 Pounds

INTERPRETED BY
Beth Johnson, DVM DACVIM

IMAGING PERFORMED BY
Harold Mike Beard

HOSPITAL NAME
Animal Care Vet Center

REFERRING VET
Dr. Mayflower

INVOICE
38554

DATE
6/9/22

Pancreas

The pancreas is prominent in size with a diffusely coarse echotexture and hypoechoic echogenicity.

Free Abdomen

A small amount of free fluid is present, primarily in the cranial abdomen. Markedly enhanced hyperechoic and clumped mesentery is present throughout the entire abdomen, most appreciated around the liver and pancreas.

ULTRASONOGRAPHIC FINDINGS

- Markedly enlarged, irregular, hypoechoic liver with multifocal coalescing heterogeneous nodules throughout – most concerning for infiltrative neoplasia. Round cell neoplasia, primary hepatic neoplasia, and metastatic neoplasia are all differentials. Benign inflammatory or even infectious disease such as an undifferentiated abscess is possible, but considered much less likely, especially given the concurrent abnormalities.

- Thick muscularis – This finding has been reported in cats with infiltrative bowel disease including both benign inflammatory disease as well as infiltrative neoplasia such as lymphoma. **Infiltrative round cell neoplasia such as lymphoma has to be a top differential, given the concurrent lesions.

- Small amount of free fluid and hyperechoic, clumped mesentery – reactive peritonitis secondary to possible pancreatitis and/or the liver disease is possible. However, neoplastic spread, as is seen with carcinomatosis has to be considered.

- Prominent, heterogeneous pancreas – rule out normal age remodeling of the pancreas versus chronic smoldering pancreatitis. Infiltrative neoplasia of the pancreas is possible, but considered less likely.

INTERPRETATION OF THE FINDINGS & FURTHER RECOMMENDATIONS

Recommendations include:

1. Fine needle aspirate of the liver, if patient's coagulation status is appropriate, as well as fluid sampling for cytology +/- culture, if possible.

2. 3-view thoracic radiographs are recommended for further evaluation of metastatic disease, if not already evaluated.

3. Ultimately, surgical laparotomy with liver biopsy and small intestinal biopsies, being sure to include the ileum if possible, may be necessary to definitively diagnosis and therefore manage this patient's underlying condition. However, it appears unlikely that all of the visibly gross disease in the liver can be removed surgically.

SonoPath

Clinical Sonography & Telecytology

EDUCATIONAL TELECONSULTATION SERVICES™

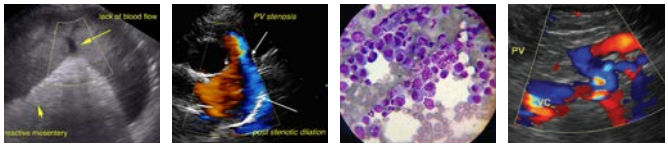

SonoPath.com™

1-800-838-4268 info@sonopath.com

PATIENT

Cherub Moon Tinkle

SPECIES

Feline

BREED

DLH

SEX

Neutered Male

AGE

11 Years

WEIGHT

15.5 Pounds

INTERPRETED BY

Beth Johnson, DVM
DACVIM

IMAGING PERFORMED BY

Harold Mike Beard

HOSPITAL NAME

Animal Care Vet Center

REFERRING VET

Dr. Mayflower

INVOICE

38554

DATE

6/9/22

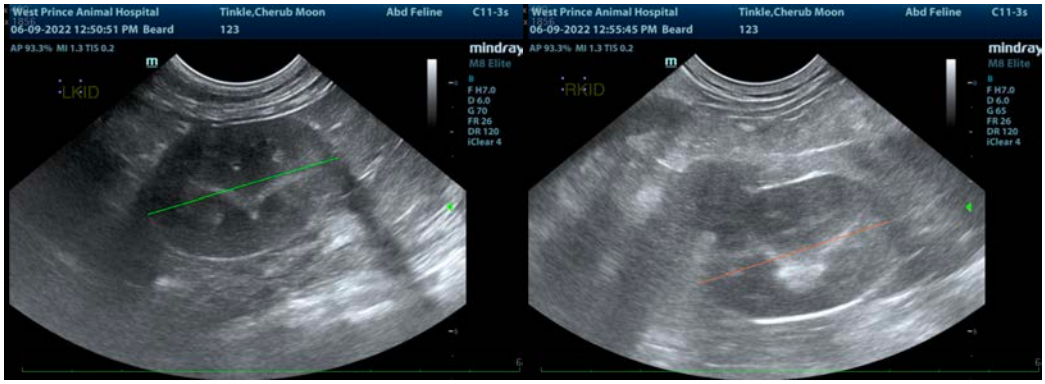

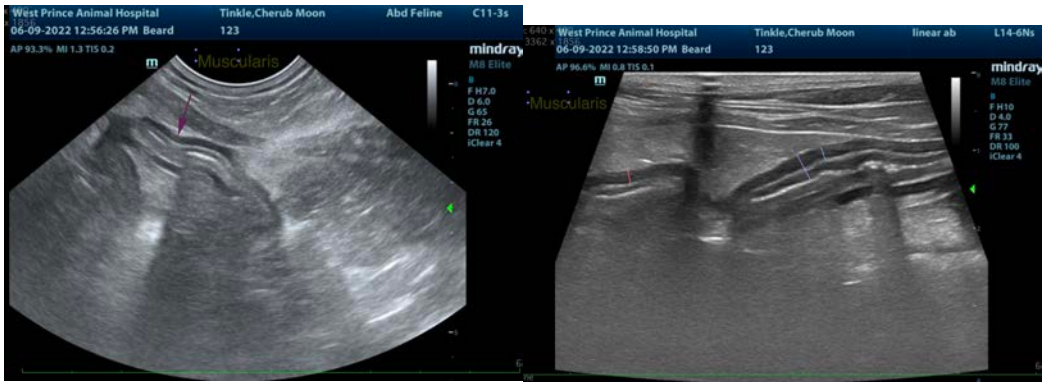

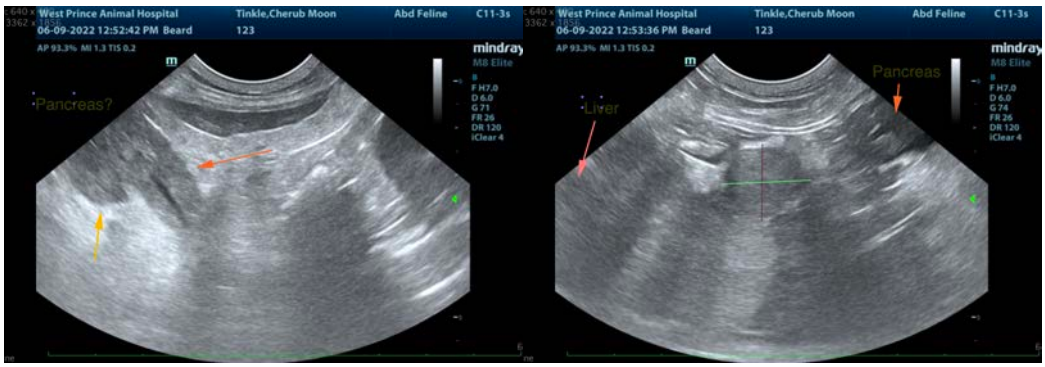

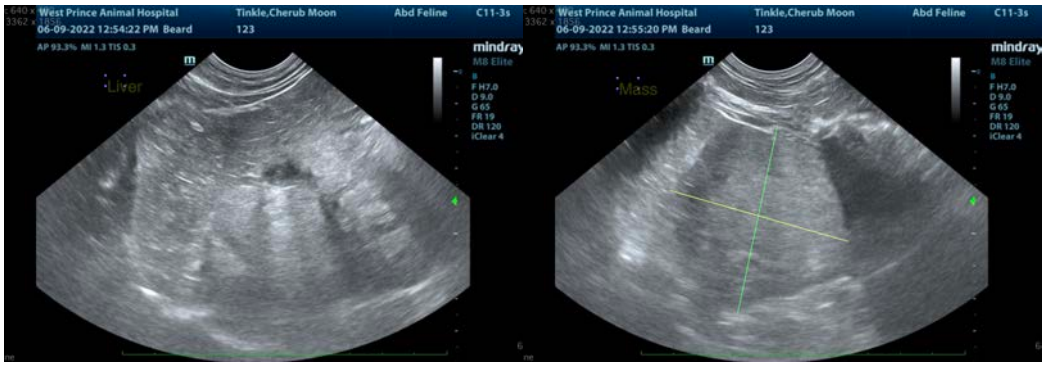

SonoPath

Clinical Sonography & Telecytology

EDUCATIONAL TELECONSULTATION SERVICES™

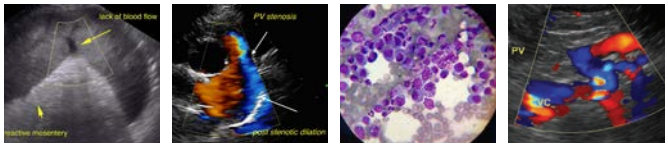

SonoPath.com™
1-800-838-4268 info@sonopath.com

PATIENT

Cherub Moon Tinkle

SPECIES

Feline

BREED

DLH

SEX

Neutered Male

AGE

11 Years

WEIGHT

15.5 Pounds

INTERPRETED BY

Beth Johnson, DVM DACVIM

IMAGING PERFORMED BY

Harold Mike Beard

HOSPITAL NAME

Animal Care Vet Center

REFERRING VET

Dr. Mayflower

INVOICE

38554

DATE

6/9/22

The information and recommendations provided are based on the images presented by the referring veterinarian/sonographer. No evaluation can be communicated regarding pathology that was not visible in the image/video clips provided.

Thank you for this referral. If the clinical or image interpretation does not parallel your findings or if I can be of any further assistance please contact me.

Beth Johnson, DVM, DACVIM
Beth.Johnson@sonopath.com