

**DATE PRESENTING CLINICAL SIGNS**

6/8/22 Historical uncontrolled diabetes. Pet started having seizures this morning.

PATIENT Current Medications: Humulin N Inuslin 7 units BID.

Sammy Alperstein Lab Results: Elevated ALKP, Fructosamine, Glu.

Date of Previous IntraPet Ultrasound: No previous.

Sedation: Midazolam and Torbugesic IV.

Stat Report: Declined.

SPECIES

Canine

ULTRASONOGRAPHIC EXAMINATION OF THE ABDOMEN**BREED** *Urinary System*

Terrier

Urinary bladder is mildly to moderately distended. Contents include primarily anechoic fluid combined with both gravity dependent and suspended echogenic non-shadowing debris within the fluid. Apical urinary bladder wall is diffusely thick. Mucosa is hyperechoic and irregular. No masses or cystoliths are observed. The trigone and visible pelvic urethra are normal thickness with a smooth mucosal surface.

SEX

Spayed Female

The right kidney is normal in size (6.58 cm), shape and echogenicity. It has smooth peripheral margination. There is a normal 1:3 cortex to medulla ratio with appropriate corticomedullary distinction. There is pyelectasia noted. Enhanced hyperechoic thickened pelvic fat is noted. There is no evidence of mineral or infarcts observed. A hyperechoic band parallel to the corticomedullary border is present.

AGE

5/12/08

The left kidney is normal in size (5.63 cm), shape and echogenicity. It has smooth peripheral margination. There is a normal 1:3 cortex to medulla ratio with appropriate corticomedullary distinction. There is pyelectasia noted. Enhanced hyperechoic thickened pelvic fat is noted. There is no evidence of mineral or infarcts observed. A hyperechoic band parallel to the corticomedullary border is present.

WEIGHT

26.8 Pounds

INTERPRETED BY

Beth Johnson, DVM
DACVIM

Adrenal Glands

The left adrenal gland is enlarged (4.39 cm long x 1.57 cm at the cranial pole and 1.41 cm at the caudal pole) with heterogeneous parenchymal changes diffusely, regional capsular escape cranially, and diffuse undifferentiated proliferation.

IMAGING PERFORMED BY

Stephanie Pearce
RDMS, RVT

The right adrenal gland is visualized and is more normal in appearance. Cranial pole measured 1.0 cm. Caudal pole measured 0.73 cm.

HOSPITAL NAME

Banfield Timonium

Spleen

The spleen is subjectively normal in size with a normal smooth capsular contour. Parenchyma is appropriately finely textured and homogenous with normal echogenicity relative to surrounding tissue (hyperechoic to liver). No focal nodules or masses are observed. Splenic vasculature appears normal.

REFERRING VET

Dr. Kameka

Liver

Liver is subjectively enlarged with rounded margins. Parenchyma is heterogeneous characterized by multiple poorly defined hypoechoic nodules within otherwise hyperechoic liver parenchyma. A heterogeneous undifferentiated mass is noted in the right liver, measuring approximately 7.5 cm in diameter. Visible vasculature appears normal.

INVOICE

38515

GB is moderately distended with anechoic bile and gravity dependent echogenic sediment. The wall is smooth without visible thickening. There is no evidence of cystic or CBD dilation. There is no evidence of effusion or inflammation.

Gastrointestinal

The stomach wall is normal in thickness (canine < 0.5 cm and feline < 0.4 cm) and layering. The lumen of the stomach is mildly distended with echogenic non-shadowing luminal contents and gas consistent with normal ingesta. There is no evidence of obstruction, foreign material or infiltrative disease. Pyloric outflow tract appears patent.

The visible small intestines are normal in wall thickness and layering (canine duodenum < 0.5 cm and feline duodenum < 0.4 cm; other < 0.3 cm). Small intestinal motility appears adequate (1-3 contractions per min). The lumen of the small intestine is empty with no evidence of obstruction, foreign material or infiltrative disease.

The visible colon is normal in wall thickness (< 0.2 cm) and layering. Contents are consistent with normal formed feces and gas.

Pancreas

The pancreatic parenchyma is appropriately isoechoic to surrounding tissue. Visible capsule is smooth and normal in contour. There is no visible pancreatic duct dilation. There is no evidence of active peripancreatic inflammation.

Free Abdomen

A pocket of anechoic fluid with some echogenic debris within the fluid is noted around the left adrenal mass and kidney.

There is no apparent lymphadenopathy.

ULTRASONOGRAPHIC FINDINGS

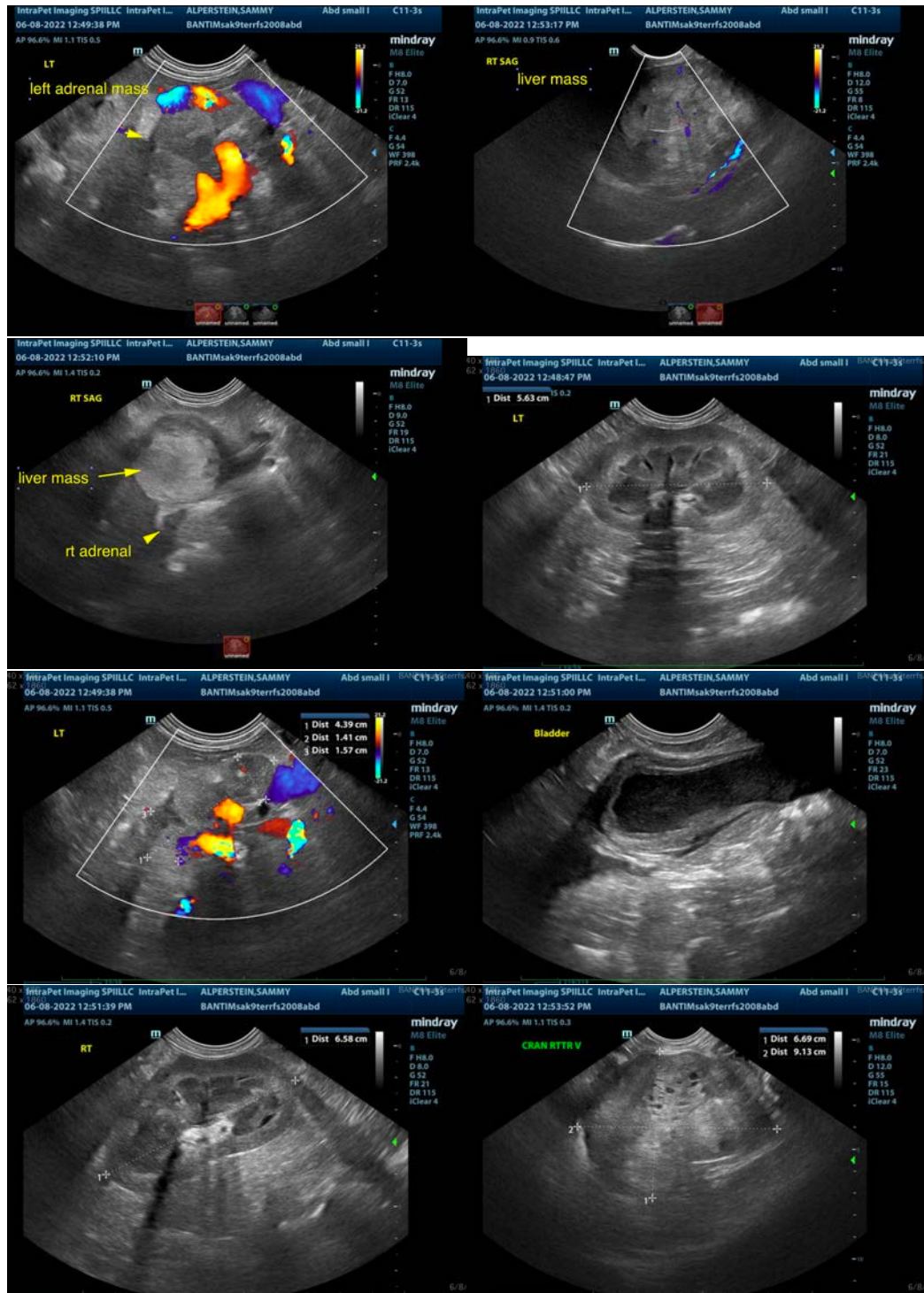
- Left adrenal mass and heterogeneous liver mass, with the liver mass believed to represent a metastatic lesion from the adrenal mass, or potentially comorbidities. Top differentials for the adrenal mass are adrenal carcinoma or pheochromocytoma. Vascular invasion is not visible in these images, but is considered likely. The focal free fluid could represent hemorrhage from the mass versus paraneoplastic effusion.
- Bilateral pyelectasia with enhanced pelvic fat – concerning for chronic pyelonephritis.
- Chronic Cystitis – Urinary bladder wall changes are most consistent with chronic cystitis. Infiltrative neoplasia cannot be ruled out but is considered less likely given the location and diffuse nature of the changes.

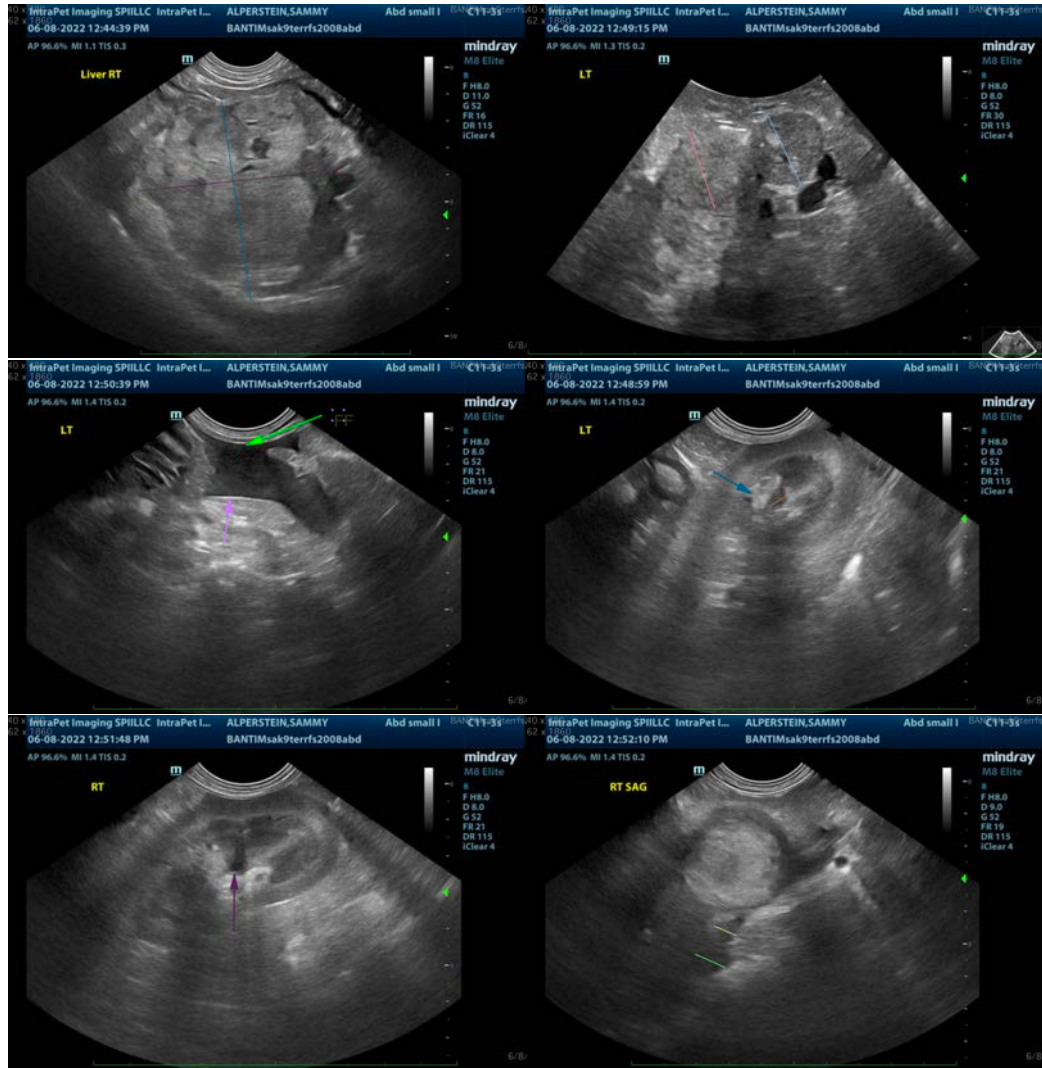
INTERPRETATION OF THE FINDINGS & FURTHER RECOMMENDATIONS

It is unknown if the adrenal mass and liver mass are related, with the liver mass being a metastatic lesion, or if there is multicentric neoplasia (two separate pathologies) in this patient. Seizures could be secondary to a hypertensive vascular event and/or metastatic disease vs other. Recommendations include:

- Blood pressure if not recently evaluated.
- 3-view thoracic radiographs for further evaluation of metastatic disease (if not recently evaluated).
- Further evaluation of the liver mass could be pursued with a fine needle aspirate of the liver mass, if patient's coagulation status is appropriate, or surgical excisional biopsies of the liver mass and left adrenal mass could be considered with strong recommendation for pre-surgical planning abdominal CT scan.

- If not recently evaluated, urinalysis and urine culture are recommended, given the history of diabetes and the bladder and kidney changes present in this study.





The information and recommendations provided are based on the images presented by the referring veterinarian/sonographer. No evaluation can be communicated regarding pathology that was not visible in the image/video clips provided.

Thank you for this referral. If the clinical or image interpretation does not parallel your findings or if I can be of any further assistance please contact me.

Beth Johnson, DVM, DACVIM
 Beth.Johnson@sonopath.com