**DATE**

6/6/22

**PRESENTING CLINICAL SIGNS**

FNA of mass consistent with mast cell tumor. PE- severe dental disease, MPLs, few dermal masses, MCT near R stifle.

Current Medications: None listed.

**PATIENT**

Lab Results: FNA to Scpio consistent with MCT.

Date of Previous IntraPet Ultrasound: No previous.

Kipper Adams

Sedation: Not required to complete full diagnostic ultrasound.

Stat Report: Not requested.

**SPECIES**

Imaging Performed By: Andi Parkinson, BS, RDMS.

Canine

**ULTRASONOGRAPHIC EXAMINATION OF THE ABDOMEN****BREED****Urinary System**

Yorkie

Urinary bladder is moderately distended with anechoic contents. It has normal uniform wall thickness (< 0.2 cm). No masses or cystoliths are observed.

**SEX**

Neutered male

The prostate is normal in size measuring 1.2 cm wide. It maintains smooth margins that are well differentiated from surrounding tissue and a normal bilobed shape. The parenchyma is mildly heterogeneous; however, slightly atypical for a dog neutered as a puppy.

**AGE**

5/5/09

The left kidney is normal in size and shape with smooth peripheral margination. A normal 1:3 cortex to medulla ratio is maintained. The medulla and cortices are uniform in texture with some mild increased echogenicity and mild loss of corticomedullary distinction. There is no evidence of pyelectasia, mineral or infarcts observed. The left kidney measured 2.71 cm.

**WEIGHT**

5.12 lbs

The right kidney is normal in size and shape with smooth peripheral margination. A normal 1:3 cortex to medulla ratio is maintained. The medulla and cortices are uniform in texture with some mild increased echogenicity and mild loss of corticomedullary distinction. There is no evidence of pyelectasia, mineral or infarcts observed. The right kidney measured 3.44 cm.

**INTERPRETED BY**Beth Johnson, DVM  
DACVIM**Adrenal Glands**

Left adrenal gland is normal in size (1.24 cm long, 0.47 cm at cranial pole and 0.49 cm at caudal pole), shape and contour. Corticomedullary structure is unremarkable.

**HOSPITAL NAME**

Eastern AH

Right adrenal gland is normal in size (1.01 cm long cm, 0.21 cm at cranial pole and 0.33 cm at caudal pole), shape and contour. Corticomedullary structure is unremarkable.

**REFERRING VET**

Dr. Cusack

**Spleen**

Spleen is subjectively normal in size with normal smooth margins. Parenchyma is normal in echogenicity and echotexture. A hypoechoic nodule with a hyperechoic center was noted near the tail of the spleen and measured 0.6 cm. The nodule does not disrupt the splenic capsule. Splenic vasculature appears normal.

**INVOICE**

30862

**Liver**

Liver is subjectively normal in size. Margins are sharp and smooth. It has normal homogenous echotexture and normal echogenicity. No focal lesions are observed. Visible vasculature appears normal. Gallbladder is mildly distended with anechoic contents. The wall is smooth without visible thickening. There is no evidence of common bile duct dilation.

### ***Gastrointestinal***

The visible gastric wall is normal in thickness (canine < 0.5 cm and feline < 0.4 cm). The stomach is empty.

The small intestines are normal in wall thickness and layering. Small intestinal motility appears adequate (1-3 contractions per min). There are no luminal contents noted within small intestines.

Colon is normal in wall thickness (< 0.2 cm) and layering.

### ***Pancreas***

Pancreas has normal homogenous echotexture and is normal in echogenicity and smooth margination. There is no evidence of peripancreatic inflammation.

### ***Free Abdomen***

Lymph nodes are normal with no observed enlargement. No free fluid was noted. There was no pericardial effusion present.

## **ULTRASONOGRAPHIC FINDINGS**

### **PRIMARY FINDINGS:**

- Splenic nodule, which likely represents a benign lesion such as a cyst or hematoma, nodular hyperplasia or extramedullary hematopoiesis. However, given the patient's mast cell tumor, infiltrative neoplasia cannot be ruled out as it can mimic benign lesions in the spleen.

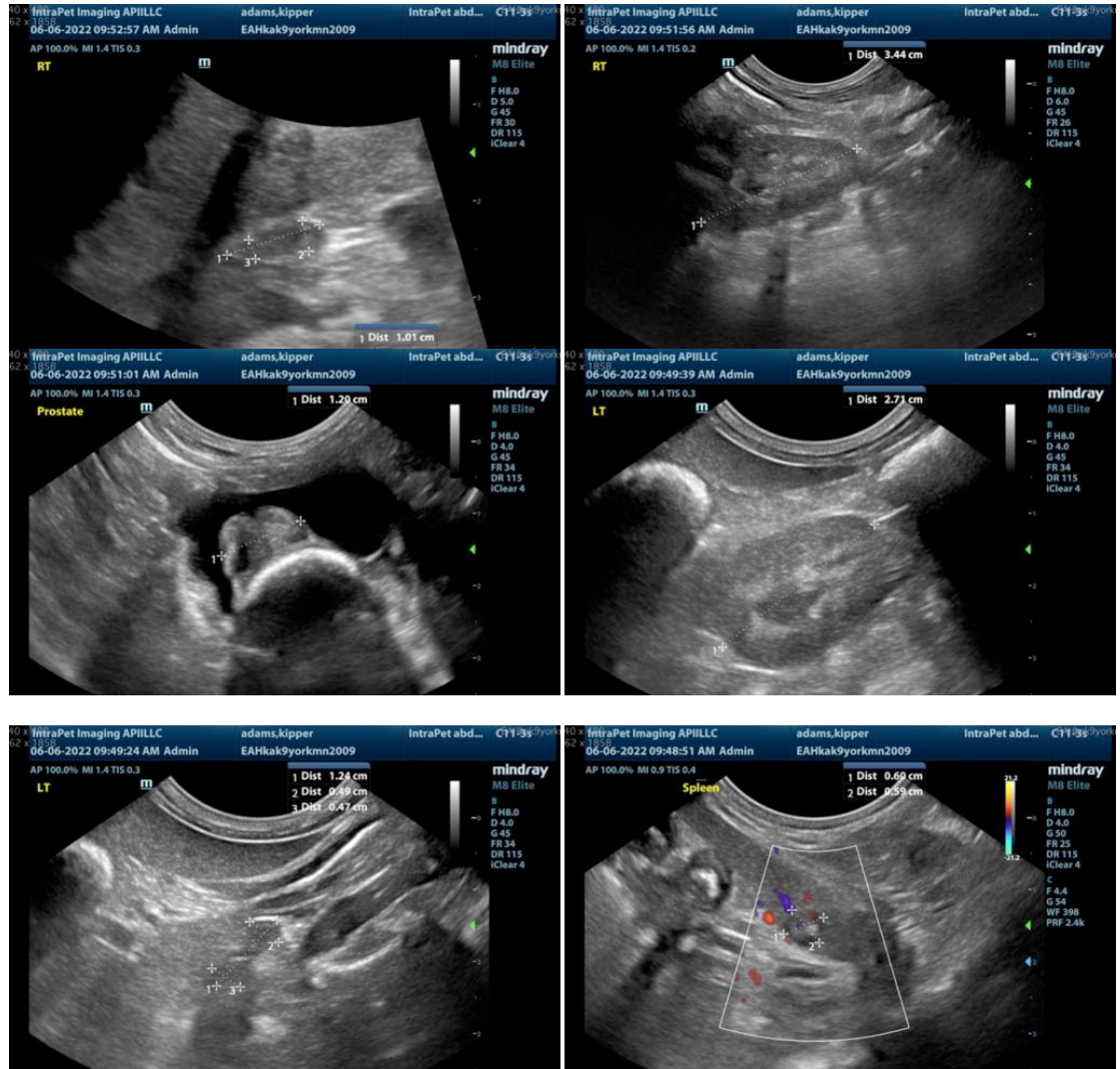
### **SECONDARY FINDINGS:**

- Mildly heterogenous prostate, considered normal patient variant, most likely especially if this dog was neutered later in life. However, prostatitis cannot be ruled out. However, pathology is considered much less likely.
- Age related kidney change – This finding is expected/consistent with age-related mild degenerative disease and should be interpreted clinically in combination with laboratory changes.

## **INTERPRETATION OF THE FINDINGS & FURTHER RECOMMENDATIONS**

Given the reported mast cell tumor a FNA of the splenic nodule is recommended if possible and if the patient's coagulation status is appropriate.

If the patient was neutered in later in life no follow-up of the prostate is necessary. However, if the patient was neutered as a young puppy a recheck of the prostate is recommended in 4-6 weeks to assess for changes/progression is recommended. If the urinary signs develop in the meantime urinalysis and urine culture if indicated based on urinalysis results can be considered.



The information and recommendations provided are based on the images presented by the referring veterinarian. No evaluation can be communicated regarding pathology that was not visible in the image/video clips provided.

Thank you for this referral. If the clinical or image interpretation does not parallel your findings or if I can be of any further assistance please contact me.

**Beth Johnson, DVM DACVIM**

Beth.Johnson@SonoPath.com