

**DATE**

06/06/2022

**PRESENTING CLINICAL SIGNS**

Elevated kidney values; leaking urine.

**PATIENT**

Brixton Lexica

Current Medications: None listed.

Date of Previous IntraPet Ultrasound: No previous.

Sedation: Not required to complete full diagnostic ultrasound.

**SPECIES**

Canine

Stat Report: Not requested.

Imaging Performed By: Stephanie Pearce RDCS, RVT.

**BREED**

Greyhound

**ULTRASONOGRAPHIC EXAMINATION OF THE ABDOMEN****SEX**

MN

**Urinary System**

Urinary bladder is moderately distended with anechoic contents. No masses, inflammatory changes, echogenic sediment or cystoliths are observed. The urinary bladder, trigone and visible pelvic urethra are normal in thickness with a smooth mucosal surface.

**AGE**

7/15/2016

Right kidney is normal in size (7.42 cm), shape and echogenicity. It has smooth peripheral margination. There is a normal 1:3 cortex to medulla ratio with appropriate corticomedullary distinction. There is no evidence of pyelectasia, mineral or infarcts observed.

**WEIGHT**

84 pounds

Left kidney is normal in size (7.65 cm), shape and echogenicity. It has smooth peripheral margination. There is a normal 1:3 cortex to medulla ratio with appropriate corticomedullary distinction. There is no evidence of pyelectasia, mineral or infarcts observed.

**INTERPRETED BY**Beth Johnson, DVM  
DACVIM

Prostate is normal in size, echotexture and echogenicity for a neutered male.

**HOSPITAL NAME**Lake Shore Pet  
Hospital**Adrenal Glands**

Right adrenal gland is normal in size (0.91 cm at cranial pole and 0.75 cm at caudal pole), shape and contour. Corticomedullary structure is unremarkable. Visible surrounding vasculature appears normal.

Left adrenal gland is normal in size (0.45 cm at cranial pole and 0.64 cm at caudal pole), shape and contour. Corticomedullary structure is unremarkable. Visible surrounding vasculature appears normal.

**REFERRING VET**

Dr. Stiehl

**Spleen**

Spleen is subjectively normal in size with a normal smooth capsular contour. Parenchyma is appropriately finely textured and homogenous with normal echogenicity relative to surrounding tissue (hyperechoic to liver). No focal nodules or masses are observed. Splenic vasculature appears normal.

**INVOICE**

10741ag

**Liver**

Liver is subjectively normal in size with normal smooth curvilinear peripheral contour. Parenchyma is appropriately hypoechoic to the spleen in echogenicity and appropriately mildly coarse and homogenous in echotexture. No focal lesions are observed. Visible vasculature and biliary tree appear normal without distension or congestion. Gallbladder is non-distended in size. The wall is smooth without visible thickening. Luminal contents are primarily anechoic. There is no evidence of cystic or common bile duct dilation.

**Gastrointestinal**

The stomach wall is normal in thickness (canine < 0.5 cm and feline < 0.4 cm) and layering. The lumen of the stomach is mildly distended with very echogenic reverberation artifact from intraluminal gas. There is no evidence of obstruction, foreign material or infiltrative disease; however, complete visualization of far wall is partially inhibited by gas. Pyloric outflow tract appears patent.

The visible small intestines are normal in wall thickness and layering (canine duodenum < 0.5 cm and feline duodenum < 0.4 cm; other < 0.3 cm). Small intestinal motility appears adequate (1-3 contractions per min). The lumen of the small intestine is mildly distended with echogenic non-shadowing luminal contents and gas consistent with normal ingesta. There is no evidence of obstruction, foreign material or infiltrative disease.

The visible colon is normal in wall thickness (< 0.2 cm) and layering. Contents are consistent with normal formed feces and gas.

### ***Pancreas***

Pancreatic parenchyma is appropriately isoechoic to surrounding tissue. Visible capsule is smooth and normal in contour. There is no visible pancreatic duct dilation. There is no evidence of active peripancreatic inflammation.

### ***Free Abdomen***

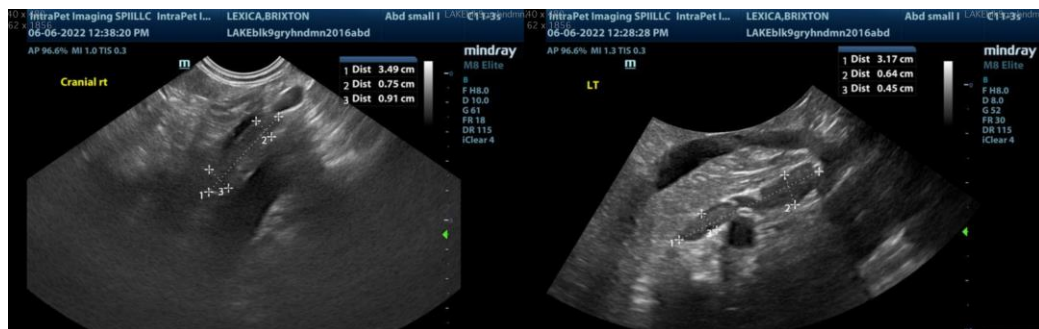
There is no evidence of peritoneal effusion. There is no apparent lymphadenopathy.

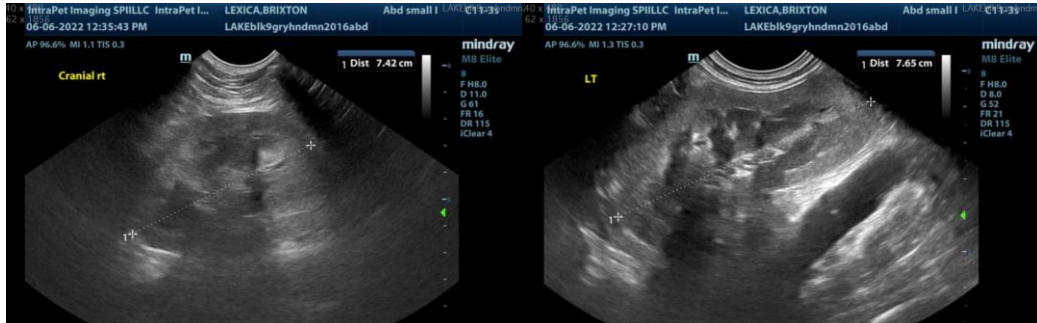## **ULTRASONOGRAPHIC FINDINGS**

- A relatively unremarkable abdomen

## **INTERPRETATION OF THE FINDINGS & FURTHER RECOMMENDATIONS**

Given this patient's progressive azotemia and reported urinary incontinence recommendations include a urine C/S as well as testing for leptospirosis. A BP is also recommended if not recently evaluated. If there is protein in the urine and the culture is negative, a UPC is recommended for quantification of the proteinuria. If PU/PD are present that may be contributing to the urinary incontinence. Otherwise, additional diagnostic recommendations include neurologic evaluation for other causes of incontinence.





The information and recommendations provided are based on the images presented by the referring veterinarian/sonographer. No evaluation can be communicated regarding pathology that was not visible in the image/video clips provided.

Thank you for this referral. If the clinical or image interpretation does not parallel your findings or if I can be of any further assistance please contact me.

**Beth Johnson, DVM DACVIM**

Beth.Johnson@SonoPath.com