

**DATE PRESENTING CLINICAL SIGNS**

6/30/22

Pt presented 6/27 for diarrhea after eating entire raw hide. No vomiting, normal eating/drinking. Slight lethargy. Pt goes to CVCA for echocardiograms regularly per O (need records). Treated for outpatient care as pt ate snacks in the AM. brief US revealed suspected splenic mass, mild panc, diarrhea in intestines. Recommend full u/s to assess splenic mass as well as any changes in liver, LN as well as search for any remaining raw hide on empty stomach.

PATIENT

Rocky Dellaratta

SPECIES

Canine

Current Medications: metronidazole 100AM, 50PM since 6/27, bland diet, pimobendane, probiotics.
Date of Previous IntraPet Ultrasound: No previous.
Sedation: Not required to complete full diagnostic ultrasound.
Stat Report: Not requested.

BREED

Shih Tzu

ULTRASONOGRAPHIC EXAMINATION OF THE ABDOMEN**SEX**

Intact Male

Urinary System

The urinary bladder is moderately distended with anechoic contents. No masses, inflammatory changes, echogenic sediment or cystoliths are observed. The urinary bladder, trigone and visible pelvic urethra are normal in thickness with a smooth mucosal surface.

AGE

6/27/08

Prostate (intact) is normal in size for an intact male. It has a normal homogenous echotexture and is hyperechoic in echogenicity, normal for intact male.

WEIGHT

14.18 Pounds

The right kidney is normal in size (3.75 cm), shape and echogenicity. It has smooth peripheral margination. There is a normal 1:3 cortex to medulla ratio with appropriate corticomedullary distinction. There is no evidence of pyelectasia or infarcts observed. There is a 1.3 cm x 2.0 cm anechoic cortical cyst in the cranial pole. Non-obstructive areas of mineralization/nephroliths are noted, primarily in the diverticular of the kidney.

INTERPRETED BYBeth Johnson, DVM
DACVIM

The left kidney is normal in size (3.81 cm), shape and echogenicity. It has smooth peripheral margination. There is a normal 1:3 cortex to medulla ratio with appropriate corticomedullary distinction. There is no evidence of pyelectasia or infarcts observed. Non-obstructive areas of mineralization/nephroliths are noted, primarily in the diverticular of the kidney.

IMAGING PERFORMED BY

Andi Parkinson RDMS

Adrenal Glands

The right adrenal gland is normal in size (1.73 cm long x 0.41 cm at the cranial pole and 0.50 cm at the caudal pole), shape and contour. Corticomedullary structure is unremarkable. Visible surrounding vasculature appears normal.

HOSPITAL NAME

Everhart Vet Hospital

The left adrenal gland is normal in size (1.95 cm long x 0.49 cm at the cranial pole and 0.46 cm at the caudal pole), shape and contour. Corticomedullary structure is unremarkable. Visible surrounding vasculature appears normal.

REFERRING VET

Dr. Rubinstein

Spleen

The spleen contains two masses. One is an approximately 4.0 cm round, cavitated, vascular, mixed mass in the mid body that disrupts the capsule. The second is an approximately 1.5 cm in diameter hypo- to anechoic nodule that does not disrupt the capsule.

INVOICE

39159

Liver

The liver is subjectively normal in size with normal smooth curvilinear peripheral contour. Parenchyma is appropriately hypoechoic to the spleen in echogenicity and appropriately mildly coarse and homogenous in echotexture. No focal lesions are observed. Visible vasculature and biliary tree appear normal without distension or congestion.

GB contains a moderate amount of non-dependent, mildly aggregated/inspissated sludge and measures 2.6 cm x 4.8 cm.. Hypo to anechoic cystic areas are noted between the gallbladder sludge and luminal wall. The wall is otherwise smooth without visible thickening. There is no evidence of cystic or CBD dilation. There is no evidence of effusion.

Gastrointestinal

The stomach wall is normal in thickness (canine < 0.5 cm and feline < 0.4 cm) and layering. The lumen of the stomach is empty with no evidence of obstruction, foreign material or infiltrative disease. Pyloric outflow tract appears patent.

The visible small intestines are normal in wall thickness and layering (canine duodenum < 0.5 cm and feline duodenum < 0.4 cm; other < 0.3 cm). Small intestinal motility appears adequate (1-3 contractions per min). The lumen of the small intestine is empty with no evidence of obstruction, foreign material or infiltrative disease.

The visible colon is normal in wall thickness (< 0.2 cm) and layering. Contents are consistent with normal formed feces and gas.

Pancreas

The pancreatic parenchyma is appropriately isoechoic to surrounding tissue. Visible capsule is smooth and normal in contour. There is no visible pancreatic duct dilation. There is no evidence of active peripancreatic inflammation.

Free Abdomen

There is no evidence of peritoneal effusion. There is no apparent lymphadenopathy.

PRIMARY FINDINGS

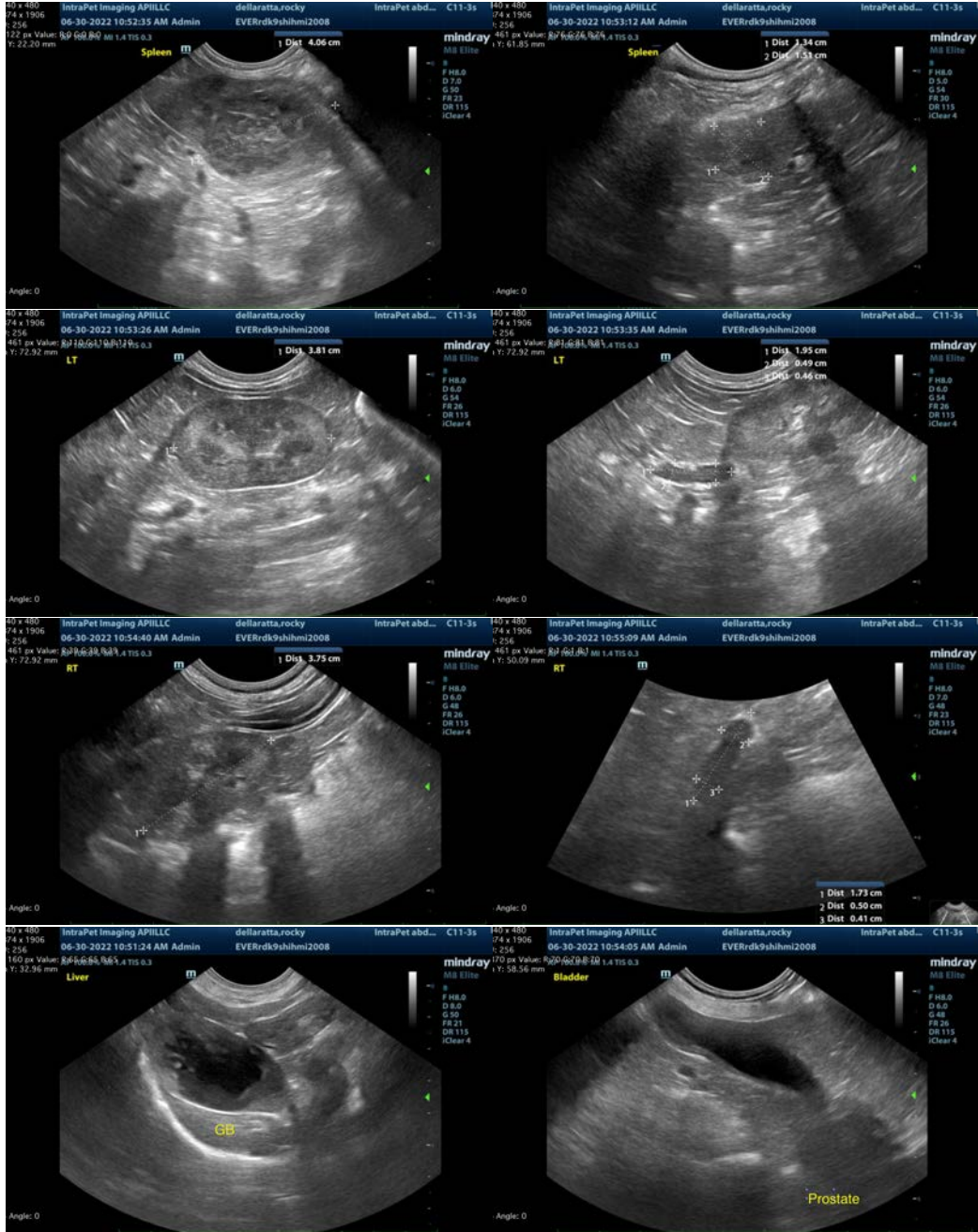
- Multiple splenic masses – concerning for infiltrative neoplasia such as hemangiosarcoma. Benign hematomas can mimic malignant lesions and cannot be ruled out.
- Early mucocele – Cholecystic debris is of unknown clinical significance. It can be seen with biliary stasis from fasting or illness. Cholecystic debris is not necessarily related to hepatobiliary disease. The non-dependent nature of this sludge combined with the cystic areas are suggestive, however, of possible emerging cystic mucosal hyperplasia or early gallbladder mucocele.

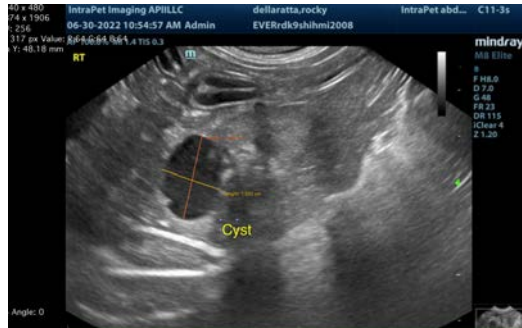SECONDARY FINDINGS

- Bilateral non-obstructive nephrolithiasis

INTERPRETATION OF THE FINDINGS & FURTHER RECOMMENDATIONS

- Three view thoracic radiographs are recommended for further assessment of cardio-pulmonary status as well as to further evaluate for any evidence of metastatic disease, if not recently evaluated.
- Surgical laparotomy for splenectomy is recommended, at which time gallbladder patency can also be evaluated in more detail with intervention recommended at that time, if indicated.





The information and recommendations provided are based on the images presented by the referring veterinarian/sonographer. No evaluation can be communicated regarding pathology that was not visible in the image/video clips provided.

Thank you for this referral. If the clinical or image interpretation does not parallel your findings or if I can be of any further assistance please contact me.

Beth Johnson, DVM, DACVIM
Beth.Johnson@sonopath.com