



## PATIENT

Moose Timm

## SPECIES

Canine

## BREED

Dachshund

## SEX

Intact Male

## AGE

1 Year

## WEIGHT

5.3 kg

## INTERPRETED BY

Beth Johnson, DVM  
DACVIM

## IMAGING PERFORMED BY

Dr. Sarah Barthelemy

## HOSPITAL NAME

Fish Creek Pet Hospital

## REFERRING VET

Dr. Whale

## INVOICE

75650

## DATE

6/3/26

## PRESENTING CLINICAL SIGNS

History since Thursday of hyporexia, lethargy, some vomiting. Poor response to outpatient treatment  
Currently hospitalized

Abnormal PE/Chem/CBC/UA Results: Neutrophilia and monocytosis

## ULTRASONOGRAPHIC EXAMINATION OF THE ABDOMEN

### *Urinary System*

The urinary bladder is adequately distended with anechoic contents. No masses, inflammatory changes, echogenic sediment or cystoliths are observed. The urinary bladder, trigone and visible pelvic urethra are normal in thickness with a smooth mucosal surface.

Prostate is normal in size (2.4 cm wide in the transverse view), echotexture and echogenicity for a neutered male.

The right kidney is normal in size (4.76 cm), shape and echogenicity. It has smooth peripheral margination. There is a normal 1:3 cortex to medulla ratio with appropriate corticomedullary distinction. There is no evidence of pyelectasia, mineral or infarcts observed.

The left kidney is normal in size (4.71 cm), shape and echogenicity. It has smooth peripheral margination. There is a normal 1:3 cortex to medulla ratio with appropriate corticomedullary distinction. There is no evidence of pyelectasia, mineral or infarcts observed.

### *Adrenal Glands*

The right adrenal gland is normal in size (0.32 cm at cranial pole and 0.37 cm at caudal pole), shape and overall architecture, echogenicity and echotexture. Visible surrounding vasculature appears normal.

The left adrenal gland is normal in size (0.37 cm at cranial pole and 0.42 cm at caudal pole), shape and overall architecture, echogenicity and echotexture. Visible surrounding vasculature appears normal.

### *Spleen*

The spleen is subjectively normal in size with a normal smooth capsular contour. Parenchyma is appropriately finely textured and homogenous with normal echogenicity relative to surrounding tissue (hyperechoic to liver). No focal nodules or masses are observed. Splenic vasculature appears normal.

### *Liver*

The liver is subjectively normal in size with normal smooth curvilinear peripheral contour. Parenchyma is appropriately hypoechoic to the spleen in echogenicity and appropriately mildly coarse and homogenous in echotexture. No focal lesions are observed. Visible vasculature and biliary tree appear normal without distension or congestion.

The gallbladder is non-distended in size. The wall is smooth without visible thickening. Luminal contents are primarily anechoic. There is no evidence of cystic or common bile duct dilation.

### *Gastrointestinal*

The visible stomach wall is normal in thickness and layering. The lumen of the stomach is mildly distended with a small to moderate amount of echogenic non-shadowing luminal contents and gas



## PATIENT

Moose Timm

## SPECIES

Canine

## BREED

Dachshund

## SEX

Intact Male

## AGE

1 Year

## WEIGHT

5.3 kg

## INTERPRETED BY

Beth Johnson, DVM  
DACVIM

## IMAGING PERFORMED BY

Dr. Sarah Barthelemy

## HOSPITAL NAME

Fish Creek Pet Hospital

## REFERRING VET

Dr. Whale

## INVOICE

75650

## DATE

6/3/26

consistent with normal ingesta. There is no evidence of obstruction, foreign material or infiltrative disease. Pyloric outflow tract appears patent.

The visible small intestines are normal in wall thickness and layering. Small intestinal motility appears adequate (1-3 contractions per min). The lumen is largely empty, except for in the mid jejunum where there is an intraluminal echogenic density with acoustic shadow, concerning for a foreign object. The bowel is mildly fluid distended leading up to the suspected foreign body, indicating at least partial or early obstruction.

The visible colon is normal in wall thickness (< 0.2 cm) and layering. The lumen is diffusely mildly distended with soft stool.

### ***Pancreas***

The pancreas that is observed appears appropriately isoechoic to surrounding omental fat. Visible capsule is smooth and normal in contour. Visible pancreatic parenchyma is homogenous and unremarkable. There is no visible pancreatic duct dilation. There is no evidence of active peripancreatic inflammation.

### ***Free Abdomen***

Mesenteric lymph nodes are prominent in size with swollen capsular contour. Normal elongated shape (length to width ratio) is maintained. There is no loss of parenchymal detail.

Free fluid and enhanced hyperechoic fat and mesentery are noted adjacent to the suspected foreign body.

## **ULTRASONOGRAPHIC FINDINGS**

- At least partial versus early small bowel obstruction from a foreign object is suspected, with focal changes i.e., free fluid, enhanced fat, etc. consistent with focal inflammation/peritonitis.
- Suspect emerging diarrhea.
- Moderately reactive mesenteric lymph nodes – This finding may be in part normal patient variant/juvenile lymphadenopathy, given the young age. Infiltrative neoplastic disease cannot be ruled out but is considered less likely.

## **INTERPRETATION OF THE FINDINGS & FURTHER RECOMMENDATIONS**

As was reportedly planned, as soon as patient is stable enough for surgery an exploratory laparotomy is recommended for further investigation and removal of the suspected foreign body.



**PATIENT**

Moose Timm

**SPECIES**

Canine

**BREED**

Dachshund

**SEX**

Intact Male

**AGE**

1 Year

**WEIGHT**

5.3 kg

**INTERPRETED BY**

Beth Johnson, DVM  
DACVIM

**IMAGING PERFORMED BY**

Dr. Sarah Barthelemy

**HOSPITAL NAME**

Fish Creek Pet Hospital

**REFERRING VET**

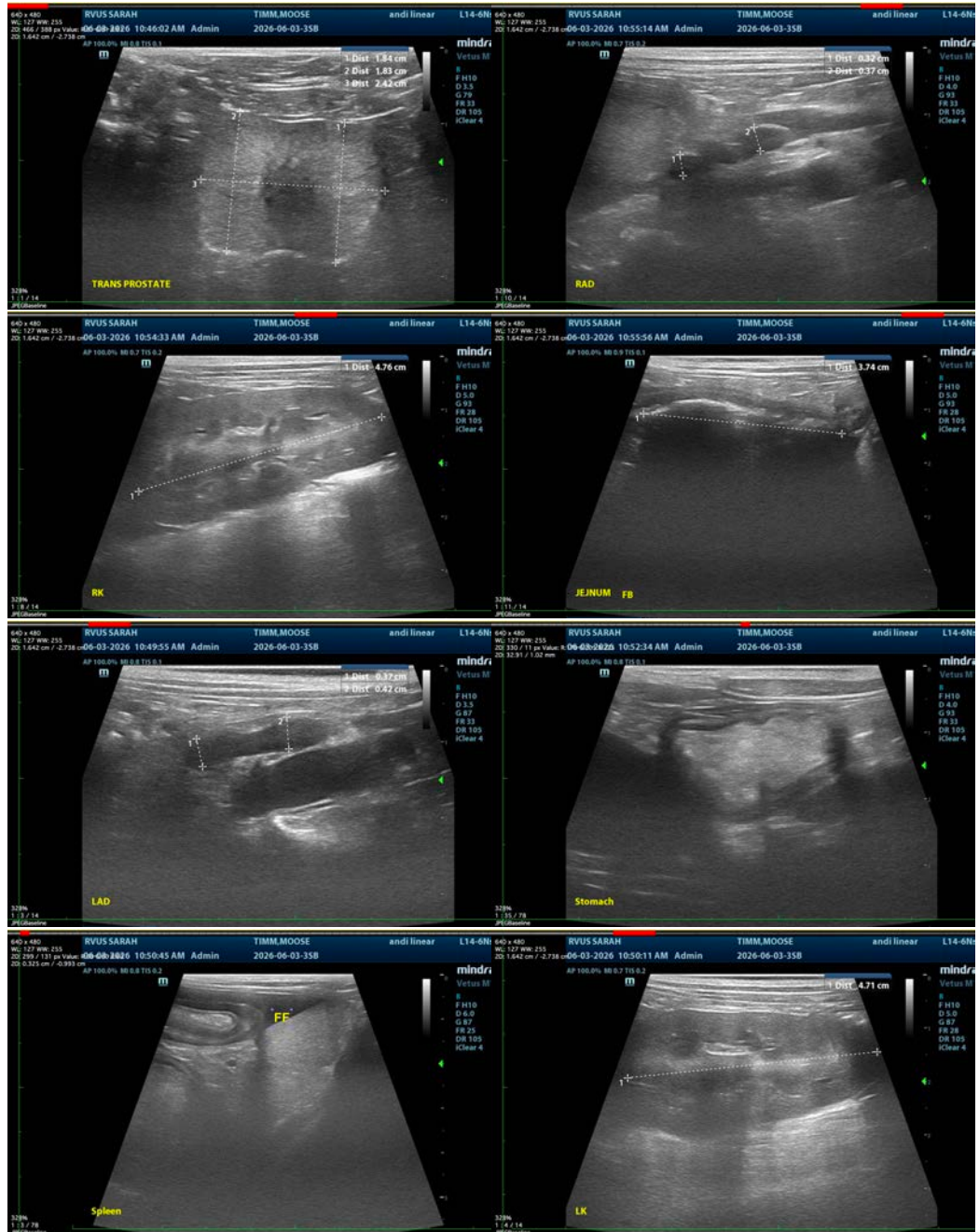
Dr. Whale

**INVOICE**

75650

**DATE**

6/3/26





## PATIENT

Moose Timm

## SPECIES

Canine

## BREED

Dachshund

## SEX

Intact Male

## AGE

1 Year

## WEIGHT

5.3 kg

## INTERPRETED BY

Beth Johnson, DVM  
DACVIM

## IMAGING PERFORMED BY

Dr. Sarah Barthelemy

## HOSPITAL NAME

Fish Creek Pet Hospital

## REFERRING VET

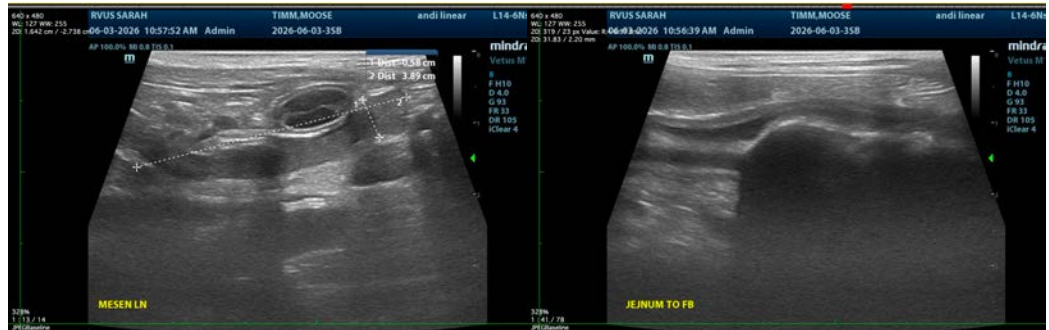
Dr. Whale

## INVOICE

75650

## DATE

6/3/26



The information and recommendations provided are based on the images presented by the referring veterinarian/sonographer. No evaluation can be communicated regarding pathology that was not visible in the image/video clips provided.

Thank you for this referral. If the clinical or image interpretation does not parallel your findings or if I can be of any further assistance please contact me.

**Beth Johnson, DVM, DACVIM**  
info@sonopath.com