



PATIENT

Milo Park

SPECIES

Canine

BREED

Mixed

SEX

NM

AGE

7 years

WEIGHT

107 lbs

INTERPRETED BY

Beth Johnson, DVM
DACVIM

IMAGING PERFORMED BY

Dr. Suci

HOSPITAL NAME

Animal Clinic of
Queens

REFERRING VET

Dr. Mucera

INVOICE

12078

DATE

6/3/2026

PRESENTING CLINICAL SIGNS

Increased liver values since March 2026 (incidental finding at wellness bloodwork). Patient is asymptomatic, no V/D, no PU/PD, good energy level, normal appetite.

Abnormal PE/Chem/CBC/UA Results: BW 3/13/26: high ALT (409). High globulin 3.8 (1.6-3.6). High Ca (11.7), corrected Ca is high (11.9). BW 5/30/26: high ALT (537), high AST 82 (15-66)(may be falsely elevated due to hemolysis 4+ per Antech). High globulin 4.0 (1.6-3.6)

****Interpretation of this study is severely limited by a large amount of motion artifact and gas.****

ULTRASONOGRAPHIC EXAMINATION OF THE ABDOMEN

Urinary System

Urinary bladder is only mildly distended (empty). Visible contents are anechoic. Urinary bladder wall is unable to be fully assessed for pathology without further distension. No visible masses or definitive cystoliths are observed. The trigone and visible pelvic urethra are normal thickness with a smooth mucosal surface. In the face of urinary signs and/or suspected urinary bladder pathology, reassessment after complete filling is recommended.

The area of the prostate is examined without evident prostatic pathology.

The right kidney is normal is size (7.9 cm), shape and echogenicity. It has smooth peripheral margination. There is a normal 1:3 cortex to medulla ratio with appropriate corticomedullary distinction. There is no evidence of pyelectasia, mineral or infarcts observed.

The left kidney is normal is size (7.8 cm), shape and echogenicity. It has smooth peripheral margination. There is a normal 1:3 cortex to medulla ratio with appropriate corticomedullary distinction. There is no evidence of pyelectasia, mineral or infarcts observed.

Adrenal Glands

The right adrenal gland is normal in size (0.53 cm at cranial pole and 0.53 cm at caudal pole), shape and overall architecture, echogenicity and echotexture. Visible surrounding vasculature appears normal.

The left adrenal gland is normal in size (0.62 cm at cranial pole and 0.72 cm at caudal pole), shape and overall architecture, echogenicity and echotexture. Visible surrounding vasculature appears normal.

Spleen

The spleen is subjectively normal in size with a normal smooth capsular contour. Parenchyma is appropriately finely textured and homogenous with normal echogenicity relative to surrounding tissue (hyperechoic to liver). No focal nodules or masses are observed. Splenic vasculature appears normal.

Liver

The liver is subjectively normal in size with normal smooth curvilinear peripheral contour. Parenchyma is appropriately hypoechoic to the spleen in echogenicity and appropriately mildly coarse and homogenous in echotexture. No focal lesions are observed. Visible vasculature and biliary tree appear normal without distension or congestion.



PATIENT

The gallbladder is non-distended in size. The wall is smooth without visible thickening. Luminal contents are primarily anechoic. There is no evidence of cystic or common bile duct dilation.

Milo Park

Gastrointestinal

SPECIES

The visible stomach wall is normal in thickness and layering. The lumen of the stomach is mildly distended with very echogenic reverberation artifact from intraluminal gas. There is no evidence of obstruction, foreign material, or infiltrative disease; however, visualization is partially inhibited by gas. Pyloric outflow tract appears patent.

Canine

BREED

Mixed

SEX

NM

The visible colon is normal in wall thickness (< 0.2 cm) and layering. Contents are consistent with normal formed feces and gas.

AGE

7 years

Pancreas

The pancreas that is observed appears appropriately isoechoic to surrounding omental fat. Visible capsule is smooth and normal in contour. Visible pancreatic parenchyma is homogenous and unremarkable. There is no visible pancreatic duct dilation. There is no evidence of active peripancreatic inflammation.

WEIGHT

107 lbs

INTERPRETED BY

Free Abdomen

Beth Johnson, DVM
DACVIM

There is no visible free peritoneal effusion noted in these images.

There is no apparent pathologic lymphadenopathy noted in these images.

IMAGING PERFORMED BY

ULTRASONOGRAPHIC FINDINGS

Dr. Suci

- An obvious cause for the reported increased liver enzymes is not identified in these images. Microscopic disease such as Leptospirosis, bacterial cholangiohepatitis, chronic active hepatitis, copper-associated hepatotoxicity, other hepatotoxicity, other reactive hepatopathy, infiltrative neoplasia, etc. cannot be definitively ruled out.

HOSPITAL NAME

Animal Clinic of
Queens

INTERPRETATION OF THE FINDINGS & FURTHER RECOMMENDATIONS

REFERRING VET

Dr. Mucera

Given patient's reported hyperglobulinemia, combined with the historical hypercalcemia, a malignancy panel (PTH, PTHrP, iCa) to Michigan State College of Veterinary Medicine is recommended for further investigation of the reported hypercalcemia.

Serum electrophoresis for further evaluation of the globulins could be considered.

INVOICE

12078

Differentials for a primary hepatocellular injury liver enzyme pattern (increased ALT) depend partially on the level of increase. Mild increases (less than 2 times normal) are often a "reactive hepatopathy" or the liver's response to an insult elsewhere in the body including, but not limited to, pancreatitis, gastroenteritis, parasitic disease, dental disease, vacuolar or endocrine hepatopathy from diabetes mellitus or hyperadrenocorticism (steroid-induced), hypoadrenocorticism, certain drugs (e.g. phenobarbital, corticosteroids, azathioprine, etc.), and muscle ALT (more likely if AST and CK concurrently increased).

DATE

6/3/2026



PATIENT

Milo Park

SPECIES

Canine

BREED

Mixed

SEX

NM

AGE

7 years

WEIGHT

107 lbs

INTERPRETED BY

Beth Johnson, DVM
DACVIM

IMAGING PERFORMED BY

Dr. Suci

HOSPITAL NAME

Animal Clinic of
Queens

REFERRING VET

Dr. Mucera

INVOICE

12078

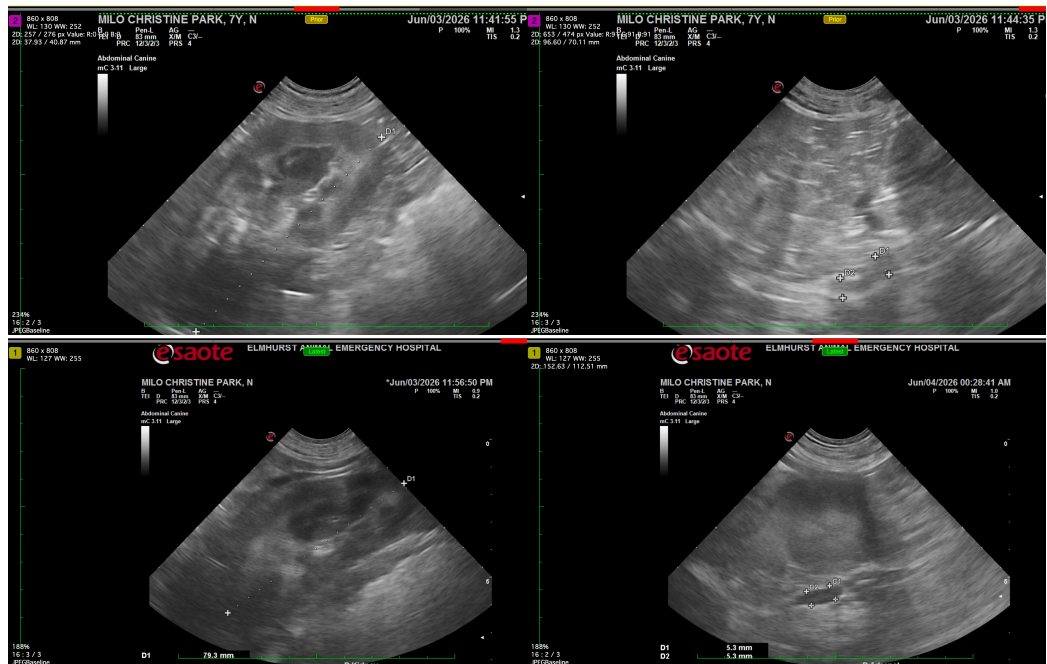
DATE

6/3/2026

It is a good indicator of active liver damage (cell membrane disruption, cellular necrosis), however, if the value is increased by at least 3-4 times normal. Differentials include infectious disease, including Leptospirosis, inflammatory disease (ie. active hepatitis, copper, other), toxic insult as well as infiltrative neoplasia.

ALT levels vary in cases of vascular anomalies such as microvascular dysplasia and portosystemic shunts (PSS), but are often less significantly increased.

- Testing for Leptospirosis could be considered.
- Bile acids could be considered, if tbili is not increased.
- An empirical course of antibiotics and empirical hepatic nutraceuticals may be tried, with monitoring of ALT for improvement. If improvement is noted, antibiotics should be continued until liver enzymes either normalize or plateau (recheck every 2-3 weeks); however, if improvement is not noted and/or enzyme increase progresses, antibiotics should not be continued long term and liver tissue sampling is recommended.
- FNA of the liver can be performed to assess inflammatory cell type, rule in/out round cell neoplasia, etc. (if patient's coagulation status is appropriate).
- If round cell neoplasia is not diagnosed, a liver biopsy (including copper level assessment) may be required to definitively diagnose the underlying hepatopathy.





PATIENT

Milo Park

SPECIES

Canine

BREED

Mixed

SEX

NM

AGE

7 years

WEIGHT

107 lbs

INTERPRETED BY

Beth Johnson, DVM
DACVIM

IMAGING PERFORMED BY

Dr. Suci

HOSPITAL NAME

Animal Clinic of
Queens

REFERRING VET

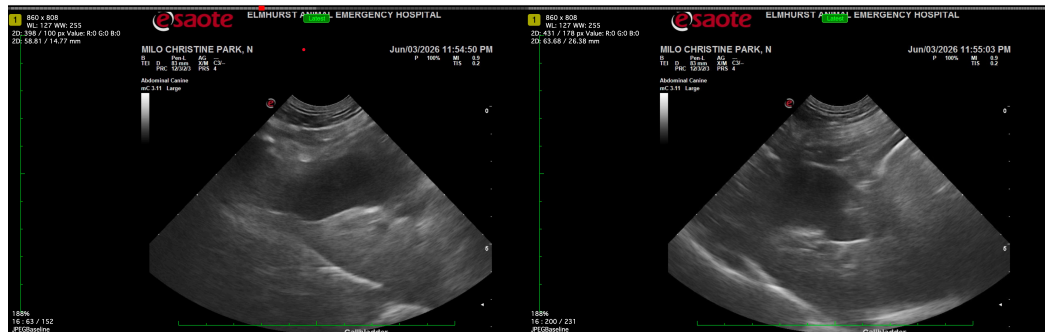
Dr. Mucera

INVOICE

12078

DATE

6/3/2026



The information and recommendations provided are based on the images presented by the referring veterinarian/sonographer. No evaluation can be communicated regarding pathology that was not visible in the image/video clips provided.

Thank you for this referral. If the clinical or image interpretation does not parallel your findings or if I can be of any further assistance please contact me.

Beth Johnson, DVM, DACVIM
info@sonopath.com