



PATIENT

Maca Johnson

SPECIES

Canine

BREED

Doberman x

SEX

Neutered Male

AGE

11 Years

WEIGHT

33.3 kg

INTERPRETED BY

Beth Johnson, DVM
DACVIM

IMAGING PERFORMED BY

Dr. Sarah Barthelemy

HOSPITAL NAME

Petzoic Vet

REFERRING VET

Dr. Hamed

INVOICE

75655

DATE

6/3/26

PRESENTING CLINICAL SIGNS

Presented May 30 for vomiting and diarrhea. Spec CPL in house elevated at that time . Outpatient supportive treatment given but continued to have some vomiting through maropitant. Presented June 2 and is hospitalized on IVF, ondansetron, maropitant. Liver enzymes are going down

Abnormal PE/Chem/CBC/UA Results: Mild ALP and ALT elevations

ULTRASONOGRAPHIC EXAMINATION OF THE ABDOMEN

Urinary System

Urinary bladder is adequately distended. It has a normal uniform wall thickness. Contents include primarily anechoic fluid with a mild amount of echogenic non-shadowing debris, most consistent with exfoliated cells, mucous and/or small blood clots. Both sterile inflammation as well as urinary tract infection can present with echogenic debris. No masses or cystoliths are observed. The trigone and visible pelvic urethra are normal in thickness with a smooth mucosal surface.

Prostate is normal in size, echotexture and echogenicity for a neutered male.

The right kidney is normal is size (7.02 cm), shape and echogenicity. It has smooth peripheral margination. There is a normal 1:3 cortex to medulla ratio with appropriate corticomedullary distinction. There is no evidence of pyelectasia, mineral or infarcts observed. A subtle hyperechoic band parallel to the corticomedullary border is present.

The left kidney is normal is size (6.71 cm), shape and echogenicity. It has smooth peripheral margination. There is a normal 1:3 cortex to medulla ratio with appropriate corticomedullary distinction. There is no evidence of pyelectasia, mineral or infarcts observed. A subtle hyperechoic band parallel to the corticomedullary border is present.

Adrenal Glands

The right adrenal gland is normal in size (0.66 cm at cranial pole and 0.53 cm at caudal pole), shape and overall architecture, echogenicity and echotexture. Visible surrounding vasculature appears normal.

The left adrenal gland is normal in size (0.59 cm at cranial pole and 0.62 cm at caudal pole), shape and overall architecture, echogenicity and echotexture. Visible surrounding vasculature appears normal.

Spleen

Spleen is subjectively large in size with a mildly swollen but smooth capsule. Parenchyma is normal and homogenous in echogenicity and echotexture. No focal nodules or masses are observed. Splenic vasculature appears normal.

Liver

Liver is subjectively enlarged with mildly irregular margins. Parenchyma is mildly heterogenous characterized by multiple poorly defined hypoechoic nodules within otherwise hyperechoic liver parenchyma. Visible vasculature and biliary tree appear normal without distension or congestion.

Gallbladder is moderately distended with anechoic bile as well as suspended and gravity dependent echogenic debris. The wall is smooth without visible thickening. There is no evidence of cystic or CBD dilation. There is no evidence of effusion or inflammation.



PATIENT

Maca Johnson

SPECIES

Canine

BREED

Doberman x

SEX

Neutered Male

AGE

11 Years

WEIGHT

33.3 kg

INTERPRETED BY

Beth Johnson, DVM
DACVIM

IMAGING PERFORMED BY

Dr. Sarah Barthelemy

HOSPITAL NAME

Petzoic Vet

REFERRING VET

Dr. Hamed

INVOICE

75655

DATE

6/3/26

Gastrointestinal

The visible stomach wall is normal in thickness and layering. The lumen of the stomach is empty with no evidence of obstruction, foreign material or infiltrative disease. Pyloric outflow tract appears patent.

The visible small intestines are normal in wall thickness and layering. Small intestinal motility appears adequate (1-3 contractions per min). The lumen of the small intestine is empty with no evidence of obstruction, foreign material or infiltrative disease.

The visible colon is normal in wall thickness (< 0.2 cm) and layering, except for subtle very mild thickening in the distal descending colon where it measures 0.29 cm thick. Normal intact layering is maintained. The lumen is mildly distended with soft stool.

Pancreas

The pancreas that is observed appears appropriately isoechoic to surrounding omental fat. Visible capsule is smooth and normal in contour. Visible pancreatic parenchyma is homogenous and unremarkable. There is no visible pancreatic duct dilation. There is no evidence of active peripancreatic inflammation.

Free Abdomen

There is no visible free peritoneal effusion noted in these images.

There is no apparent pathologic lymphadenopathy noted in these images.

ULTRASONOGRAPHIC FINDINGS

- Mildly thick distal descending colon trends in appearance toward benign as is seen with parasitic, infectious, dietary related or other benign inflammatory colitis, with infiltrative neoplasia being considered less likely but unable to be definitively ruled out without tissue sampling.
- Mildly heterogenous liver – These changes are most consistent with benign processes such as nodular hyperplasia, steroid (vacuolar) hepatopathy, extramedullary hematopoiesis or possibly chronic inflammatory disease and less commonly infiltrative round cell or metastatic neoplasia.
- Mild gallbladder debris - Cholecystic debris is of unknown clinical significance. It can be seen with biliary stasis from fasting or illness. Cholecystic debris is not necessarily related to hepatobiliary disease. Echogenic bile is most commonly an incidental finding in dogs and should be interpreted in combination with clinical signs such as nausea, inappetence, cranial abdominal discomfort and/or laboratory changes such as increased ALP and/or increased Tbili.
- Splenomegaly– can be associated with congestion caused by sedation (if sedated) but can also be associated with diffuse infiltrative disease. Both benign conditions such as extramedullary hematopoiesis, lymphoid hyperplasia, as well as infiltrative neoplastic diseases such as round cell neoplasia should be considered.
- Subtle bilateral medullary rim sign - This finding is of unknown clinical significance and can be a normal variant, often idiopathic. Medullary rim sign can be present with renal disease including lymphoma, hypercalcemic nephropathy, Leptospirosis, tubular disease, other and should be interpreted in combination with other more specific indications of kidney disease such as



PATIENT

Maca Johnson

SPECIES

Canine

BREED

Doberman x

SEX

Neutered Male

AGE

11 Years

WEIGHT

33.3 kg

INTERPRETED BY

Beth Johnson, DVM
DACVIM

IMAGING PERFORMED BY

Dr. Sarah Barthelemy

HOSPITAL NAME

Petzoic Vet

REFERRING VET

Dr. Hamed

INVOICE

75655

DATE

6/3/26

isosthenuria, proteinuria, azotemia, etc. This is a common incidental finding in patients with diabetes mellitus.

- Mild amount of echogenic urinary bladder debris.

INTERPRETATION OF THE FINDINGS & FURTHER RECOMMENDATIONS

A routine fecal/giardia exam is recommended if not recently evaluated.

A gastrointestinal malabsorption panel (including cobalamin, folate, TLI and PLI) to Texas A&M GI Laboratory is recommended for further evaluation of GI and pancreatic function.

A fecal enteropathogen PCR panel to Texas A&M GI Laboratory could be considered for further evaluation of possible infectious disease. Contact lab for recommendations on how long to discontinue antibiotics (if indicated) prior to obtaining a stool sample for submission.

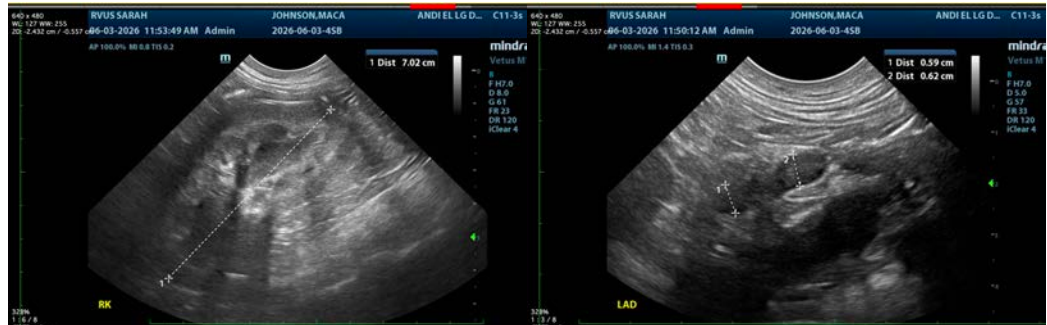
A baseline cortisol is recommended. If baseline cortisol is less than 2, a full ACTH stimulation test is recommended to rule out hypoadrenocorticism.

Additionally, fine needle aspirates of the spleen +/- liver could be considered if patient's coagulation status is appropriate.

In the meantime:

- Supportive/symptomatic medical management of clinical signs is recommended, including anti-emetics, gastroprotectants (+/- sucralfate, especially with any history of hematemesis), an appetite stimulant and fluid therapy if indicated, etc.
- Additionally, empirical deworming with a 5-day course of Panacur is recommended.
- A full course of empirical Helicobacter triple therapy could be considered.
- A probiotic, such a visbiome or proviable, may be helpful.
- Finally, if tolerated, a transition in diet could be considered, based on trial-and-error response with some options to consider including a gastrointestinal biome diet vs a hydrolyzed protein diet (sometimes several trials with different brands are necessary) vs an easy to digest, bland or low-fat diet vs other.

Ultimately, if a diagnosis is not obtained, and clinical signs persist, colonoscopy for further visual evaluation and biopsies of the colon may be warranted.





PATIENT

Maca Johnson

SPECIES

Canine

BREED

Doberman x

SEX

Neutered Male

AGE

11 Years

WEIGHT

33.3 kg

INTERPRETED BY

Beth Johnson, DVM
DACVIM

IMAGING PERFORMED BY

Dr. Sarah Barthelmy

HOSPITAL NAME

Petzoic Vet

REFERRING VET

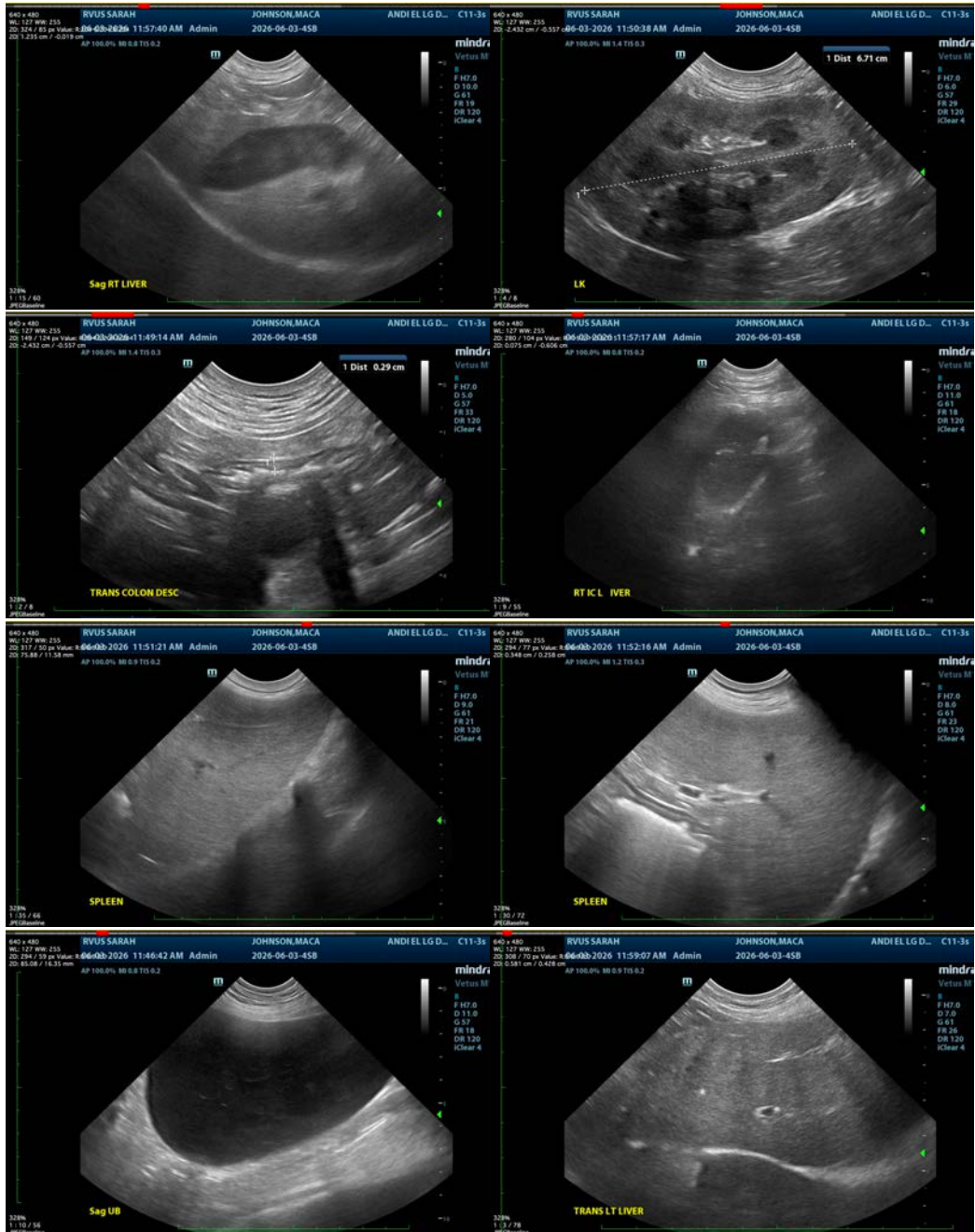
Dr. Hamed

INVOICE

75655

DATE

6/3/26





PATIENT

Maca Johnson

SPECIES

Canine

BREED

Doberman x

SEX

Neutered Male

AGE

11 Years

WEIGHT

33.3 kg

INTERPRETED BY

Beth Johnson, DVM
DACVIM

IMAGING PERFORMED BY

Dr. Sarah Barthelemy

HOSPITAL NAME

Petzoic Vet

REFERRING VET

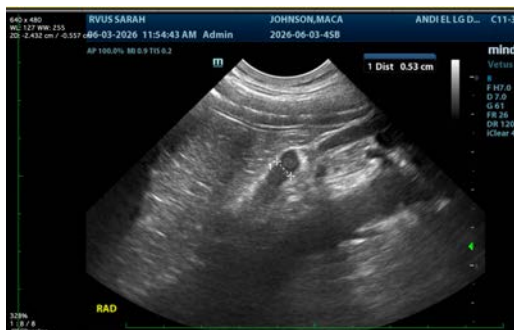Dr. Hamed

INVOICE

75655

DATE

6/3/26



The information and recommendations provided are based on the images presented by the referring veterinarian/sonographer. No evaluation can be communicated regarding pathology that was not visible in the image/video clips provided.

Thank you for this referral. If the clinical or image interpretation does not parallel your findings or if I can be of any further assistance please contact me.

Beth Johnson, DVM, DACVIM
info@sonopath.com