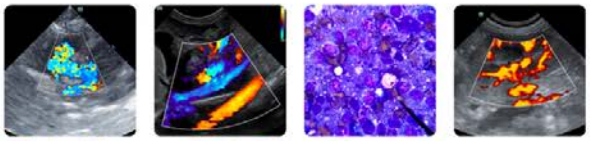



**PATIENT**
Isaac Mucci

**SPECIES**
Canine

**BREED**
Weimaraner

**SEX**
Male

**AGE**
7

**WEIGHT**
74

**INTERPRETED BY**
Beth Johnson, DVM DACVIM

**IMAGING PERFORMED BY**
Jenn

**HOSPITAL NAME**
Rockaway Animal Hospital

**REFERRING VET**
Dr. Kahn

**INVOICE**
75628

**DATE**
6/3/26

## PRESENTING CLINICAL SIGNS

Intact male with symptoms of BPH urinary incontinence , intermittent blood dribbled in urine recently treated for UTI/prostatitis at a different vet They saw enlarged prostate with cystic lesions on u/s

Abnormal PE/Chem/CBC/UA Results: ALT 182 all else WNL U/A ph 6.5 RBC's seen trace proyein sperm present USG 1.022

## ULTRASONOGRAPHIC EXAMINATION OF THE ABDOMEN

### *Urinary System*

Urinary bladder is adequately distended with primarily anechoic contents and occasional echogenic non-shadowing debris. Apical urinary bladder wall is diffusely thick (0.43 cm). Mucosa is hyperechoic and irregular. No masses or cystoliths are observed. The trigone and visible pelvic urethra are normal thickness with a smooth mucosal surface.

Prostate is symmetrically enlarged (4.3 cm wide in the transverse view) with smooth margins that are well differentiated from surrounding tissue. Normal bilobed shape is maintained. Parenchyma is diffusely hyperechoic. Several small anechoic cysts are noted. The largest cystic density measures 1.3 cm x 2.3 cm. No mineral is noted.

The right kidney is normal is size (6.65 cm), shape and echogenicity. It has smooth peripheral margination. There is a normal 1:3 cortex to medulla ratio with appropriate corticomedullary distinction. There is no evidence of pyelectasia, mineral or infarcts observed. A subtle hyperechoic band parallel to the corticomedullary border is present.

The left kidney is normal is size (7.05 cm), shape and echogenicity. It has smooth peripheral margination. There is a normal 1:3 cortex to medulla ratio with appropriate corticomedullary distinction. There is no evidence of pyelectasia, mineral or infarcts observed. A subtle hyperechoic band parallel to the corticomedullary border is present.

### *Adrenal Glands*

The right adrenal gland is unable to be well visualized in these images. *The patient reportedly could have benefited from increased sedation, which may be necessary for further visual evaluation of the right adrenal gland.

The left adrenal gland is normal in size (0.86 cm at cranial pole and 0.66 cm at caudal pole), shape and overall architecture, echogenicity and echotexture. Visible surrounding vasculature appears normal.

### *Spleen*

The spleen is subjectively normal in size with a normal smooth capsular contour. Parenchyma is appropriately finely textured and homogenous with normal echogenicity relative to surrounding tissue (hyperechoic to liver). No focal nodules or masses are observed. Splenic vasculature appears normal.

### *Liver*

The liver is subjectively normal in size with normal smooth curvilinear peripheral contour. Parenchyma is appropriately hypoechoic to the spleen in echogenicity and appropriately mildly coarse and homogenous in echotexture. No focal lesions are observed. Visible vasculature and biliary tree appear normal without distension or congestion.

**PATIENT**
Isaac Mucci

**SPECIES**
Canine

**BREED**
Weimaraner

**SEX**
Male

**AGE**
7

**WEIGHT**
74

**INTERPRETED BY**
Beth Johnson, DVM DACVIM

**IMAGING PERFORMED BY**
Jenn

**HOSPITAL NAME**
Rockaway Animal Hospital

**REFERRING VET**
Dr. Kahn

**INVOICE**
75628

**DATE**
6/3/26

The gallbladder is non-distended in size. The wall is smooth without visible thickening. Luminal contents are primarily anechoic. There is no evidence of cystic or common bile duct dilation.

### *Gastrointestinal*

The visible stomach wall is normal in thickness and layering. The stomach is moderately distended with echogenic non-shadowing luminal contents and gas consistent with normal ingesta. There is no evidence of obstruction, foreign material or infiltrative disease. If patient was appropriately fasted, delayed gastric emptying could be considered. Non-shadowing foreign material is considered less likely but cannot be definitively ruled out.

If clinical signs are consistent (vomiting, etc.), recommendations include supportive medical care, 24 hours fasting and re-image.

The visible small intestines are normal in wall thickness and layering. Small intestinal motility appears adequate (1-3 contractions per min). The lumen of the small intestine is empty with no evidence of obstruction, foreign material or infiltrative disease.

The visible colon is normal in wall thickness (< 0.2 cm) and layering. Contents are consistent with normal formed feces and gas.

### *Pancreas*

The pancreas that is observed appears appropriately isoechoic to surrounding omental fat. Visible capsule is smooth and normal in contour. Visible pancreatic parenchyma is homogenous and unremarkable. There is no visible pancreatic duct dilation. There is no evidence of active peripancreatic inflammation.

### *Free Abdomen*

There is no visible free peritoneal effusion noted in these images.

There is no apparent pathologic lymphadenopathy noted in these images.

## ULTRASONOGRAPHIC FINDINGS

- Benign Prostatic Hyperplasia with cysts – Prostatic findings are most consistent with Benign Prostatic Hyperplasia (BPH) and concurrent benign prostatic cysts. Active prostatitis cannot be ruled out. Infiltrative neoplasia cannot be ruled out but is considered less likely.

- Chronic Cystitis - Urinary bladder wall changes are most consistent with chronic cystitis. Infiltrative neoplasia cannot be ruled out but is considered less likely give the location and diffuse nature of the changes.

- Subtle bilateral medullary rim sign - This finding is of unknown clinical significance and can be a normal variant, often idiopathic. Medullary rim sign can be present with renal disease including lymphoma, hypercalcemic nephropathy, Leptospirosis, tubular disease, other and should be interpreted in combination with other more specific indications of kidney disease such as isosthenuria, proteinuria, azotemia, etc. This is a common incidental finding in patients with diabetes mellitus.

**PATIENT**

Isaac Mucci

**SPECIES**

Canine

**BREED**

Weimaraner

**SEX**

Male

**AGE**

7

**WEIGHT**

74

**INTERPRETED BY**

Beth Johnson, DVM DACVIM

**IMAGING PERFORMED BY**

Jenn

**HOSPITAL NAME**

Rockaway Animal Hospital

**REFERRING VET**

Dr. Kahn

**INVOICE**

75628

**DATE**

6/3/26

## INTERPRETATION OF THE FINDINGS & FURTHER RECOMMENDATIONS

If clinical signs persist bey9ond ruling out and/or treating urinary tract infection/bacterial prostatitis, etc., submission of urine to look BRAF gene mutation could be considered to more definitively rule out infiltrative neoplasia, which is not suspected but can't be ruled out visually. Additionally and/or alternatively, sampling of the prostate via fine needle aspirate could be considered if patient's coagulation status is appropriate. Ultimately, however, these clinical signs can be present with benign prostatic hyperplasia, and patient neutering may be necessary to prevent progression and future episodes of clinical signs.

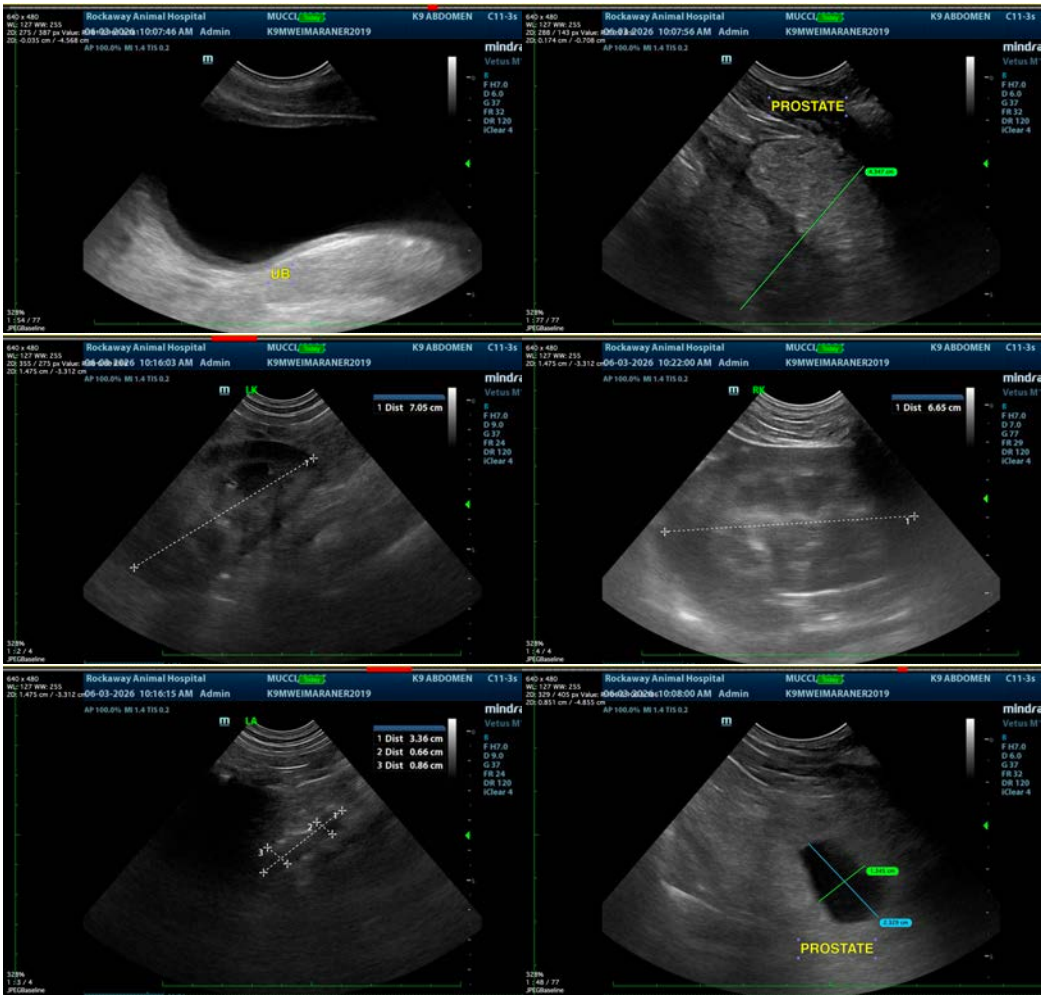


**The information and recommendations provided are based on the images presented by the referring veterinarian/sonographer. No evaluation can be communicated regarding pathology that was not visible in the image/video clips provided.**

Thank you for this referral. If the clinical or image interpretation does not parallel your findings or if I can be of any further assistance please contact me.

**Beth Johnson**, DVM, DACVIM
info@sonopath.com